Neurol Med Chir (Tokyo) 47, 128～131, 2007

Optochiasmatic Cavernous Angioma: Unexpected Diagnosis

—Case Report—

Ercan ÖZER, Orhan KALEMCI, Kemal YÜCESOY, and Serafettin CANDA*

*Departments of Neurosurgery and *Pathology, Dokuz Eylül University Medical Faculty, Inciralti, Izmir, Turkey*

Abstract

A 15-year-old boy presented with an extremely rare optochiasmatic cavernous angioma. He was admitted to a special hospital with the complaint of blurred vision persisting for 1 month. Magnetic resonance imaging and biopsy of the lesion were inconclusive. He was admitted to our neurosurgical clinic after worsening of the visual symptoms 9 months later. Repeat magnetic resonance imaging showed optochiasmatic cavernous angioma which had doubled in size. The lesion was removed completely without any problem. Postoperatively his visual complaints remained stable, but had improved after 1 year. Optochiasmatic cavernous malformation should be treated by surgical excision, whereas biopsy is useless and may result in enlargement.

Key words: cavernous angioma, optic nerve, optic chiasm, surgical treatment, vision disorders

Introduction

All lesions in the suprasellar region can interfere with optic nerve functions. The most common lesions are pituitary adenoma, craniopharyngioma, meningioma, carotid aneurysm, and optic and hypothalamic gliomas. In addition, many uncommon neoplastic and infiltrative diseases affect this area, including germinoma, lymphoma, leukemia, chordoma, metastasis, nasopharyngeal carcinoma, sarcoidosis, and histiocytosis X.[18] Optochiasmatic cavernous angioma is a very rare cause of visual symptoms and findings caused by optic nerve dysfunction.[1,6,8,9,16,20,23] Only a few neurosurgeons worldwide have experience with this type of suprasellar mass. Therefore, the diagnosis and treatment of cavernous angioma arising from the optic nerve-chiasm complex presents some problems.

Here we describe a case of optochiasmatic cavernous angioma, with the clinical and radiological characteristics.

Case Report

A 15-year-old boy experienced blurred vision for 1 month. He was admitted to a special hospital. Magnetic resonance (MR) imaging showed a suprasellar mass (Fig. 1A–E). Exploration and biopsy of the lesion were performed. Histological examination of the specimen found vascular structure, so the biopsy was inconclusive. Nine months later, his complaints worsened. MR imaging showed the persisting lesion (Fig. 2A, B). He was then admitted to our outpatient clinic.

Neurological examination and visual field study demonstrated total visual loss without light perception in the left eye, and temporal hemianopia in the right eye. Funduscopic examination revealed bilateral optic atrophy. MR imaging was repeated. Re-evaluation of the initial MR images before the exploration surgery (Fig. 1A–E) demonstrated a suprasellar mass consistent with optochiasmatic cavernous angioma apparently consisting of blood of different ages. The mass had caused enlargement of chiasm and left optic nerve. There was no hemosiderin ring around the lesion but the progressive enlargement indicated cavernous angioma. MR angiography showed flushing of the lesion (Fig. 1F). Re-evaluation of the MR images after biopsy and after worsening showed the mass had doubled in size since the operation (Fig. 2A, B).

Surgery was planned for removal of the lesion via left pterional craniotomy. Exposure of the sellar

Received October 21, 2005; Accepted November 27, 2006

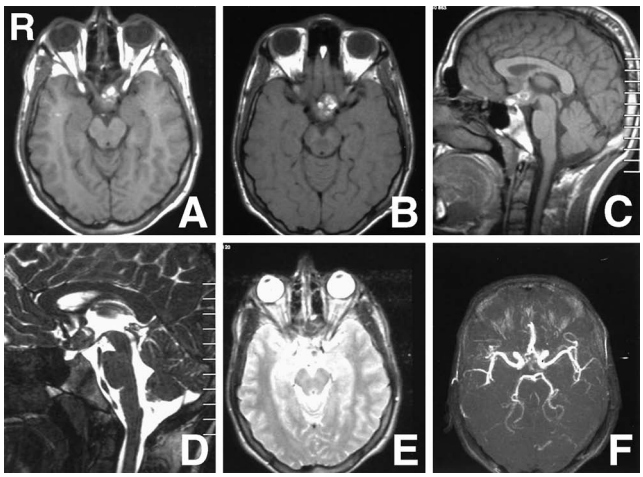

Fig. 1 Axial T_1-weighted magnetic resonance (MR) images (A) and with contrast medium (B), sagittal T_1-weighted (C) and T_2-weighted (D) MR images, and proton density (E) MR image at the initial diagnosis showing the optochiasmatic cavernous angioma as a mass in the sellar region containing blood of different ages but no hemosiderin ring around the lesion, which is typical for cavernous angioma. The lesion clearly originates from the visual apparatus (A). MR angiogram (F) showing flushing of the lesion.

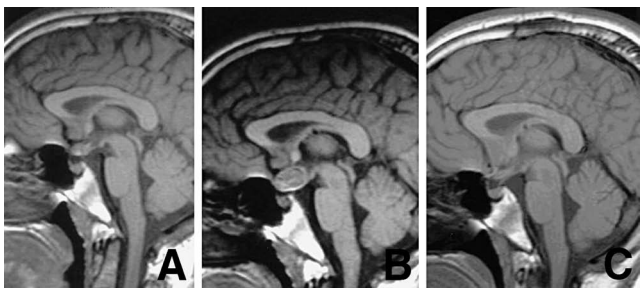

Fig. 2 Sagittal T_1-weighted magnetic resonance (MR) images showing the decreased size after the biopsy (A) but significant enlargement after 9 months (B). Sagittal T_1-weighted MR image performed 6 months after the radical excision (C) showing the cavernous angioma was completely excised and no residual lesion.

region revealed the distorted and enlarged left optic nerve-chiasm complex. The distortion was so great that the chiasm and optic nerve could not be differentiated. Neural tissue had purplish-blackish discoloration indicating intraneural pathology. Neurotomy was performed carefully parallel to the optic nerve. Meticulous microsurgical dissection was performed around the cavernous angioma but en bloc removal was not possible because of the thin lesion walls, so piecemeal excision was done. The lesion consisted of dark blood. Following control of any residual lesion and hemostasis, the surgical wound was closed.

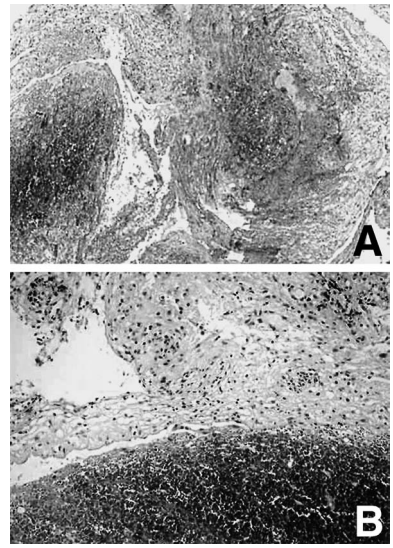

Fig. 3 Photomicrographs showing lumens lined with endothelium and filled with thrombosis, but no elastic fiber or muscle in the walls of the lumens. Presence of hemosiderin pigment in the walls indicates old hemorrhages. Hematoxylin and eosin stain, (A) ×10 and (B) ×40.

Histological examination showed lumens lined with endothelium and filled with thrombosis (Fig. 3). The lumen walls had no elastic fiber or muscle. The presence of hemosiderin pigment in the walls indicated old hemorrhages.

After the operation, his visual deficits persisted but did not get worse. The postoperative course was uneventful and he was discharged without problems. MR imaging 6 months later demonstrated complete removal of the lesion (Fig. 2C). Slight improvement of vision was observed after 1 year as slight clearing of the inferior nasal quadrant in the left eye and reduced temporal hemianopia in the right eye.

Discussion

Cavernous malformations affecting only the cranial nerves are very rare, although cases involving the optic nerve and chiasm, facial-vestibulocochlear complex, hypoglossal nerve, and oculomotor nerve

have been described.[1,3,19,25] Cavernous malformations involving the visual pathway are extremely rare,[1,6,8,9,16,20,23] with only 24 cases of cavernous angioma involving the optic nerve-chiasm complex.[5] Cavernous malformations in the sellar region can also arise from the adjacent brain and dura of the cavernous sinus.[2,7,21] The nomenclature for cavernous angiomas of the optic nerve-chiasm complex is not unified, with optic, optic tract, and chiasmal terminology. Optochiasmatic would be more appropriate, because this term covers all cases.

Optochiasmatic cavernous malformations may manifest as blurred vision, diminished vision and visual loss, and visual field defects.[6,12,13,15,17] Alcohol consumption, pregnancy, and labor are predisposing factors in provoking the symptoms.[12,16] Visual symptoms result from progressive enlargement or bleeding of the cavernous angioma.[11] Hemorrhages can be extralesional or intralesional. Extralesional hemorrhages are most common. Bleeding causes acute development of symptoms whereas enlargement results in progressive symptoms.[24] Differentiation of optochiasmatic cavernous angioma from entities with similar presentations, such as optic neuritis, is important because of the potential for permanent compromise of vision.[10] Optochiasmatic cavernous malformations can also present with subarachnoid hemorrhage and intracerebral hematoma, and may cause headache, confusion, and lethargy.[15,25]

MR imaging is the imaging modality of choice for the identification and follow up of optochiasmatic cavernous angioma.[1,14,23,25] These lesions were difficult to identify preoperatively before the introduction of MR imaging.[23] However, the correct interpretation may not always be possible. MR imaging did not suggest cavernous angioma in some cases.[9,10,23] MR imaging shows optochiasmatic cavernous angioma with blood of different ages with subtle or no enhancement after intravenous contrast administration. The optic nerve-chiasm complex may be enlarged.[1,4,14] Gradient echo imaging is the most sensitive sequence for detecting blood products from recent or chronic hemorrhage.[9]

The main differential diagnoses are meningioma of the sellar region, optic glioma, and thrombosed aneurysm.[4] Meningiomas are typically isointense to gray matter on all pulse sequences, with rather intense and uniform contrast enhancement. Optic gliomas also cause enlargement of the optic nerve and chiasm but are not typically associated with hemorrhage. Thrombosed aneurysm should be related with the main vascular structures and be detectable by angiography.

Preoperative MR imaging of this case demonstrated a lesion causing enlargement of the left optic nerve and chiasm which contained blood of different ages, but no hemosiderin ring. The absence of the hemosiderin ring may have resulted from bleeding occurring directly into the cisterns, and removal of the blood by the cerebrospinal fluid. The serial MR imaging findings of enlargement of the lesion suggest cavernoma rather than old clot, despite the absence of the hemosiderin ring. Computed tomography (CT) demonstrates suprasellar cavernous angioma as a mass with areas of hyperdensity and/or calcification.[1,8,14,16] Such CT findings are nonspecific and may lead to an incorrect diagnosis of tumor or thrombosed aneurysm.[23] CT is mainly useful to provide information about bone details in such cases. We did not perform CT, which would have demonstrated any calcification, if present. Cavernous angiomas are angiographically occult due to thrombosis and low internal flow.[10,14,23] Occasionally a blush may be observed in the capillary phase.[14]

Symptomatic cavernous malformations of the optic nerve-chiasm complex are generally treated by surgical intervention.[5,16,22,23] The eloquence of the tissue should not exclude operative treatment. These tumors are unique intrinsic lesions of the nerves and require neurotomy for excision. During surgical excision, the gliotic interspace between the vascular malformation and normal neural tissue provides a plane of cleavage for dissection which permits total excision without causing new deficits.[22] Surgery can stabilize or improve visual deficits, whereas mild visual worsening is rare.[10] Biopsy of optochiasmatic cavernous angioma is useless, because it will provide no guidance for treatment. Moreover, biopsy may be inconclusive,[5] as in our case. Biopsy may increase the growth rate of the lesion, as in our case, and the risk of hemorrhage persists.

The pterional approach is preferred for removal of optochiasmatic cavernous malformations. Orbitozygomatic and subfrontal approaches have been suggested,[16] but we think that pterional craniotomy is adequate. Resection of cavernous malformations of the optic nerve-chiasm complex is also possible through an eyebrow keyhole.[20] However, complete removal of the lesion is essential because of the possibility of recurrence.[5] Recurrent lesions should also be treated surgically. Some residual lesions may remain stable, so conservative management of such lesions is also an option, but the risk of hemorrhage remains. Second surgery should be considered if the symptoms and findings progress. Asymptomatic optochiasmatic cavernous malformations should be carefully evaluated and considered for possible preventive surgical resec-

tion.[4] Histological examination of cavernous angiomas shows separation of irregular venous channels with thin septa formed by fibrous and collagenous stroma, and no intervening neural parenchyma.[1,6,14]

Optochiasmatic cavernous angioma is rare, so the diagnosis may be difficult and needs special care. Surgical intervention is indicated for decompression of the optic nerve-chiasm complex, and prevention of lesion growth and new hemorrhages. Diagnostic biopsy rather than operative removal is useless, because it may induce rapid growth of the cavernous angioma.

References

1) Arrué P, Thorn-Kany M, Vally P, Lacroix F, Delisle MB, Lagarrigue J, Manelfe C: Cavernous hemangioma of the intracranial optic pathways: CT and MRI. *J Comput Assist Tomogr* 23: 357–361, 1999
2) Bristot R, Santoro A, Fantozzi L, Delfini R: Cavernoma of the cavernous sinus: case report. *Surg Neurol* 48: 160–163, 1997
3) Chow M, Addas B, Sangalang V, Holness R: Cavernous malformation of the hypoglossal nerve: case report and review of the literature. *Can J Neurol Sci* 29: 191–194, 2002
4) Christoforidis GA, Bourekas EC, Baujan M, Drevelengas A, Tzalonikou M: Neuroradiology case of the day. *AJR Am J Roentgenol* 175: 888–890, 2000
5) Deshmukh VR, Albuquerque FC, Zabramski JM, Spetzler RF: Surgical management of cavernous malformations involving the cranial nerves. *Neurosurgery* 53: 352–357, 2003
6) Elmacı İ, Ateş G, Kurtkaya O, Necmettin Pamir M: Chiasmal cavernous malformation. A rare cause of acute visual loss. *J Neurosurg Sci* 44: 226–229, 2000
7) Escott EJ, Rubinstein D, Cajade-Law AG, Sze CI: Suprasellar cavernous malformation presenting with extensive subarachnoid hemorrhage. *Neuroradiology* 43: 313–316, 2001
8) Ferreira NP, Ferreira MP: Optic nerve apoplexy caused by a cavernous angioma: case report. *Neurosurgery* 30: 262–264, 1992
9) Glastonbury CM, Warner JE, MacDonald JD: Optochiasmal apoplexy from a cavernoma. *Neurology* 61: 266, 2003
10) Hassler W, Zentner J, Petersen D: Cavernous angioma of the optic nerve. Case report. *Surg Neurol* 31: 444–447, 1989
11) Houtteville JP: Brain cavernoma: a dynamic lesion. *Surg Neurol* 48: 610–614, 1997
12) Hwang JF, Yau CW, Huang JK, Tsai CY: Apoplectic optochiasmal syndrome due to intrinsic cavernous hemangioma. Case report. *J Clin Neuroophthalmol* 13: 232–236, 1993
13) Iwai Y, Yamanaka K, Nakajima H, Miyaura T: Cavernous angioma of the optic chiasm: case report. *Neurol Med Chir* (*Tokyo*) 39: 617–620, 1999
14) Kehagias DT: A case of headache and disordered vision: cavernous hemangioma of the optic chiasm (2003:8b). *Eur Radiol* 13: 2552–2553, 2003
15) Klein LH, Fermaglich J, Kattah J, Luessenhop AJ: Cavernous hemangioma of optic chiasm, optic nerves and right optic tract. Case report and review of literature. *Virchows Arch A Pathol Anat Histol* 383: 225–231, 1979
16) Maruoka N, Yamakawa Y, Shimauchi M: Cavernous hemangioma of the optic nerve. Case report. *J Neurosurg* 69: 292–294, 1988
17) Mohr G, Hardy J, Gauvin P: Chiasmal apoplexy due to ruptured cavernous hemangioma of the optic chiasm. *Surg Neurol* 24: 636–640, 1985
18) Montanera W, Kucharczyk W: Imaging of sellar and parasellar lesions, *in* Wilkins RH, Rengachary SS (*eds*): *Neurosurgery, ed 2*. New York, McGraw Hill Health Professions Division, International Edition, 1996, pp 1253–1272
19) Ogilvy CS, Pakzaban P, Lee JM: Oculomotor nerve cavernous angioma in a patient with Roberts syndrome. *Surg Neurol* 40: 39–42, 1993
20) Paladino J, Rotim K, Pirker N, Gluncic V, Juric G, Kalauz M: Minimally invasive treatment of cavernous angioma of the optic chiasm: case report. *Minim Invasive Neurosurg* 44: 114–116, 2001
21) Rigamonti D, Pappas CTE, Spetzler RF, Johnson PC: Extracerebral cavernous angiomas of the middle fossa. *Neurosurgery* 27: 306–310, 1990
22) Shibuya M, Baskaya MK, Saito K, Suzuki Y, Ooka K, Hara M: Cavernous malformations of the optic chiasma. *Acta Neurochir* (*Wien*) 136: 29–36, 1995
23) Steinberg GK, Marks MP, Shuer LM, Sogg RL, Enzmann DR, Silverberg GD: Occult vascular malformations of the optic chiasm: magnetic resonance imaging diagnosis and surgical laser resection. *Neurosurgery* 27: 466–470, 1990
24) Warner JE, Rizzo JF III, Brown EW, Ogilvy CS: Recurrent chiasmal apoplexy due to cavernous malformation. *J Neuroophthalmol* 16: 99–106, 1996
25) Zentner J, Grodd W, Hassler W: Cavernous angioma of the optic tract. *J Neurol* 236: 117–119, 1989

Address reprint requests to: Ercan Özer, M.D., Dokuz Eylül Üniversitesi Tip Fakültesi, Nörosirurji AD, 35340 Inciralti, Izmir, Turkey.
e-mail: ercozer@yahoo.com