Check for updates

Received: 14 December 2021 | Revised: 19 February 2022 | Accepted: 27 February 2022

DOI: 10.1002/pbc.29655

Pediatric Blood & Cancer

SIOP INTERNATIONAL SOCIETY OF PAEDIATRIC ONCOLOGY

aspho The American Society of Pediatric Hematology/Oncology

WILEY

LETTER TO THE EDITOR

Abscess-like skin and lung lesions in a patient with acute lymphoblastic leukemia: Pyoderma gangrenosum

To the Editor,

Pyoderma gangrenosum (PG) is a rare ulcerative and neutrophilic dermatosis with unclear pathogenesis, which can be seen at any age.[1–4] PG is generally associated with systemic diseases.[5] Herein, we present a patient who developed PG during treatment for acute lymphoblastic leukemia (ALL).

A 10-year-old female child who was diagnosed with T-cell ALL and treated with ALL-BFM 95 protocol developed painful nodular, abscess-like lesions at the end of the induction therapy. Lesions were detected on the anterior surface of the right tibia and in the left submandibular area. Culture samples were taken and antimicrobial treatment was initiated. In the follow-up, new lesions developed in various parts of the body. There was no growth in any of the cultures and the patient did not respond to treatment. The patient admitted to our center upon the request of her family. Physical examination revealed palpable fluctuating, abscess-like lesions in the interscapular area, under the mandible to the left of the midline, lateral to the right lumbar region in the abdomen, and on the skin in the left femur region (Figure 1A,B). Thorax computed tomography (CT) imaging showed circular-shaped consolidations in both lungs. Magnetic resonance imaging (MRI) revealed cystic lesions in the right paravertebral muscle tissue and the right paravertebral subcutaneous fatty tissue (Figure 1C,D,E). Work-up for immune deficiency including genetic analysis revealed normal results. Despite the widespread lesions, general condition of the patient was well, although there was an increment in the acute phase reactants (CRP 84.4 mg/L and ESR 80 mm/h).

An excisional biopsy was performed from the subcutaneous lesion in the middle diaphysis of the left thigh. Histopathological examination of the lesions demonstrated "dense mixed inflammatory cell infiltration and chronic granulation tissue containing neutrophils." Note that 1 mg/kg/day methylprednisolone was started with the initial diagnosis of PG. After the treatment, the patient's lesions disappeared completely and the acute phase reactants returned to normal within 3 weeks. When the patient was evaluated retrospectively, it was observed that lesions appeared with tapering of steroids at the end of induction treatment for leukemia and increased with the use of granulocyte colony-stimulating factor (GCSF). Her lesions had reoccurred after repeated use of GCSF. Informed consent for sharing images and content was obtained from the patient and her family.

PG is a necrotizing neutrophilic dermatosis, which may precede various systemic diseases, coexist with, or follow them.[6,7] Approximately half of the patients with PG are thought to have an underlying inflammatory disease and it is thought to be related to immune-mediated mechanisms.[2] Lesions developed in our patient while reducing immunosuppressive therapy. In addition, PG can be induced by the use of drugs such as GCSF in patients receiving chemotherapy.[2,8–10] Supportingly, our patient had received GCSF, when the first lesions appeared and her lesions had reoccurred after repeated use of GCSF. The prevalence of PG is estimated to be 0.63 per 100,000 patients, of which less than 5% are children. The estimated prevalence of accompanying malignant diseases is 4.5%–9% in these patients.[11,12] Acute myeloid leukemia has been reported to be the most common hematological malignancy underlying PG.[2] In the literature, there are few pediatric ALL patients presented with PG.[4,12] Adult patients with ALL and PG have been reported more frequently than pediatric patients in literature.[13,14]

As in our patient, this diagnosis should be considered when there are nonhealing ulcers and all microbiological causes are excluded. Morphologically, lesions start as pustules and may progress to ulceration or deep erosions. The lesions are severely painful and this provides a diagnostic clue.[15] The most common extracutaneous manifestation of PG is pulmonary followed by ocular and visceral involvement. Clinical onset in pulmonary involvement ranges from asymptomatic to severe respiratory failure. Radiological presentations are observed in a wide range from cavitating or noncavitating lesions to pulmonary infiltrates or lobular consolidation. Our patient was found to have asymptomatic, noncavitating consolidated pulmonary lesions that completely resolved after treatment with corticosteroids. Due to its rarity, the diagnosis of PG is difficult. Diagnostic criteria for PG proposed by Maverakis et al.[16] and Su et al.[17] may be also used for pediatric patients. Skin biopsy is essential to exclude other causes of ulceration including vasculitic conditions. Even though the clinical presentation is heterogeneous, the histopathological evaluation reveals sterile neutrophilic infiltration in all patients.

There is no gold standard treatment approach in PG. In addition to treating the underlying disease, local wound care and systemic therapy should be used together. Options for systemic therapy include high-dose corticosteroids, immunosuppressive agents, and cyclosporine.[12] Similar to cutaneous involvement, treatment of pulmonary involvement relies on the use of systemic corticosteroids and other immunosuppressant agents.[18] In our patient, we used systemic steroid therapy in addition to local wound care and the treatment response was excellent. Since we were concerned about the drugs that stimulate neutrophils, like GCSF, which would contribute to the formation of lesions; care was taken not to use any GCSF during therapy in our patient.

© 2022 Wiley Periodicals LLC.

15455017, 2022, 10, Downloaded from https://onlinelibrary.wiley.com/doi/10.1002/pbc.29655 by Dokuz Eylul University, Wiley Online Library on [23/11/2022]. See the Terms and Conditions (https://onlinelibrary.wiley.com/terms-and-conditions) on Wiley Online Library for rules of use; OA articles are governed by the applicable Creative Commons License

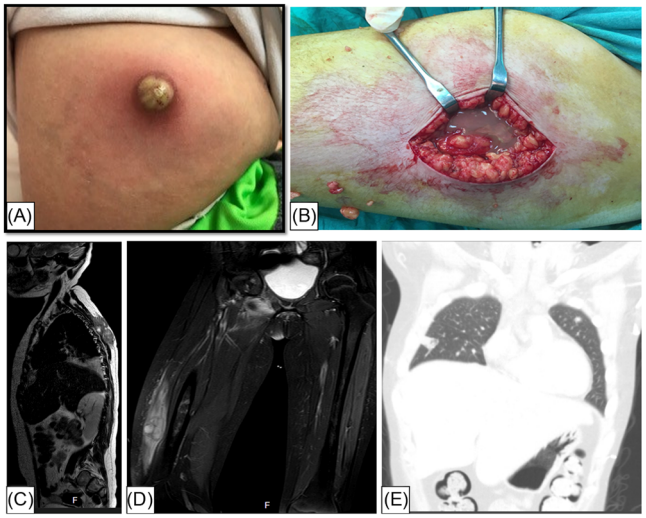

FIGURE 1 (A) Abscess in the right flank area of the patient. (B) Intraoperative view of the abscess located in the middle diaphyseal part of the left thigh. (C) Cystic lesions in the paravertebral subcutaneous fatty tissue that may be compatible with abscesses. (D) Liquefied lesions in soft tissues in the distal diaphyseal part of the right thigh, the middle diaphyseal part of the left thigh, and the right obturator foramen. (E) Consolidation areas in the middle and lower lobes of the right lung

In conclusion, PG is an autoinflammatory neutrophilic dermatosis that may occur in the course of treatment of ALL, and drugs stimulating PG, such as GCSF, should be kept in mind in the presence of abscess-like, recurrent, noncultured, and extremely painful lesions.

CONFLICT OF INTEREST

The authors declare that there is no conflict of interest.

INFORMED CONSENT

Informed consent for sharing images and content was obtained from the patient and her family.

Şefika Akyol
Özlem Tüfekçi
Birsen Baysal
Şebnem Yılmaz
Hale Ören

Department of Pediatric Hematology, Faculty of Medicine, Dokuz Eylül University, İzmir, Turkey

Correspondence
Şefika Akyol, Division of Pediatric Hematology and Oncology, Faculty of Medicine, Department of Pediatrics, Dokuz Eylul University, İnciraltı Mahallesi Mithatpaşa cad. no:1606 Balçova, İzmir, Turkey.
Email: drsefikaakyol@gmail.com

ORCID

Şefika Akyol https://orcid.org/0000-0003-0051-4274
Özlem Tüfekçi https://orcid.org/0000-0002-0721-1025
Birsen Baysal https://orcid.org/0000-0001-7995-7347
Şebnem Yılmaz https://orcid.org/0000-0001-7874-3734
Hale Ören https://orcid.org/0000-0001-5760-8007

REFERENCES

1. Sakiyama M, Kobayashi T, Nagata Y, Fujimoto N, Satoh T, Tajima S. Bullous pyoderma gangrenosum: a case report and review of the published work. *J Dermatol*. 2012;39(12):1010-1015.
2. Mehrtens SH, Crawley JM. Pyoderma gangrenosum. *Br J Hosp Med (Lond)*. 2015;76(11):C173-C176.
3. Teagle A, Hargest R. Management of pyoderma gangrenosum. *J R Soc Med*. 2014;107(6):228-236.
4. Kechichian E, Haber R, Mourad N, El Khoury R, Jabbour S, Tomb R. Pediatric pyoderma gangrenosum: a systematic review and update. *Int J Dermatol*. 2017;56(5):486-495.
5. Vacas AS, Bollea-Garlatti ML, Torre AC, Galimberti RL. Bullous pyoderma gangrenosum as a predictor of hematological malignancies. *An Bras Dermatol*. 2018;93(1):133-134.
6. Batista MD, Fernandes RL, Rocha MAD, et al. Bullous pyoderma gangrenosum and myelodysplastic syndrome. *An Bras Dermatol*. 2006;81:309-312.
7. Wallach D, Vignon-Pennamen MD. Pyoderma gangrenosum and Sweet syndrome: the prototypic neutrophilic dermatoses. *Br J Dermatol*. 2018;178(3):595-602.
8. Montagnon CM, Fracica EA, Patel AA, et al. Pyoderma gangrenosum in hematologic malignancies: a systematic review. *J Am Acad Dermatol*. 2020;82(6):1346-1359.
9. Miall FM, Harman K, Kennedy B, Dyer MJ. Pyoderma gangrenosum complicating pegylated granulocyte colony-stimulating factor in Hodgkin lymphoma. *Br J Haematol*. 2006;132(1):115-116.
10. Wu BC, Patel ED, Ortega-Loayza AG. Drug-induced pyoderma gangrenosum: a model to understand the pathogenesis of pyoderma gangrenosum. *Br J Dermatol*. 2017;177(1):72-83.
11. Gupta AS, Ortega-Loayza AG. Pyoderma gangrenosum: a too often overlooked facultative paraneoplastic disease. *Ann Hematol*. 2019;98(9):2247-2248.
12. Bakhshi S, Sethuraman G, Singh MK, Arya LS. Atypical pyoderma gangrenosum as a manifestation of childhood acute lymphoblastic leukemia. *Pediatr Dermatol*. 2005;22(6):543-545.
13. Zheng W, Zhao X, Feng J, Huang H. Successful treatment of pyoderma gangrenosum with skin grafting in a patient with acute lymphoblastic leukemia. *Dermatol Surg*. 2020;46(3):421-423.
14. Borda LJ, Mervis JS, Kirsner RS. Unilateral granuloma annulare in association with pyoderma gangrenosum and chronic lymphocytic leukemia. *Dermatol Online J*. 2019;25(3):13030/qt62c9d1ws.
15. Al Ghazal P, Herberger K, Schaller J, et al. Associated factors and comorbidities in patients with pyoderma gangrenosum in Germany: a retrospective multicentric analysis in 259 patients. *Orphanet J Rare Dis*. 2013;8:136.
16. Maverakis E, Ma C, Shinkai K, et al. Diagnostic criteria of ulcerative pyoderma gangrenosum: a Delphi consensus of international experts. *JAMA Dermatol*. 2018;154(4):461-466.
17. Su WP, Davis MD, Weenig RH, Powell FC, Perry HO. Pyoderma gangrenosum: clinicopathologic correlation and proposed diagnostic criteria. *Int J Dermatol*. 2004;43(11):790-800.
18. Miller J, Yentzer BA, Clark A, Jorizzo JL, Feldman SR. Pyoderma gangrenosum: a review and update on new therapies. *J Am Acad Dermatol*. 2010;62(4):646-654.

15455017, 2022, 10, Downloaded from https://onlinelibrary.wiley.com/doi/10.1002/pbc.29655 by Dokuz Eylul University, Wiley Online Library on [23/11/2022]. See the Terms and Conditions (https://onlinelibrary.wiley.com/terms-and-conditions) on Wiley Online Library for rules of use; OA articles are governed by the applicable Creative Commons License