Check for updates

Clinical Research Report

Journal of INTERNATIONAL MEDICAL RESEARCH

Journal of International Medical Research
2019, Vol. 47(1) 411–419
© The Author(s) 2018
Article reuse guidelines:
sagepub.com/journals-permissions
DOI: 10.1177/0300060518803028
journals.sagepub.com/home/imr
SAGE

Cerebellar volume in early-onset schizophrenia and its association with severity of symptoms

Aylin Özbek[1], Nüket Göçmen Mas[2], Serkan Turan[1], Bari Ay[1], Burcu Serim Demirgören[1], Gökşin Nilüfer Yonguç[2], Selim Karabekir[3], Ayşe İpek Polat[4], Ayşe Semra Hız[4] and Özlem Gencer Kıdak[1]

Abstract

Objectives: This study aimed to investigate whether early-onset schizophrenia (EOS) cases differ from controls regarding volumes of the total cerebellum and the right and left cerebellar hemispheres, and volumetric asymmetry. Correlations of cerebellar volumes and asymmetry indices with severity of symptoms and general functioning in cases of EOS were also assessed.

Methods: Adolescents with EOS (n = 23) were compared with controls (n = 23). Sociodemographic and clinical data, and magnetic resonance imaging scans that were acquired for routine clinical purposes were collected retrospectively. Cerebellar volumes were evaluated using the stereological method. Asymmetry indices were subsequently calculated. Scores of the Positive and Negative Syndrome Scale and the Children's Global Assessment Scale were used to assess the severity of symptoms and general functionality.

Results: There were no significant differences in any of the cerebellar volumes and asymmetry indices between the two groups. Neither cerebellar volumes nor asymmetry indices were correlated with the severity of symptoms and general functionality in EOS.

[1]Department of Child and Adolescent Psychiatry, Faculty of Medicine, Dokuz Eylül University, Izmir, Turkey
[2]Department of Anatomy, Faculty of Medicine, Dokuz Eylül University, Izmir, Turkey
[3]Department of Neurosurgery, Faculty of Medicine, Dokuz Eylül University, Izmir, Turkey
[4]Department of Child Neurology, Faculty of Medicine, Dokuz Eylül University, Izmir, Turkey

Corresponding author:
Aylin Özbek, Department of Child and Adolescent Psychiatry, Dokuz Eylül University, Balçova, İzmir, 35340, Turkey.
Email: aylinozbek@deu.edu.tr

Creative Commons Non Commercial CC BY-NC: This article is distributed under the terms of the Creative Commons Attribution-NonCommercial 4.0 License (http://www.creativecommons.org/licenses/by-nc/4.0/) which permits non-commercial use, reproduction and distribution of the work without further permission provided the original work is attributed as specified on the SAGE and Open Access pages (https://us.sagepub.com/en-us/nam/open-access-at-sage).

Conclusions: Our findings suggest that the early-onset form of schizophrenia does not show apparent volumetric changes of the cerebellum. Additionally, the neural circuits involved in formation of symptomatology may not reflect any correlation with cerebellar volumes at mid-adolescence.

Keywords
Early-onset schizophrenia, cerebellum, stereology, magnetic resonance imaging, Positive and Negative Syndrome Scale (PANSS), general functionality

Date received: 26 June 2018; accepted: 3 September 2018

Introduction

Early-onset schizophrenia (EOS), defined as the onset of psychosis before 18 years old, is a severe and rare form of schizophrenia.[1] The cortico-thalamic-cerebellar-thalamic-cortical loops have been proposed as a basis for cognitive dysmetria underlying the cognitive deficits and symptoms that are observed during the course of EOS.[2] The term cognitive dysmetria points to the importance of the cerebellum for investigating schizophrenia because the cerebellum might play roles in higher cortical functions of working memory, the theory of mind processes, language processing, cognition, behavior, and emotional regulation.[3–5]

Cerebellar volumetric abnormalities have been reported in adult patients with schizophrenia, although some studies showed controversial results.[6–9] Szeszko et al.[10] reported that adult male patients with schizophrenia had significantly reversed anterior and posterior asymmetry compared with healthy controls, despite no differences in regional cerebellar volumes. Moreover, measure of cerebellar asymmetry was significantly correlated with increased negative symptoms.[10]

Although the cerebellum has received much interest in adult-onset schizophrenia (AOS), there are limited data for its involvement in EOS. A previous study showed that bilateral anterior cerebellar lobes and anterior and total vermis volumes were smaller in childhood-onset schizophrenia (COS) compared with controls.[11] Moreover, the COS group diverged from controls over time in total, left, right, and bilateral posterior cerebellar volumes. Similarly, Keller et al.[12] reported a progressive loss in cerebellar volume during adolescence in COS cases. To the best of our knowledge, no studies have investigated cerebellar volumetric asymmetry in EOS.

Clinical reflections of cerebellar volumetric findings in EOS still need to be studied. In one of the few studies that examined cerebellar volume and symptom severity in EOS, Yoshihara et al.[13] suggested that the severity of positive symptoms was positively related to white matter volume of the cerebellar vermis and the cerebellar hemispheres. Another study suggested that better general functionality was associated with larger total vermis volume and no other clinical measure was correlated with volumes of any other cerebellar structures.[11]

This study aimed to determine whether EOS cases differ from controls in terms of total cerebellar volume, volumes of the right and left cerebellar hemispheres, and cerebellar volumetric asymmetry. We also investigated cerebellar volumes and asymmetry indices in relation to the severity of

symptoms and the level of general functionality of EOS cases. We hypothesized that EOS cases have smaller cerebellar volumes compared with controls, and smaller cerebellar volumes are associated with an increased severity of symptoms and worse general functionality.

Methods

Ethical approval

The study was approved by the Ethics Committee of Dokuz Eylül University, İzmir, Turkey (Decision number: 2016/27-33). Because the data of the study were based on hospital records, no individual consent was obtained other than routine consent obtained during admission to the hospital.

Sample

The study was retrospective in design. The cases of the study comprised all of the right-handed children and adolescents who were diagnosed with EOS based on the Diagnostic and Statistical Manual of Mental Disorders-IV.[14] These patients received treatment between 2005 and 2017 at the inpatient unit of Child and Adolescent Mental Health Services at Dokuz Eylül University. This unit, located in Izmir Turkey, has been a member of the Quality Network for Inpatient Child and Adolescent Mental Health Services since 2005, which is an initiative of the Royal College of Psychiatrists in the United Kingdom.

The control group was composed of age- and sex-matched right-handed children and adolescents who were admitted to the Child Neurology Department of Dokuz Eylül University for headaches. Those who had a normal neurological examination and normal magnetic resonance imaging (MRI) scan results, those who did not have a history of any neurological disorder, head trauma, or any chronic disorder including any psychiatric disorder, and those who had no history of admission to psychiatric services for any reason were recruited in the study.

Instruments and procedure

Sociodemographic and clinical data were retrospectively collected from the hospital records of patients with EOS and controls. Variables, such as birth date, sex, handedness data (based on observation and self-report), medication status, date of MRI image acquisition, and age at MRI image acquisition, were recorded.

As a routine procedure, clinical diagnosis of all children and adolescents who were treated at the unit was determined and refined by the consensus of the inpatient unit team by clinical assessment, follow-up, and application of relevant psychometric tests and clinical scales. For the EOS group, the Positive and Negative Syndrome Scale (PANSS) was routinely applied for measuring the severity of positive and negative symptoms, and general psychopathology.[15] Additionally, the level of general functionality was assessed by The Children's Global Assessment Scale (CGAS).[16] Scores for all four scales of the PANSS and CGAS at the date of MRI acquisition were also recorded on a data collection form that was developed for the purposes of the study.

MRI acquisition and stereological analysis

As part of the clinical routine of the unit, all EOS cases were required to have MRI scans to aid in differential diagnosis. MRI scans of cases and controls were collected from the archives of the hospital image recording system. An MRI machine (1.5 Tesla Gyroscan Achieva, release 8:1; Philips Medical Systems, Best, the Netherlands) was used for all of the patients.

Stereological analysis was conducted for volumetric measurements of cerebellar volumes. Stereology has been used as a novel, alternative, volumetric analysis technique for radiological anatomy.[17,18] A recent study showed the high reliability of stereology compared with fully automated and semi-automated segmentation techniques and with the current gold standard method of manual segmentation tecniques.[18] This technique is based on the Cavalieri principle and is robust, unbiased, and efficient because it requires no assumptions about the structure (orientation or shape) under assessment.[18] Accordingly, in this study, we used the stereological (Cavalieri's) method for volumetric measures of the cerebellum. Standard T1-weighted sagittal plane (3 mm) slices were obtained with a 1.5-T magnetic resonance (MR) machine. Two observers who were blinded to the groups conducted stereological measurements of the total and hemicerebellar volumes. An optimal plane was taken as the smallest diameter of anisotropic structures that can be measured in two-dimensional analyses on sagittal MRI sections. This value was multiplied by the cross-sectional thickness and the volume was obtained. A uniform point grid with a point-associated area of 0.625 cm^2 was randomly superimposed on each MR image using the grid. Points that hit the cerebellum were manually counted for volume estimation. Volume estimation was accomplished by Cavalieri's principle as described previously[18] using the formula shown below:

$$V = t \times \left[\left((SU) \times d\right)/SL\right] 2 \times \Sigma P$$

where t is the section thickness, SU is the scale unit (the real length of the scale marked on the MRIs), d is the distance between two points in the point grid, SL is the scale length (the actual measure of the scale on MRI), and P is the number of points counted.

All data were entered in a previously-prepared Microsoft excel spreadsheet for automatic calculation of the results of the above-mentioned formula and the statistical evaluation parameters. These parameters included the nugget variance and the coefficient of error (CE), which provide information to infer the precision of volumetric extraction.[18]

To evaluate the interhemispheric asymmetry between the hemispheres, middle sections were identified by clear visualization of the cerebral aqueduct. The point counts belonging to the middle section were divided by two and the results were added to the total point counts for each hemisphere separately. Therefore, a volume value for each cerebellar hemisphere was measured. The stereological point counting technique is shown in Figure 1.

Asymmetry indices were calculated according to the following formula:

$$\left[\left((\text{right} - \text{left})/(\text{right} + \text{left})\right) \times 100\right]$$

Statistical analysis

Data analyses were performed with IBM SPSS Statistics for Windows, version 24.0 software (IBM Corp., Armonk, NY, USA). The Kolmogorov–Smirnov test was used to assess the normality of distribution of the

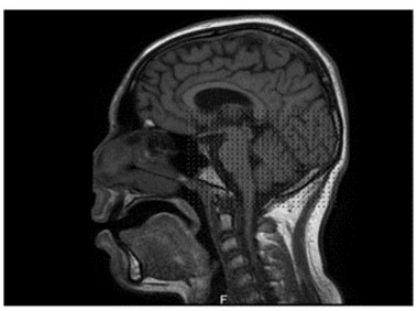

Figure 1. The stereological point counting technique

variables and Levene's test was used to assess the homogeneity of variance in the different groups. The Student's t test and paired sample t test were used for independent and dependent groups, respectively. The Pearson moment correlation was applied for correlations. A P value less than 0.05 was considered statistically significant.

Results

There were a total of 26 right-handed patients with EOS who were treated at the unit between 2005 and 2017. MRI scans could not be retrieved from the archives of the hospital image recording system for three patients. Therefore, the study was conducted with total of 23 children and adolescents with EOS. None of the patients were medication-naive and all of them had active positive and negative symptoms of EOS during MRI scan acquisition.

The EOS group (n = 23) and the age- and sex-matched control group (n = 23) each comprised 13 boys and 10 girls. The mean (± standard deviation) age of participants was 15.48 ± 1.24 years (13–17 years) in the EOS group and 15.52 ± 1.20 years (13–17 years) in the control group. There was no significant difference in age between the groups.

Results for clinical scales in the EOS group

Mean scores for PANSS-positive (PANSS-P), PANSS-negative (PANSS-N), PANSS-general psychopathology (PANSS-G), PANSS-total (PANSS-T), and the CGAS in EOS cases were 25.15 ± 8.18, 31.78 8.27, 55.11 ± 13.80, 108.86 ± 27.70, and 31.78 ± 11.23, respectively. PANSS-P and PANSS-N scores were missing in four patients, PANSS-G scores were not available for five patients, and PANSS-T scores were missing for two patients.

Comparison of cerebellar volumes and cerebellar volumetric asymmetry indices between the groups

There were no significant differences in total cerebellar volume, volumes of the right and left cerebellar hemispheres, and cerebellar asymmetry indices between the EOS and control groups (Table 1). In the EOS group, the mean CE value was 0.009 ± 0.0037 for the right and 0.009 ± 0.0037 for the left hemispheres. In the control group, mean CE values for the right and left hemispheres were 0.008 ± 0.0017 and 0.009 ± 0.0032, respectively. All of the CE values were in the acceptable range, which reflected the reliability of the stereological measurements.[19]

Table 1. Comparison of cerebellar volumes and cerebellar asymmetry indices between patients with EOS and controls.

	Mean (standard deviation)			Confidence interval (95%)	
Cerebellar variables	EOS (n = 23)	Controls (n = 23)	P	Lower	Upper
Total cerebellar volume (cm^3)	104.74 (1.52)	103.95 (2.72)	0.235	−2.09	0.52
Right cerebellar hemispheric volume (cm^3)	52.99 (0.91)	52.50 (1.43)	0.182	−1.19	0.23
Left cerebellar hemispheric volume (cm^3)	51.75 (0.78)	51.44 (1.38)	0.367	−0.97	0.36
Asymmetry indices	1.18 (0.71)	1.02 (0.70)	0.445	−0.58	0.26

Table 2. Correlations of cerebellar volumes and cerebellar volumetric asymmetry indices with the severity of symptoms and the level of general functioning in patients with EOS.

	Total cerebellar volume	Right cerebellar hemispheric volume	Left cerebellar hemispheric volume	Cerebellar volumetric asymmetry indices
PANSS-P (n = 19)				
r*	0.234	0.202	0.218	0.002
P	0.336	0.407	0.370	0.995
PANSS-N (n = 19)				
r*	0.007	−0.016	0.032	−0.056
P	0.977	0.948	0.896	0.821
PANSS-G (n = 18)				
r*	0.031	0.031	0.024	0.011
P	0.903	0.902	0.926	0.967
PANSS-T (n = 21)				
r*	0.089	0.105	0.053	0.064
P	0.701	0.652	0.821	0.784
CGAS (n = 23)				
r*	−0.252	−0.143	−0.323	0.169
P	0.247	0.514	0.133	0.441

*Pearson correlation coefficient.
PANSS-P: Positive and Negative Syndrome Scale-positive, PANSS-N: Positive and Negative Syndrome Scale-negative, PANSS-G: Positive and Negative Syndrome Scale-general psychopathology, PANSS-T: Positive and Negative Syndrome Scale-total, CGAS: Children's Global Assessment Scale.

Correlation of cerebellar volumes and cerebellar volumetric asymmetry indices with the severity of symptoms and the level of general functioning in the EOS group

Total cerebellar volume, volumes of the right and left cerebellar hemispheres, and cerebellar volumetric asymmetry indices did not show any significant correlations with PANSS-P, PANSS-N, PANSS-G, PANSS-T, and CGAS scores (Table 2).

Discussion

Our study showed that, in patients with EOS, none of the cerebellar volumetric measures, including asymmetry indices, were different from controls. Neither cerebellar volumes nor asymmetry indices were correlated with positive and negative symptom severity, severity of general psychopathology, and general function.

Comparison of our findings with previous research is difficult because few studies have focused on the cerebellum in EOS. Consistent with our findings, Yoshihara et al.[13] suggested that the cerebellum showed no significant structural differences in EOS. In contrast to this finding, smaller total cerebellar volumes and reduced volumes of the vermis and bilateral posterior and anterior lobes have been reported in EOS in other studies.[11,12,20] Structural MRI studies involving the cerebellum for patients with AOS have also shown mixed results. Some studies reported smaller volumes of the total cerebellum, right and left hemispheres, vermis, and anterior, bilateral superior and posterior cerebellar lobes in AOS compared with controls, whereas some studies did not show any significant differences in these variables.[6,8,9,21]

Such inconsistency of findings among studies might be related to methodological issues, such as sample characteristics. Our sample consisted of adolescents with an average age of 15 years, with the youngest being 13 years old and the oldest 17 years old. Keller et al.[12] reported that although the COS and control groups did not differ in cerebellar volumes at the age of 14, the COS group had a progressive loss of cerebellar volume until the age of 22. This resulted in a significantly smaller total cerebellar volume in the COS group compared with controls. Similarly, Greenstein et al.[11] studied a sample with a mean age of 16 years where the COS and control groups initially did not differ from each other in total cerebellar volume. However, the COS group had a significant reduction in cerebellar volume by the age of 23. Data from these previous studies suggest that the average age of our sample might have been at a point where apparent volumetric differences between the EOS and controls were not yet evident. MRI follow-up of our patients to early adulthood may yield different results.

Other than volumetric measures of the cerebellum, some studies on AOS investigated the presence of reversed hemispheric asymmetry in schizophrenia compared with healthy controls. Several MRI studies have shown that a pattern of asymmetry is present in all healthy humans and the asymmetry index is positive because the right hemisphere volume is larger than the left hemisphere volume.[10,22,23] It has been suggested that cerebellar asymmetry in humans may be associated with handedness patterns.[23] However, some data do not support these previous findings. Levitt et al.[24] found that patients with AOS and healthy subjects showed left-greater-than right cerebellar volume asymmetry and that there was a trend for this asymmetry to be larger in patients with AOS. Loeber et al.[25] reported that their samples of patients with AOS and healthy subjects demonstrated right-greater-than-left hemispheric volume asymmetry, but this asymmetry was significantly smaller in patients with AOS. Szeszko et al.[10] showed that although patients and healthy subjects did not differ in any of the cerebellar volumes, cerebellar asymmetry was reversed in patients with AOS. They proposed that gross volumetric abnormalities of the cerebellar hemispheres do not play a role in the pathophysiology of schizophrenia. A neurodevelopmental defect involving aberrant growth gradients may account for the findings of reversed cerebellar asymmetry instead. To the best of our knowledge, no studies have investigated cerebellar asymmetry in EOS. Our findings of no significant differences in cerebellar asymmetry indices between patients with EOS and age-, sex-, and handedness-matched controls is a preliminary report regarding this issue requiring further inquiry.

Morphological changes that might contribute to formation of symptomatology have been the focus of schizophrenia research. However, the number of studies that have examined the correlations of cerebellar volumes and severity of symptoms in EOS is small compared with AOS studies. Yoshiara et al.[13] reported that the positive symptom score of PANSS was positively related to the volume of white matter in the cerebellar vermis region and negatively correlated with the volume of white matter in the bilateral cerebellar hemispheric regions in EOS. Their finding regarding the cerebellar vermis is consistent with a previous AOS study, which showed a positive correlation between white matter volume of the vermis and the severity of positive symptoms.[24] Our findings suggest that total cerebellar volume and the volume of the left and right cerebellar hemispheres, as well as cerebellar asymmetry indices, are not correlated with the severity of positive and negative symptoms, general

psychopathology, and general functioning in cases of EOS. Unfortunately, our retrospective study design prevented us from measuring the vermis area, which hindered comparison of our data with previous studies reporting associations of symptoms and the cerebellar vermis. A future prospective study, with MRI sequences to permit volumetric estimations of smaller regions of the cerebellum, is required.

The retrospective design of this study provides some advantages, such as enabling accumulation of data for a rare disorder, convenience for the adolescents who were the study sample, and low cost. However, our study has some limitations. None of our patients with EOS were medication-free because the sample consisted of patients from a tertiary level medical center. Therefore, the patients had received variety of medication before they were admitted to the inpatient unit where our study was performed. We cannot rule out the possibility that our findings reflect the effects of neuroleptic medication. An additional limitation is that our sample had a low level of functioning and had severe psychotic symptomatology during MRI acquisition. This prevented us from presenting cognitive measures because psychometric testing was not possible owing to clinical reasons. Another limitation is the MRI slice thickness used. We used 3-mm slices to measure cerebellar volumes.[26,27] Although a study that compared the effects of slice thickness on brain MRI image analysis showed that a 3-mm slice thickness was sufficient for analysis,[28] thinner slices might have provided different results. Therefore, caution is required when interpreting our results.

Even though our study has several limitations, we provide further knowledge in an area of limited evidence regarding neuroimaging of the cerebellum in patients with schizophrenia whose age of onset is as early as mid-adolescence. Large-scale, multicenter studies involving follow-up of cases are required to identify cerebellar morphological changes and associations of these changes with clinical presentation in young populations with EOS.

Acknowledgements

The authors would like to thank all of the participants of this study.

Declaration of conflicting interest

The authors declared no potential conflicts of interest with respect to the research, authorship, and/or publication of this article.

Funding

The authors received no financial support for the research, authorship, and/or publication of this article.

References

1. Kodish I and McClellan JM. Early onset schizophrenia. In: Dulcan MK (ed) *Dulcan's textbook of child and adolescent psychiatry*. Second ed. Arlington: American Psychiatric Association Publishing, 2015; pp.389–402.
2. Andreasen NC, Paradiso S and O'Leary DS. "Cognitive dysmetria" as an integrative theory of schizophrenia: a dysfunction in cortical-subcortical-cerebellar circuitry? *Schizophr Bull* 1998; 24: 203–218.
3. Bostan AC, Dum RP and Strick P. Cerebellar networks with the cerebral cortex and basal ganglia. *Trends Cogn Sci* 2013; 17: 241–254.
4. Schutter DJ and van Honk J. The cerebellum on the rise in human emotions. *Cerebellum* 2005; 4: 290–294.
5. Mothersill O, Knee-Zaska J and Donohoe G. Emotion and theory of mind in schizophrenia— investigating the role of the cerebellum. *Cerebellum* 2016; 15: 357–368.
6. Moberget T, Doan NT, Kaufmann T, et al. Cerebellar volume and cerebellocerebral structural covariancein schizophrenia: a multisite mega-analysis of 983 patients and

1349 healthy controls. *Mol Psychiatry* 2018; 23: 1512–1520.
7. Laidia C, d'Albisa M, Wessaf M, et al. Cerebellar volume in schizophrenia and bipolar i disorder with and without psychotic features. *Acta Psychiatr Scand* 2015; 131: 223–233.
8. Andreasen NC, Flashman L, Flaum M, et al. Regional brain abnormalities in schizophrenia measured with magnetic resonance imaging. *JAMA* 1994; 272: 1763–1769.
9. Staal WG, Hulshoff Pol HE, Schnack HG, et al. Structural brain abnormalities in patients with schizophrenia and their healthy siblings. *Am. J Psychiatry* 2000; 157: 416–421.
10. Szeszko PR, Gunning-Dixon F, Ashtari M, et al. Reversed cerebellar asymmetry in men with first-episode schizophrenia. *Biol Psychiatry* 2003; 53: 450–459.
11. Greenstein D, Lenroot R, Clausen L, et al. Cerebellar development in childhood onset schizophrenia and non-psychotic siblings. *Psychiatry Res* 2011; 193: 131–137.
12. Keller A, Castellanos FX, Jeffries A, et al. Progressive loss of cerebellar volume in childhood-onset schizophrenia. *Am J Psychiatry* 2003; 160: 128–133.
13. Yoshihara Y, Sugihara G, Matsumoto H, et al. Voxel-based structural magnetic resonance imaging (MRI) study of patients with early onset schizophrenia. *Ann Gen Psychiatry* 2008; 7: 25.
14. American Psychiatric Association. *Diagnostic and statistical manual of mental disorders*. 4th ed.Washington, DC: American Psychiatric Association Publishing, 1991.
15. Kostakoğlu E, Batur S, Tiryaki A, et al. Pozitif ve Negatif Sendrom Ölçeğinin (PANSS) Türkçe Uygulamasının geçerlik ve güvenirliği. *Türk psikoloji dergisi* 1999; 14: 23–32.
16. Nilsen TS, Handegard BH, Eisemann M, et al. Predictors of rate of change for children and youth with emotional disorders: a naturalistic observational study. *Child Adolesc Psychiatry Ment Health* 2016; 10: 11.
17. Zeinali R, Keshtkar A, Zamani A, et al. Brain volume estimation enhancement by morphological image processing tools. *J Biomed Phys Eng* 2017; 7: 379–388.
18. Theophilus NA, Leila N, Migle M, et al. A comparative study of segmentation techniques for the quantification of brain subcortical volume. *Brain Imaging Behav* 2018. doi: 10.1007/s11682-018-9835-y.
19. Gundersen HJ and Jensen EB. The efficiency of systematic sampling in stereology and its prediction. *J Microsc* 1987; 147(Pt 3): 229–263.
20. Ordóñez AE, Luscher Z and Gogtay N. Neuroimaging findings from childhood onset schizophrenia patients and their non-psychotic siblings. *Schizophr Res* 2016; 173: 124–131.
21. Bottmer C, Bachmann S, Pantel J, et al. Reduced cerebellar volume and neurological soft signs in first-episode schizophrenia. *Psychiatry Res* 2005; 140: 239–250.
22. Bilder R, Wu H, Bogerts B, et al. Absence of regional hemispheric volume asymmetries in first-episode schizophrenia. *Am J Psychiatry* 1994; 151: 1437–1447.
23. Snyder PJ, Bilder RM, Wu H, et al. Cerebellar volume asymmetries are related to handedness: a quantitative MRI study. *Neuropsychologia* 1995; 33: 407–419.
24. Levitt JJ, McCarley RW, Nestor PG, et al. Quantitative volumetric MRI study of the cerebellum and vermis in schizophrenia: clinical and cognitive correlates. *Am J Psychiatry* 1999; 156: 1105–1107.
25. Loeber RT, Clinton CM and Yurgelun-Todd DA. Morphometry of individual cerebellar lobules in schizophrenia. *Am J Psychiatry* 2001; 158: 952–954.
26. Gocmen MN, Yilmaz KO, Bafi O, et al. Evaluation of cerebellar asymmetry with vertigo cases: a stereological study. *Turk Neurosurg* 2009; 19: 15–20.
27. Grossman R, Hoffman C, Mardor Y, et al. Quantitative MRI measurements of human fetal brain development in utero. *Neuroimage*. 2006; 33: 463–470.
28. Savio SJ, Harrison LC, Luukkaala T, et al. Effect of slice thickness on brain magnetic resonance image texture analysis. *Biomed Eng Online* 2010; 9: 60. doi: 10.1186/1475-925X-9-60.