The Turkish Journal of Pediatrics 2022; 64: 736-740
https://doi.org/10.24953/turkjped.2021.4855

Case Report

A novel *Mecom* gene mutation associated with amegakaryocytic thrombocytopenia in a premature infant

Burak Deliloğlu[1], Özlem Tüfekçi[2], Funda Tüzün[1], Ayça Aykut[3], Emine İpek Ceylan[3], Asude Durmaz[3], Şebnem Yılmaz[2], Nuray Duman[1], Hasan Özkan[1], Hale Ören[2]

Department of Pediatrics, Divisions of [1]Neonatology and [2]Pediatric Hematology, Dokuz Eylul University Faculty of Medine, İzmir; [3]Department of Medical Genetics, Ege University Faculty of Medicine, İzmir, Turkey.

ABSTRACT

Background. Hereditary bone marrow failure syndromes are a category of biologically different syndromes that can cause cytopenia in at least one hematopoietic cell lineage.

Case. We present a 29-week-old male infant who had a low Apgar Score, advanced delivery room resuscitation, widespread petechial rash, and ecchymoses at birth, without any dysmorphic features. Initial laboratory tests revealed bicytopenia (platelet count 7x10 3 /uL, hemoglobin of 3.9 g/dL, neutrophil 2.0x10^3 /uL) with findings of disseminated intravasculer coagulation (DIC). Imaging studies demonstrated accompanying left-sided congenital pulmonary airway malformation. On the second postnatal week pancytopenia occurred and the bone marrow findings were consistent with congenital amegakaryocytic thrombocytopenia. Further evaluations for differential diagnosis of pancitopenia were performed and the results of congenital viral infections, metabolic and immunologic tests were negative. While supportive treatments were in progress, haploidentical bone marrow transplantation (BMT) was performed from the father at 84th day due to unavailability of HLA-matched relative or nonrelative donor. Whole exome sequencing revealed a novel heterozygous frameshift variation (c.1242dupT [p. Thr538fs]) in exon 8 of the MECOM gene and validated by Sanger sequencing. No variation was detected in the parents genetic analysis.

Conclusions. In this report, we present a patient with congenital bone marrow failure successfully treated with haploidentic BMT and describe a novel, de novo pathogenic variant in MECOM gene.

Key words: MECOM gene, congenital amegakaryocytic thrombocytopenia, neonate.

Inherited bone marrow failure syndromes (IBMFS) are rare disorders and usually caused by a genetic condition represented as single or multilinear cytopenia and physical malformations. Hematological and dysmorphic findings of IBMFS rarely present during neonatal period. The diagnosis of IBMFS should be kept in mind in newborns with cytopenia and / or congenital abnormalities since early diagnosis of an IBMFS is important to optimize clinical management. Congenital amegacaryocytic thrombocytopenia (CAMT) is one of the IBMFS in neonates characterized with severe thrombocytopenia and hypocellular bone marrow.[1-4] In recent years, genetic analysis has added many opportunities to diagnose IBMFS. Whole-exome sequencing (WES) gained a specific interest in terms of genetic diagnostic approach among patients with IBMFS.[5,6] Herein, we report a de novo heterozygote mutation of *MECOM* gene diagnosed by WES in a preterm neonate with CAMT.

✉ Funda Tüzün
fundatuzun@gmail.com

Received 27th October 2021, revised 23rd January 2022, accepted 26th February 2022.

Case Report

A 1471 g male neonate was born at 29 gestational weeks to a 37-year-old G2P1A1 healthy mother by cesarean section, with Apgar scores 5/5 at 1st and 5th minute. A distant consanguinity was defined between parents (3rd degree cousin marriage). The patient required resuscitation and was intubated in the delivery room. First examination in neonatal intensive care unit (NICU) revealed pallor, ecchymosis on four extremities and widespread petechial rashes on truncal part of the body. The patient developed pulmonary hemorrhage in the first hour of life.

The initial blood count showed Hb 3.9 g/dL, Htc 11.6 %, MCV 118 fL, MCH 39.7 pg, MCHC 33.6 g/dL, WBC 2200/mm^3, ANC: 2000/mm^3, ALC 100/mm^3, PLT: 7.000/mm^3, MPV: 11 fL. Peripheral smear revealed leukopenia, myeloid and erythroid precursor cells, few platelets, anisocytosis, polychromasia and several schistocytes. Corrected reticulocyte count was decreased (1.04%) and direct coombs test was negative. Coagulation tests revealed prolonged PT and PTT according to his gestational age (aPTT: 79 s [27.5-78.4], PT: 17 s [10.6-16.2], D.dimer: 10.7 mg/L [0-0.5], Fibrinogen 2.2 g/L [1.5-3.7]. The patient was diagnosed as disseminated intravascular coagulation (DIC) secondary to intrauterine hypoxia, and suspected early onset neonatal sepsis (EONS). In addition to wide spectrum antibiotics for EOS, repeated packed red blood cell (PRBC), platelet and fresh frozen plasma (FFP) transfusions were performed. On the third postnatal day results of whole blood count and coagulation tests were in normal values.

A chest radiograph for the prenatally diagnosed congenital pulmonary airway malformation (CPAM) showed left upper lobe consolidation (Fig. 1). Chest computed tomography (CT) with angiography revealed 32x28 mm large solid intrathoracic mass involving left superior lobe unrelated to bronchial system and normal thoracic aorta branching, that indicates type 3 CPAM. Partial pulmonary venous return anomaly was also detected in the CT scan. Echocardiography, cranial and abdominal ultrasonography showed no congenital anomalies.

On the 14th postnatal day, pancytopenia was detected with PLT: 5.000/mm^3, Hb :9 g/dL, and ANC: 800/mm^3 while the patient had no sign of infection and was stabilized hemodynamically. The patient was consulted with pediatric hematology department for pancytopenia. Bone marrow aspiration revealed profoundly hypocellular bone marrow with very rare myeloid and erythroid precurosrs and total absence of megacaryocytes. There was no dysplasia, malign infiltration or hemaphagocytosis. Considering radioulnar synostosis with amegakaryocytic thrombocytopenia (RUSAT), syndrome an upper extremity radiography was taken and proximal radioulnar synostosis was ruled out.

Tests for inborn error of metabolism and immune system (flow cytometric evaluation of lymphocyte subgroups immunoglobulin levels) were in the normal range. Ophthalmological examination showed pale optical disk, peripapillary hyperpigmentation. Cytogenetic evaluation of patient's peripheral blood revealed 46,XY in 5 metaphases.

From the hematological point of view, pancytopenia persisted and the patient needed recurrent platelet and erythrocyte transfusions. The patient did not respond to high dose G-CSF treatment (up to 20 mcg/kg/day), had persistent severe pancytopenia and required occasional granulocyte transfusions duw to sepsis in the follow-up.

In terms of IBMFS, next- generation sequencing analysis was performed for WES analysis and revealed a novel heterozygous frameshift variation c.1242dupT (p. Thr538fs) in exon 8 of the *MECOM* gene. The mutation is detected in the proband, but not in the parents, is confirmed by Sanger sequencing (Fig. 2). The clinical significance of the variant was examined using the standards and guidelines for the interpretation of sequence variants

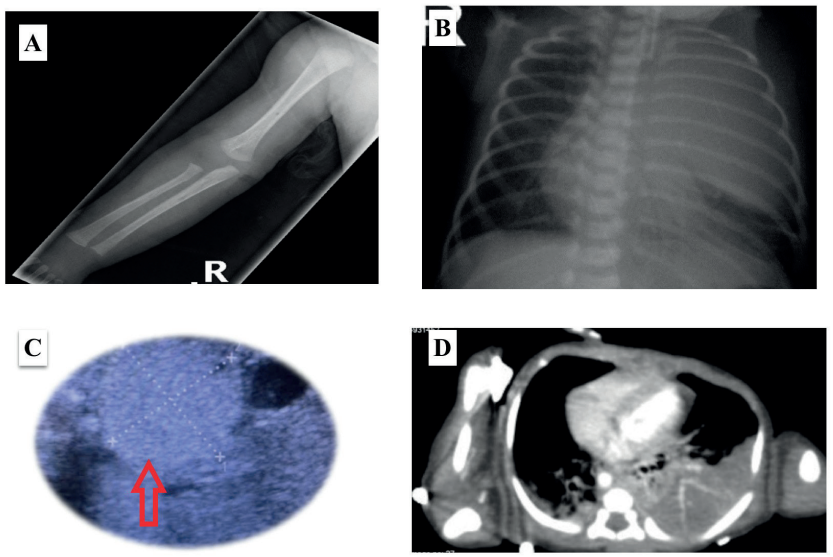

Fig. 1. A, Upper extremity graph ruling out radioulnar synostosis. B, Anterio-posterior chest graph with a suspected congenital pulmonary airway malformation. C, Ultrasound imaging of airway malformation showing hyperechogenic solid thoracic lesion with sharp border (arrow) . D, Chest CT angiography of the patient demonstrating congenital pulmonary airway malformation filling the left hemithorax, pulmonary hypoplasia and pulmonary venous return abnormality.

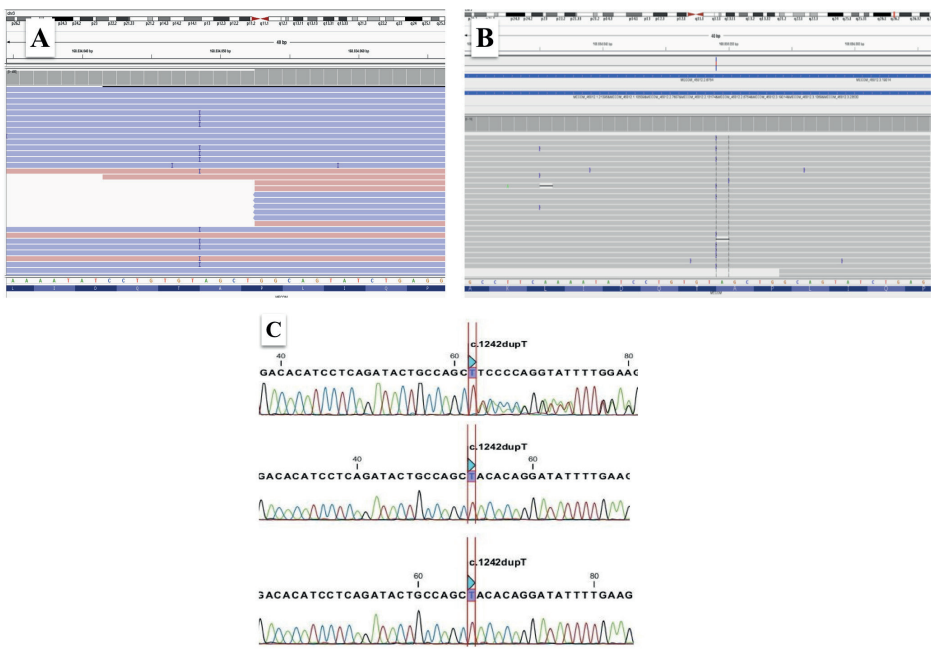

Fig. 2. A, Next generation sequencing analysis of the proband showing heterozygous c.1242dupT (p. Thr538fs) mutation in MECOM gene. B, Validation and segregation analysis of the proband and parents by Sanger sequencing revealing c.1242dupT (p. Thr538fs). C, (Line 1: Index, Line 2: Mother, Line 3: Father)

recommended by the American College of Medical Genetics and Genomics (ACMG Laboratory Quality Assurance Committee) and the Association for Molecular Pathology (AMP).[7]

Due to unavailability of HLA-matched related or unrelated donor, HLA-haploidentical hematopoietic stem cell transplantation from the father was successfully performed on the 84th day of life (postconceptional 41st gestational week). Neutrophil engrafment was achieved on day 13 and thrombocyte engrafment was achieved on day 14. No severe complication was observed in the post-transplant period. The patient experienced a grade II acute GVHD, immune suppressive treatment was tapered and discontinued on post-transplant 9th month. Full chimerism was achieved in the post-transplant first month and persisted in the follow-up.

Informed parental written consent was taken for case publication.

Discussion

In this case report, a 29-week-old premature infant diagnosed as inherited congenital bone marrow failure syndrome with *MECOM* gene mutation is presented.

True incident of IBMFS is not well known, but in a national base survey, over 40 years in Israel revealed 127 patients, only 6% of them had been diagnosed as CAMT.[8] Mucosal bleeding, petechia or ecchymosis usually present as initial symptoms of CAMT in early neonatal period secondary to thrombocytopenia.[9] In our case, the patient presented with petechial rashes and ecchymosis overall the body and pulmonary hemorrhage right after birth. Persistent pancytopenia after clinical stabilization period directed us for further investigations. Presence of decreased megakaryocytes in the bone marrow was diagnostic in addition to clinical suspect.

Skeletal and somatic abnormalities are common in IBMFS, but CAMT usually present without physical malformations in previous reported cases. In a case series of 21 CAMT patients, seven patients had mental and motor retardation, growth retardation, cardiac defects, strabismus, and nystagmus.[10] Additionally, our patient had congenital pulmonary airway malformation and partial pulmonary venous return anomaly.

Thrombopoetin (TPO) is an important regulator for hematopoietic stem cells into proliferation and survival. CAMT is mostly seen with autosomal recessive genetic mutation in the myeloproliferative leukemia virus oncogene (MPL) that encodes TPO receptor. Genetic methods particularly WES bring new insights for understanding underlying pathophysiology and accurate diagnosis. Although some patients phenotypically present as congenital amegakaryocytic thrombocytopenia, associated genetic mutations provide more detailed linkage to other IBMFS such as *DKC1* mutation in dyskeratosis congenita, *HOXA11* and *MECOM* in radioulnar synostosis with amegakaryocytic thrombocytopenia.[11-13]

MECOM gene is located on chromosome band 3q26.2 and has a crucial role in cell differentiation, growth and migration. Clinical spectrum due to *MECOM* gene mutations varies from isolated radioulnar synostosis to severe bone marrow failure. Germeshausen et al.[13] reported 12 patients with CAMT caused by *MECOM* mutations, and beside bone marrow failure additional phenotypes were observed such as clinodactyly, congenital deafness, renal abnormalities and cardiac malformations. A case report by Kjeldsen et al.[14] identified a de novo *MECOM* gene mutation in a neonate with congenital hypoplastic bone marrow and the patient has no dysmorphological findings. In our case skeletal and renal abnormalities were not identified and result of brainstem evoked response audiometry test was in normal limits.

To conclude, we present a CAMT case in a very preterm with several physical abnormalities with a novel de novo *MECOM* gene mutation, who was treated succesfully with stem cell tranplantation. Consideration of bone marrow transplantation on time due to congenital cytopenia was life-saving for our patient. In these patients, genetic diagnosis and genetic counseling of the family are quite critical due to the possibility of re-occurance of the disease in future generations.

Ethical approval

Informed parental written consent was taken for case publication.

Author contribution

The authors confirm contribution to the paper as follows: study conception and design: BD, FT, ÖT, SY, AA; data collection: BD, EIC, AD; analysis and interpretation of results: AA, ND, HÖ, HÖ; draft manuscript preparation: BD, FT, HÖ. All authors reviewed the results and approved the final version of the manuscript.

Source of funding

The authors declare the study received no funding.

Conflict of interest

The authors declare that there is no conflict of interest.

REFERENCES

1. Khincha PP, Savage SA. Neonatal manifestations of inherited bone marrow failure syndromes. Semin Fetal Neonatal Med 2016; 21: 57-65. https://doi.org/10.1016/j.siny.2015.12.003
2. Muramatsu H. Inherited bone marrow failure syndrome: management and diagnostic advances utilizing next-generation sequencing. Rinsho Ketsueki 2018; 59: 716-722. https://doi.org/10.11406/rinketsu.59.716
3. Dokal I, Vulliamy T. Inherited aplastic anaemias/bone marrow failure syndromes. Blood Rev 2008; 22: 141-153. https://doi.org/10.1016/j.blre.2007.11.003
4. Sieff CA. Introduction to acquired and inherited bone marrow failure. Hematol Oncol Clin North Am 2018; 32: 569-580. https://doi.org/10.1016/j.hoc.2018.04.008
5. Muramatsu H, Okuno Y, Yoshida K, et al. Clinical utility of next-generation sequencing for inherited bone marrow failure syndromes. Genet Med 2017; 19: 796-802. https://doi.org/10.1038/gim.2016.197
6. Yu QH, Wang SY, Wu Z. Advances in genetic studies of inherited bone marrow failure syndromes and their associated malignancies. Transl Pediatr 2014; 3: 305-309. https://doi.org/10.3978/j.issn.2224-4336.2014.07.06
7. Rivera-Garcia C, Bristow SL, Yarnall S, et al. Validation of a multiplex genotyping platform using a novel genomic database approach. Genet Med 2015: 10.1038/gim.2015.101. https://doi.org/10.1038/gim.2015.101
8. Tamary H, Nishri D, Yacobovich J, et al. Frequency and natural history of inherited bone marrow failure syndromes: the Israeli Inherited Bone Marrow Failure Registry. Haematologica 2010; 95: 1300-1307. https://doi.org/10.3324/haematol.2009.018119
9. Al-Qahtani FS. Congenital amegakaryocytic thrombocytopenia: a brief review of the literature. Clin Med Insights Pathol 2010; 3: 25-30. https://doi.org/10.4137/cpath.s4972
10. King S, Germeshausen M, Strauss G, Welte K, Ballmaier M. Congenital amegakaryocytic thrombocytopenia: a retrospective clinical analysis of 20 patients. Br J Haematol 2005; 131: 636-644. https://doi.org/10.1111/j.1365-2141.2005.05819.x
11. Wegman-Ostrosky T, Savage SA. The genomics of inherited bone marrow failure: from mechanism to the clinic. Br J Haematol 2017; 177: 526-542. https://doi.org/10.1111/bjh.14535
12. Niihori T, Ouchi-Uchiyama M, Sasahara Y, et al. Mutations in MECOM, encoding oncoprotein EVI1, cause radioulnar synostosis with amegakaryocytic thrombocytopenia. Am J Hum Genet 2015; 97: 848-854. https://doi.org/10.1016/j.ajhg.2015.10.010
13. Germeshausen M, Ancliff P, Estrada J, et al. MECOM-associated syndrome: a heterogeneous inherited bone marrow failure syndrome with amegakaryocytic thrombocytopenia. Blood Adv 2018; 2: 586-596. https://doi.org/10.1182/bloodadvances.2018016501
14. Kjeldsen E, Veigaard C, Aggerholm A, Hasle H. Congenital hypoplastic bone marrow failure associated with a de novo partial deletion of the MECOM gene at 3q26.2. Gene 2018; 656: 86-94. https://doi.org/10.1016/j.gene.2018.02.061