Pediatrics and Neonatology (2018) 59, 632–633

Available online at www.sciencedirect.com

ScienceDirect

journal homepage: http://www.pediatr-neonatol.com

Short Communication

Identification of the largest homozygous glycine decarboxylase gene deletion in a Turkish infant

Semra Gürsoy [a,*], Esra Ataman [b], Özlem Giray Bozkaya [a], Engin Köse [c], Müge Ayanoğlu [d], Ayşe İpek Polat [d], Nur Arslan [c], Semra Hız Kurul [d], Derya Erçal [a]

[a] Department of Pediatric Genetics, Dokuz Eylül University, Faculty of Medicine, İzmir, Turkey
[b] Department of Medical Genetics, Dokuz Eylül University, Faculty of Medicine, İzmir, Turkey
[c] Department of Pediatric Metabolism, Dokuz Eylül University, Faculty of Medicine, İzmir, Turkey
[d] Department of Pediatric Neurology, Dokuz Eylül University, Faculty of Medicine, İzmir, Turkey

Received Feb 19, 2017; received in revised form Jul 12, 2017; accepted Jan 12, 2018
Available online 31 January 2018

1. Introduction

Nonketotic hyperglycinemia (NKH) is an autosomal recessive inborn error of metabolism caused by a defect in the glycine cleavage complex.[1] Progressive lethargy, hypotonia, feeding difficulties, hiccups, and recurrent apnea are usually observed during the first few days of life. Subsequent severe neurologic dysfunction may occur, including intractable seizures, motor and cognitive impairments.[2] NKH is characterized biochemically by increased cerebrospinal fluid (CSF) and plasma glycine levels and an increased CSF-to-plasma glycine ratio.[3] Enzymatic analysis of the glycine cleavage system (GCS) in liver tissues obtained by invasive biopsy or the mutational analysis of three responsible genes, such as GLDC, AMT, and GCSH, is required to confirm the exact diagnosis. We report a case of newborn with classic NKH who had a large homozygous GLDC gene deletion.

2. Case

A female neonate was born to consanguineous parents at 39 weeks of gestation. On the first day of birth, the neonate suffered from remarkable dyspnea and had generalized hypotonia, for which she was intubated and transferred to intensive care unit. Her parents had a history of death of previous offspring at the age of 11 months who also had severe muscular hypotonia (Fig. 1). In our patient, routine laboratory test results were unremarkable.

Echocardiography (ECG) revealed a muscular ventricular septal defect and a small secundum-type atrial septal defect. Cranial magnetic resonance imaging showed decreased cerebral white matter, slightly increased signal intensity, and a mass within the retrocerebellar region compatible with an arachnoid cyst.

Glycine levels were simultaneously measured in CSF and blood samples, showing an increased CSF/plasma glycine ratio (0.19; reference value <0.08). The diagnosis of NKH was confirmed by the direct sequencing of all exons and exon–intron boundaries of the GLDC gene, and exons 1–21 were not amplified using PCR. Thereafter, multiplex ligation-dependent probe amplification (MLPA) analysis was

* Corresponding author. Department of Pediatric Genetics, Dokuz Eylül University Hospital, Faculty of Medicine Mithatpaşa cad. No 1606 inciraltı yerleşkesi 35340 Balçova / İzmir Turkey. Fax: +90 232 412 97 97.
E-mail address: dr.semra@hotmail.com (S. Gürsoy).

https://doi.org/10.1016/j.pedneo.2018.01.011
1875-9572/Copyright © 2018, Taiwan Pediatric Association. Published by Elsevier Taiwan LLC. This is an open access article under the CC BY-NC-ND license (http://creativecommons.org/licenses/by-nc-nd/4.0/).

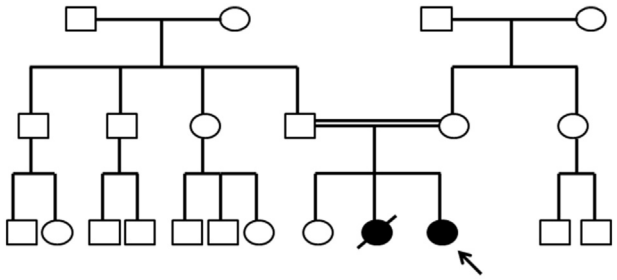

Figure 1 The pedigree of the patient's family.

performed and detected a large homozygous deletion for exons 1—21 in the GLDC gene (Fig. S1).

The patient started treatment with sodium benzoate upon the diagnosis of NKH. During her follow-up, she suffered a convulsion at the 2nd month of age; electroencephalogram showed spikes and sharp wave discharges. Therefore, phenobarbital was added to the therapy, which reduced the seizures. Carrier testing of her parents and sister showed that they are all heterozygous carriers for this large deletion.

3. Discussion

GCS is a multienzyme complex of four components: P-protein (a pyridoxal phosphate-dependent glycine decarboxylase), H-protein (a lipoic acid-containing protein), T-protein (a tetrahydrofolate-requiring enzyme), and L-protein (a lipoamide dehydrogenase). These proteins are, respectively, encoded by the GLDC, GCSH, AMT, and GCSL genes.[4] NKH may occur as a result of a defect in any one of these enzymes, and GLDC gene mutations are observed in 70%—75% of the patients with NKH.[1,2]

For the GLDC gene, missense mutations are the most common mutations seen in the variants (90%) and others are small-scale insertions/deletions, large-scale deletions, and mutations that affect splicing.[4] Kanno et al. reported GLDC deletions in 21 of 65 patients with neonatal onset NKH (32.3%), and in 25 of 130 NKH alleles (19.2%) by MLPA analysis.[5] They stated that deletions within the GLDC gene are the most common causes of NKH.[5] Suzuki et al. reported a newborn with the classic neonatal form of NKH. The patient was revealed to be a heterozygote for the deletion of all 25 GLDC exons, and a missense mutation (p.R461Q) was also revealed by sequencing the other allele.[1] In our case, molecular studies demonstrated a large homozygous deletion for exons 1—21 in the GLDC gene. Unfortunately, because most reported mutations seem to be rare or private, it is very difficult to predict the phenotype by considering the genotype.

Consequently, NKH is a very rare autosomal recessive metabolic condition and should be considered in patients with severe neurologic and respiratory signs during their first few days of life. An early diagnosis does not change the disease course due to the absence of an effective treatment, but it allows for proper genetic counseling, with the possibility of prenatal diagnosis in future pregnancies. Furthermore, a definite diagnosis with this phenotype prevents further unnecessary investigations for other genetic or metabolic etiologies. We report a large deletion in the GLDC gene in a consanguineous Turkish couple and to our knowledge, this report is the first to describe the large homozygous deletion for exons 1—21. In addition, this case aims to enhance the knowledge on genotype—phenotype correlation in NKH syndrome. But further studies are needed to determine the effect of the deletions on the phenotype and protein function.

Conflict of interest

None.

Informed Consent

All procedures followed were in accordance with the ethical standards of the responsible committee on human experimentation (UBC CREB, Canada) and with the Helsinki Declaration of 1975, as revised in 2000.

References

1. Suzuki Y, Kure S, Oota M, Hino H, Fukuda M. Nonketotic hyperglycinemia: proposal of a diagnostic and treatment strategy. *Pediatr Neurol* 2010;**43**:221—4.
2. Brunel-Guitton C, Casey B, Coulter-Mackie M, Vallance H, Hewes D, Stockler-Ipsiroglu S, et al. Late-onset nonketotic hyperglycinemia caused by a novel homozygous missense mutation in the GLDC gene. *Mol Genet Metab* 2011;**103**:193—6.
3. Tada K, Kure S. Non-ketotic hyperglycinaemia: molecular lesion, diagnosis and pathophysiology. *J Inherit Metab Dis* 1993;**16**:691—703.
4. Love JM, Prosser D, Love DR, Chintakindi KP, Dalal AB, Aggarwal S. A novel glycine decarboxylase gene mutation in an Indian family with nonketotic hyperglycinemia. *J Child Neurol* 2014;**29**:122—7.
5. Kanno J, Hutchin T, Kamada F, Narisawa A, Aoki Y, Matsubara Y, et al. Genomic deletion within GLDC is a major cause of non-ketotic hyperglycinaemia. *J Med Genet* 2007;**44**:e69.

Appendix A. Supplementary data

Supplementary data related to this article can be found at https://doi.org/10.1016/j.pedneo.2018.01.011.