doi:10.1093/brain/awx197 BRAIN 2017: 140; 1–4 | e61

BRAIN
A JOURNAL OF NEUROLOGY

LETTER TO THE EDITOR

PRUNE1: a disease-causing gene for secondary microcephaly

Mert Karakaya,[1] Sanem Yilmaz,[2] Markus Storbeck,[1] Irmgard Hoelker,[1] Raoul Heller,[1] Gül Serdaroglu,[2] Sarenur Gökben,[2] Uluc Yis[3] and Brunhilde Wirth[1]

1 Institute of Human Genetics, Center for Molecular Medicine Cologne, and Institute of Genetics, University of Cologne, Cologne, Germany
2 Ege University, Department of Pediatric Neurology, Izmir, Turkey
3 Dokuz Eylül University, Department of Pediatric Neurology, Izmir, Turkey

Correspondence to: Professor Dr Brunhilde Wirth
Institute of Human Genetics
University of Cologne
Kerpener Str. 34
50931 Cologne, Germany
E-mail: brunhilde.wirth@uk-koeln.de

Sir,

We read with great interest, the article by Zollo *et al.* (2017) presenting the first cases with functional molecular analysis of *PRUNE1*-related microcephaly with neurodevelopmental impairment. *PRUNE1* was first described by Karaca *et al.* (2015) as a candidate disease-causing gene for neurodevelopmental impairment with microcephaly. Mutations in *PRUNE1* were identified in families of various ethnic backgrounds with autosomal recessive neurodevelopmental and neurodegenerative disorder that includes primary microcephaly and profound global developmental delay (Karaca *et al.*, 2015; Zollo *et al.*, 2017).

We report an additional affected individual with congenital hypotonia, secondary microcephaly, global developmental delay and respiratory insufficiency from a healthy consanguineous Turkish family. Hereby, we confirm the pathogenicity of recessive *PRUNE1* mutations, but also underline the type of microcephaly that has developed after birth, progressed in 2 years and presented as a secondary microcephaly. Informed consent for next-generation sequencing and photos of the affected individual were obtained from the parents and the affected individual under NeurOmics consortium regulations.

The 3-year-old male was followed since birth because of neonatal generalized hypotonia, knee contractures and hip dislocation. He was born uneventfully via caesarean section due to breech presentation. His birth weight was 3750 g (75th percentile), height was 50 cm (50th percentile) and head circumference was 36 cm (75th percentile). He was able to smile and make eye contact at 2 months of age, but these abilities were gradually lost. After frequent admissions to the intensive care unit due to pneumonia, he developed respiratory insufficiency at 8 months of age, and has been mechanically ventilated since then (Fig. 1A–E). First focal motor seizures started at 2 months of age and flexor spasms occurred shortly thereafter. Cranial MRI scans at 14 months of age revealed cerebral and cerebellar atrophy with delayed myelination and inferior vermis hypoplasia (Fig. 1G–I). Electromyography findings were compatible with neurogenic involvement. At 38 months of age, he was unable to hold his head, had general muscle weakness and hypotonia along with spasticity and clonus at lower extremities, secondary microcephaly with a head circumference of 48.0 cm (−2 standard deviations) (Fig. 1F), brachycephaly, large ears, optic atrophy, severe kyphoscoliosis and flexion contractures. He required permanent mechanical ventilation through tracheostomy and feeding via nasogastric tube (Fig. 1).

Trio-whole genome sequencing (trio-WGS) was performed, which revealed a homozygous frameshift variant, c.874_875insA (p.H292Qfs*3), in *PRUNE1* (prune exopolyphosphatase 1, NM_021222.2) as the primary candidate mutation (Fig. 1J–K). The consanguinity of the parents and the parental status were confirmed by allele sharing

Advance Access publication August 23, 2017
© The Author (2017). Published by Oxford University Press on behalf of the Guarantors of Brain. All rights reserved.
For Permissions, please email: journals.permissions@oup.com

Downloaded from https://academic.oup.com/brain/article/140/10/e61/4092877 by Dokuz Eylul University Library (DEU) user on 02 September 2021

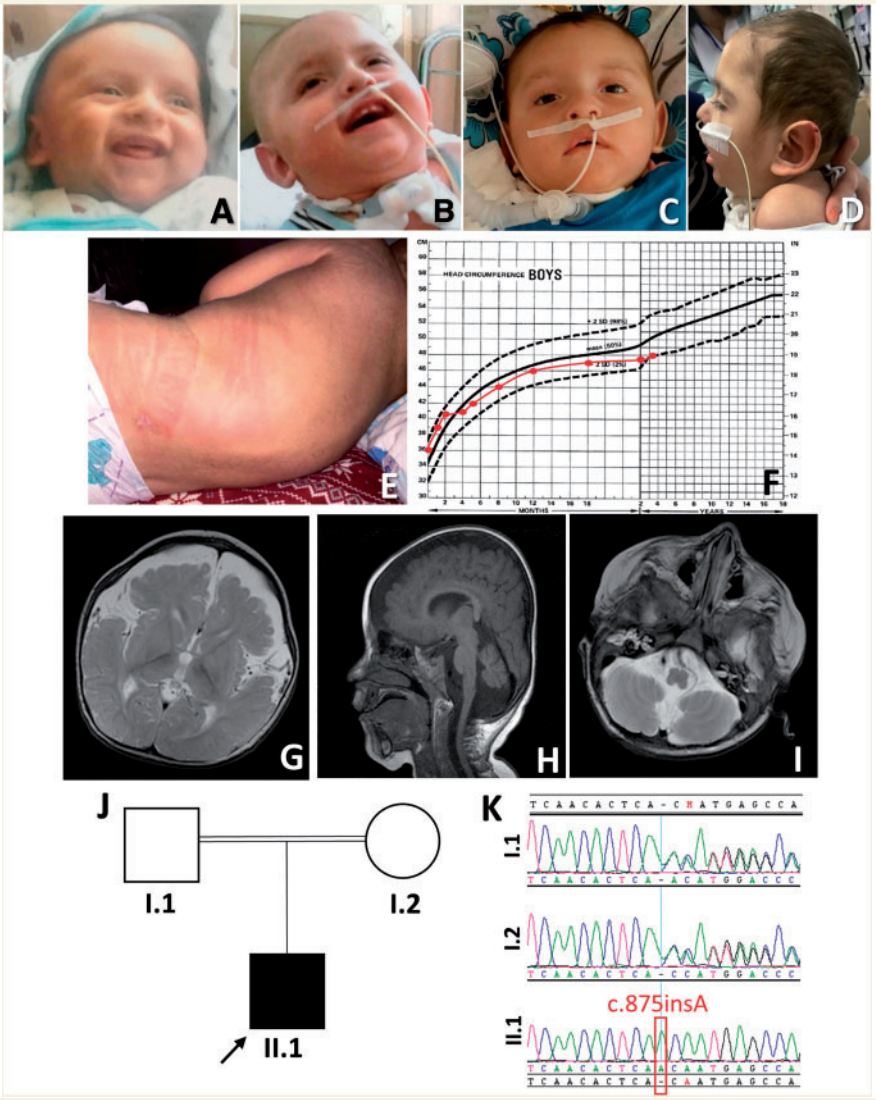

Figure 1 Phenotypic features, neurodegenerative course and disease progress at different periods. (**A**) Apparent smiling at 2 months, (**B**) incomplete head control and beginning of respiratory insufficiency at 4 months, (**C**) complete respiratory failure, mechanical ventilation and the onset of cognitive decline at 8 months. (**D**) Severe cognitive decline, loss of eye contact due to optic atrophy, large prominent ears, brachycephaly and severe hypotonia at 38 months. (**E**) Severe kyphoscoliosis at 32 months. (**F**) Head circumference curve confirms secondary microcephaly. Head circumference at birth 75th percentile, head circumference at 38 months −2 standard deviations. (**G**) On MRI images at 14 months of age, cortical atrophy at frontotemporal region and increased intensity in white matter due to delayed myelination on T_2-axial section. (**H**) Global CNS atrophy and brachycephaly on T_1-sagittal section and (**I**) inferior vermis hypoplasia on T_1-axial section. (**J**) Pedigree of the family. (**K**) Sanger confirmation and segregation analysis of c.875insA variant in the *PRUNE1* gene (NM_0121222). Carrier heterozygosity in the parents (I.1 and I.2) and homozygosity in the affected individual (II.1) were confirmed.

analysis, in which the child and each parent shared >50%, whereas the parents shared 25% of their alleles. The *PRUNE1* variant was not present in online genomic databases (1000 Genomes, NHLBI ESP database, Exome Aggregation Consortium-ExAC and Greater Middle East Variome Project Database). *In silico* CADD analysis revealed a high-deleterious score (Phred score: 26.8). The H292Qfs*3 mutation causes a loss-of-function effect in the stringently conserved DHHA2 motif, in which the homozygous missense variant c.889 C > T (p.Arg297Trp) was confirmed to be pathogenic by Zollo *et al.* (2017).

PRUNE1 is highly expressed in early embryonic and foetal stages, and is suggested to have a prospective role in the developing human brain (Karaca *et al.*, 2015). The gene is located in the chromosomal region 1q21.3 and encodes the PRUNE protein, a phosphodiesterase member of the DHH (aspartic acid-histidine-histidine) phosphodiesterase superfamily (Reymond *et al.*, 1999). PRUNE has been shown to contribute to red eye pigment formation in *Drosophila* (Timmons *et al.*, 1995), and to facilitate cellular motility and metastasis (D'Angelo *et al.*, 2004). The interaction of PRUNE with glycogen synthase kinase-3

Downloaded from https://academic.oup.com/brain/article/140/10/e61/4092877 by Dokuz Eylul University Library (DEU) user on 02 September 2021

(GSK-3B), a suppressor of neurite outgrowth, synapse formation and neurogenesis, suggests a possible molecular role in brain development (Eom *et al.*, 2007).

Zollo's recent study confirms that *PRUNE1* mutations in separate domains of the protein (DHH and DHHA2) impair cell differentiation, proliferation and migration properties in neuronal SH-SY5Y cells (Zollo *et al.*, 2017). Furthermore, the interaction between PRUNE and beta-tubulin has been identified by mass spectrometry-based interaction screen, which depicted an impairment of microtubule polymerization activity (Zollo *et al.*, 2017). These data provide a correlation and show a clinical overlap between beta-tubulin *(TUBB)*-related brain malformations (OMIM 615771) and *PRUNE1*-related microcephaly with neurodevelopmental impairment. According to a 3D model of PRUNE, the Arg297 amino acid residue is in close proximity to the predicted enzymatic pocket, and the p.Arg297Trp mutation may enhance DHH1-DHH2 domain interaction, which likely interferes with functionality of the protein (Zollo *et al.*, 2017). The single base-pair insertion in our affected individual causes a frameshift at His292 and truncates the protein 3 amino acid residues upstream, which very likely hampers the translation of a functional DHH2 domain.

Recently, a variant destroying a canonical splice acceptor site in intron 4 of *PRUNE1* (c.521-2A > G, IVS4-2A > G, NM.021222.1) has been reported in a single case from an Ojibwe-Cree family with global developmental delay, cortical blindness, infantile spasms and central hypoventilation (Costain *et al.*, 2017). Despite the lacking functional validation, this splice variant locates in the catalytic DHH domain, and it has been proposed to be a founder mutation specific to the Cree and Ojibwe tribes (Costain *et al.*, 2017).

From WGS data, we identified another biallelic truncating variant (c.1486 G > A, p.Q496*) in *CCDC14* (coiled-coil domain containing 14 gene; NM_022757) in Individual II.1. The *CCDC14* variant was reported heterozygous in ExAC database. *In silico* CADD analysis revealed a very high-deleterious score (Phred score: 37). The protein has a medium expression level at cerebral cortex as well as many other tissues (Human Protein Atlas). Despite the severity of the variant and the interaction with other proteins known to have a role in neurogenesis (CEP63 and UCHL1, GeneCards), the causality of this variant to remain elusive due to the scarce functional data of the protein.

In the previous reports, the type of microcephaly in the individuals with *PRUNE1* mutations were either not specified or mentioned as primary microcephaly (Karaca *et al.*, 2015; Costain *et al.*, 2017; Zollo *et al.*, 2017). However, no exact data were provided about head circumference at birth. The individual presented here, clearly has a secondary microcephaly with normal head circumference at birth, after which he developed a secondary microcephaly as shown by the growth curve of the head circumference (Fig. 1F).

In summary, we report an additional case with a similar phenotype to an emerging neurodevelopmental and neurodegenerative disease owing to biallelic *PRUNE1* variants (Zollo *et al.*, 2017). The mutation in the described family expands the molecular features of *PRUNE1*-related microcephaly with neurodevelopmental impairment. This letter also aims to underline the microcephaly type as secondary in biallelic mutations of *PRUNE1*. A *PRUNE1*-associated disorder should be considered in the diagnostic work-up of unsolved cases of microcephaly with neurodevelopmental impairment. It will require further molecular studies to understand completely PRUNE's role in normal cortical development and brain growth.

Web resources

The URLs for data presented herein are as follows:
NHLBI Exome Sequencing Project (ESP); http://evs.gs.washington.edu/EVS/
Online Mendelian Inheritance in Man; http://www.ncbi.nlm.nih.gov/Omim
PubMed; http://www.ncbi.nlm.nih.gov/pubmed/
GeneCards; http://www.genecards.org/
The 1000 Genomes Browser; http://browser.1000genomes.org/index.html
The Greater Middle East Variome Project; http://igm.ucsd.edu/gme/index.php
Exome Aggregation Consortium; http://exac.broadinstitute.org/
The National Center for Biotechnology; http://www.ncbi.nlm.nih.gov/
UCSC Human Genome Database; http://www.genome.ucsc.edu
Combined Annotation Dependent Depletion (CADD); http://cadd.gs.washington.edu/
Human Protein Atlas: http://www.proteinatlas.org/
NeurOmics: http://rd-neuromics.eu/

Acknowledgements

We would like to thank to the family members described here in for participating in this study.

Funding

The research leading to these results has received funding from the European Community's Seventh Framework Programme (FP7/2007-2013) under grant agreement n° 2012-305121 'Integrated European –omics research project for diagnosis and therapy in rare neuromuscular and neurodegenerative diseases (NEUROMICS)'.

References

Costain G, Shugar A, Krishnan P, Mahmutoglu S, Laughlin S, Kannu P. Homozygous mutation in PRUNE1 in an Oji-Cree male with a

Downloaded from https://academic.oup.com/brain/article/140/10/e61/4092877 by Dokuz Eylul University Library (DEU) user on 02 September 2021

complex neurological phenotype. Am J Med Genet A 2017; 173: 740–3.

D'Angelo A, Garzia L, Andre A, Carotenuto P, Aglio V, Guardiola O, et al. Prune cAMP phosphodiesterase binds nm23-H1 and promotes cancer metastasis. Cancer Cell 2004; 5: 137–49.

Eom TY, Roth KA, Jope RS. Neural precursor cells are protected from apoptosis induced by trophic factor withdrawal or genotoxic stress by inhibitors of glycogen synthase kinase 3. J Biol Chem 2007; 282: 22856–64.

Karaca E, Harel T, Pehlivan D, Jhangiani SN, Gambin T, Coban Akdemir Z, et al. Genes that affect brain structure and function identified by rare variant analyses of Mendelian neurologic disease. Neuron 2015; 88: 499–513.

Reymond A, Volorio S, Merla G, Al-Maghtheh M, Zuffardi O, Bulfone A, et al. Evidence for interaction between human PRUNE and nm23-H1 NDPKinase. Oncogene 1999; 18: 7244–52.

Timmons L, Xu J, Hersperger G, Deng XF, Shearn A. Point mutations in awdKpn which revert the prune/Killer of prune lethal interaction affect conserved residues that are involved in nucleoside diphosphate kinase substrate binding and catalysis. J Biol Chem 1995; 270: 23021–30.

Zollo M, Ahmed M, Ferrucci V, Salpietro V, Asadzadeh F, Carotenuto M, et al. PRUNE is crucial for normal brain development and mutated in microcephaly with neurodevelopmental impairment. Brain 2017; 140: 940–52.

Downloaded from https://academic.oup.com/brain/article/140/10/e61/4092877 by Dokuz Eylul University Library (DEU) user on 02 September 2021