Emergency Radiology (2022) 29:99–105
https://doi.org/10.1007/s10140-021-01990-7

ORIGINAL ARTICLE

Accuracy of specific free air distributions in predicting the localization of gastrointestinal perforations

Hakki Celik[1] · Mehmet Akif Kamar[1] · Canan Altay[1] · Isil Basara Akin[1] · Mustafa Secil[1]

Received: 29 July 2021 / Accepted: 1 October 2021 / Published online: 11 October 2021
© American Society of Emergency Radiology 2021

Abstract

Purpose To evaluate the role of specific distributions of free air in predicting the location of gastrointestinal (GI) tract perforation.

Materials and methods One hundred and fifteen patients with surgically proven GI tract perforation between January 2015 and June 2019 were included in the study. The site of perforation was based on surgical findings in all cases. Two radiologists retrospectively interpreted the computed tomography (CT) images of these patients for extraluminal free air distribution. Perforation sites were demonstrated intraoperatively in all cases and were categorized as follows: stomach and duodenum, jejunum and ileum, proximal colon (cecum, ascending colon, and transverse colon), distal colon (descending colon and sigmoid colon), rectum, and appendix.

Results There were 79 male and 36 female patients with a mean age of 56.4 years. Periportal, perihepatic, and perigastric free air were statistically significant in predicting gastroduodenal perforation. Mesenteric free air was significant in predicting both small bowel and distal colon perforations. Pelvic free air was statistically significant in distal colon perforations. Periappendiceal free air was found to be a strong predictor of acute perforated appendicitis.

Conclusion Specific free air distributions may help to predict the site of gastrointestinal perforation, which would change the treatment plan.

Keywords Gastrointestinal perforation · Extraluminal air · CT

Introduction

Gastrointestinal (GI) tract perforation, an emergency that usually requires urgent surgery, may be attributed to a variety of causes. The anatomic site of perforation significantly affects the type and burden of enteric contamination [1]. Microbiological colonization increases from proximal to distal, with the stomach showing the lowest number of viable microorganisms per cubic centimeter of luminal contents [1]. Therefore, peritonitis is usually more severe in perforations in the distal portions of the GI tract. Mortality of secondary peritonitis was as high as 90% in the early twentieth century and is still 30 to 50% despite advances in antibiotics, surgical technique, radiographic imaging, and resuscitation therapy [2]. Rapid diagnosis and treatment of GI tract perforation is essential to reduce the high morbidity and mortality of late-stage peritonitis [3]. Endoscopic and laparoscopic surgeries are increasingly being performed instead of laparotomy [4, 5]. Besides, GI perforations can be treated nonoperatively if there are no signs or symptoms of generalized peritonitis and the perforation site has sealed spontaneously [6]. Because of these various treatment options, the location and cause of GI perforation are the main questions that need to be answered by performing imaging studies.

Computed tomography (CT) is the most valuable imaging technique for identifying the presence, site, and cause of GI perforation [7–13]. CT findings of the GI tract may

✉ Hakki Celik
hakkicelikmd@gmail.com

Mehmet Akif Kamar
m.akif.kamar@gmail.com

Canan Altay
drcananaltay@gmail.com

Isil Basara Akin
isilbasara@gmail.com

Mustafa Secil
msecil@ttmail.com

[1] Department of Radiology, Dokuz Eylul University Hospital, 35340 Izmir, Turkey

vary according to the perforation site and include various findings such as extraluminal free air, focal defect in the bowel wall, segmental bowel wall thickening, perivisceral fat stranding, localized fluid collection, ascites, and abscess formation. Many studies have been reported evaluating the CT findings of GI perforation, and extraluminal free air is the most important and critical imaging finding in diagnosing GI perforation [5, 7, 9, 11–14]. CT is highly sensitive for detecting free air and is the imaging technique of choice for diagnosing pneumoperitoneum [15].

After the detection of extraluminal free air on CT, predicting the possible localization of the GI tract perforation is extremely critical in determining the management of the patient. Accurate prediction of the site of perforation and its cause can change the treatment. In cases such as peptic ulcer perforation and diverticular perforation, conservative treatment may be considered if the patient is systemically well [16, 17]. Non-operative management was shown to be effective and safe in selected patients with perforated peptic ulcer [18]. Patients with isolated pericolic extraluminal air secondary to diverticulitis can be treated conservatively without surgery [17]. Therefore, treatment may be conservative depending on the etiology and location of the perforation. We conducted this study to evaluate the diagnostic performance of specific free air distributions on CT for preoperatively detecting the perforation site in patients with GI tract perforations.

Materials and methods

Study population

The institutional review board approved this retrospective study and waived the requirement for informed consent. One radiologist with 10 years of abdominal radiology experience reviewed the medical records of patients with acute abdominal pain who visited the emergency department and underwent abdominal CT between January 2015 and June 2020. Extraluminal free air was detected on CT in 178 of approximately fifteen thousand patients. Fifty-four patients without an operative report in our hospital and nine cases with postoperative suture failure were excluded. The remaining 115 patients who were surgically confirmed to have GI tract perforation within 48 h of CT examination were included in this study.

CT technique

Computerized tomography was performed by using a 64-slice CT scanner (Philips Brilliance 64; Philips Medical Systems, Best, The Netherlands). In our standard contrast CT imaging protocol, patients receive intravenous iopromide (100 ml; 300 mg iodine/ml) and 100 ml of lactulose solution as oral contrast agent. Intravenous contrast agent was given in patients without known renal failure. Abdominal CT scanning parameters were as follows: KV, 120 kVp; milliampere, 220 mA; slice thickness, 2 mm; FOV, 500 mm. All CT images are sent and stored in a digital archive.

Image analysis

Two radiologists, each with at least 4 years of abdominal radiology experience, evaluated the CT images together. In case of disagreement, a radiologist with 10 years of abdominal radiology experience made the final decision. CT data were reviewed on a PACS system (Sectra AB, Linköping, Sweden). Multiplanar reconstructions were also evaluated in addition to the axial images to improve the accuracy of free air location in all patients. The reviewers had no access to the patients' clinical history, surgical notes, and pathological diagnosis. The reviewers assessed the presence of specific free air distributions (perihepatic, periportal, perigastric, paraduodenal, perisplenic, mesenteric, omental, pelvic, and periappendiceal) on the CT images retrospectively using a wide-window setting that distinguishes air from fat densities to enhance the sensitivity for detecting extraluminal air (Figs. 1, 2, 3, 4, 5, and 6). Detailed descriptions of specific free air distributions can be found in the Supplementary Table. Perforation sites were demonstrated intraoperatively in all cases and were categorized as follows: stomach and duodenum, jejunum and ileum, proximal colon (cecum, ascending colon, and transverse colon), distal colon (descending colon and sigmoid colon), rectum, and appendix. Rectosigmoid junction, an anatomical region where perforation is common, was included in the distal colon. The sites of perforation determined at surgery and causes of perforations are summarized in Table 1.

Statistical analysis

All statistical analyses were performed using SPSS version 24 (SPSS, Chicago, IL, USA). A p-value < 0.05 was considered statistically significant. The relationship between the perforation sites determined at the surgery and the free air distribution shown on CT images was examined. The accuracy, sensitivity, specificity, positive predictive value (PPV), and negative predictive value (NPV) of the free air distributions in predicting the perforation sites were calculated.

Results

Seventy-nine of the patients were male (69%), and thirty-six (31%) were female. The age range was 18–90 years; the average age was 56.4 years. Surgery revealed gastric or

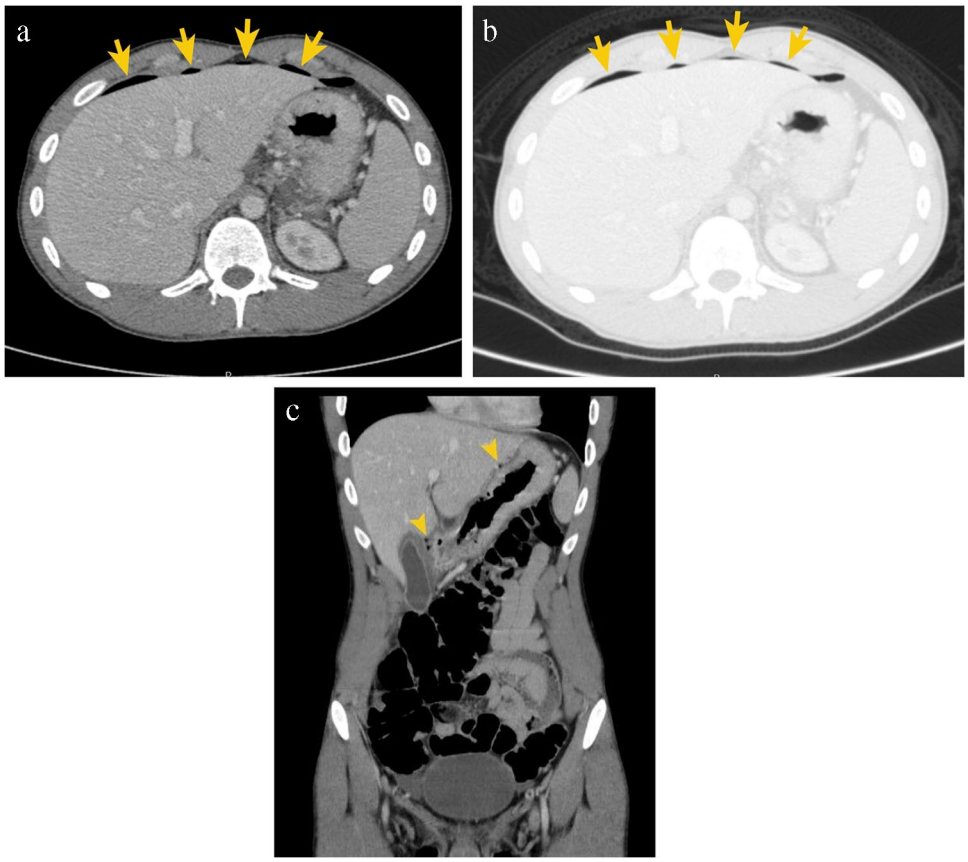

Fig. 1 Contrast-enhanced abdominal CT of a patient admitted to the emergency service with a sudden onset of pain in the upper abdomen. **a** Axial plane CT image in soft tissue window-level setting shows extraluminal free air in show the perihepatic space (arrows). **b** Axial plane CT image at the same level in a wider window shows perihepatic free air more prominently (arrows). **c** Coronal plane CT image demonstrates extraluminal free air bubbles in the perigastric area (arrowheads). A 12-mm duodenal wall defect was noted at the surgery

duodenal perforation in fifty-seven (49.5%) patients, small bowel perforation in nineteen (16.5%) patients, acute perforated appendicitis in 9 (7.8%) patients, proximal colon perforation in eight (7%) patients, distal colon perforation in twenty (17.4%) patients, and rectum perforation in 2 (1.8%) patients. The most common causes of perforations were ulcer (75%) in gastroduodenal perforations, trauma (26%) in small bowel perforations, and diverticulitis (25%) in distal colon perforations. Ischemia, cancer, and inflammation were the other common causes of perforations in the rest of the GI tract. In trauma-related perforations, trauma was blunt in 30% and penetrating in 70% of the patients. The distribution of patients according to the specific free air locations can be listed as follows: in the perihepatic area of 88 patients, periportal area of 51 patients, perigastric area of 82 patients, mesentery of 60 patients, pelvis of 33 patients, periappendiceal area of 16 patients, paraduodenal area of 41 patients, perisplenic area of 46 patients, and omentum of 80 patients.

Among the specific free air distributions, periportal, perihepatic, and perigastric free air were statistically significant in predicting gastroduodenal perforation (p: 0.009, 0.001, and 0.001, respectively). Mesenteric free air was found to be significant in both small bowel and distal colon perforations (p, 0.005 and 0.002, respectively). Free air in the pelvic area was significantly common in distal colon perforations (0.000). Periappendiceal free air was statistically significant in patients with acute perforated appendicitis (0.000). For predicting gastroduodenal perforations, the sensitivity vs. specificity values of perihepatic, periportal, and perigastric areas were 86.4% vs. 40.3%, 54.2% vs. 69.3%, and 84.7% vs. 48.4%, respectively. Mesenteric free air showed 78.9% sensitivity and 55.9% specificity in small bowel perforations, whereas it showed 81% sensitivity and 57% specificity in distal colon perforations. The sensitivity of pelvic free air in distal colon perforations was 76.2% and the specificity was 83%. In appendicular perforations, periappendicular free air revealed 72.7% sensitivity and 92.7% specificity. Diagnostic values of the significant relationships between free air distributions and perforation sites are summarized in Table 2.

Discussion

Extraluminal free air is the most common and consistent finding of gastroduodenal perforation, although it may be absent, especially at the onset of symptoms [19]. Previous studies have reported that specific free air distribution is a useful CT finding for the diagnosis of GI tract perforation [5, 20–23]. The accuracy of CT for predicting the site of bowel perforation has been reported to range between 82



Fig. 2 Contrast-enhanced abdominal CT image of a 36-year-old man admitted to the emergency department after a high-energy blunt trauma. Coronal plane CT image shows free air in the mesentery of the jejunum (arrowheads), heterogenity (arrow), and perihepatic free fluid (short arrow). Jejunal perforation was diagnosed intraoperatively

and 90% in previous studies [5, 12, 24]. In this study, the distribution of extraluminal free air within the abdominal cavity was evaluated to estimate the location of the GI tract perforation.

In the present study, free air in the periportal, perihepatic, and perigastric areas were found to be significant in gastroduodenal perforations. Periportal free air had the highest specificity for gastroduodenal perforations. Similar to the present study, Cho et al. reported that when there is free air in the periportal area, it suggests a high probability of perforation in the upper GI tract [22]. Another study reported that subphrenic and periportal free air were statistically significant in the upper GI tract perforations [14]. Because of the anatomical proximity, even a small amount of free air is easily distributed around the hepatic hilum, and therefore, periportal free air is more common in upper GI tract perforations.

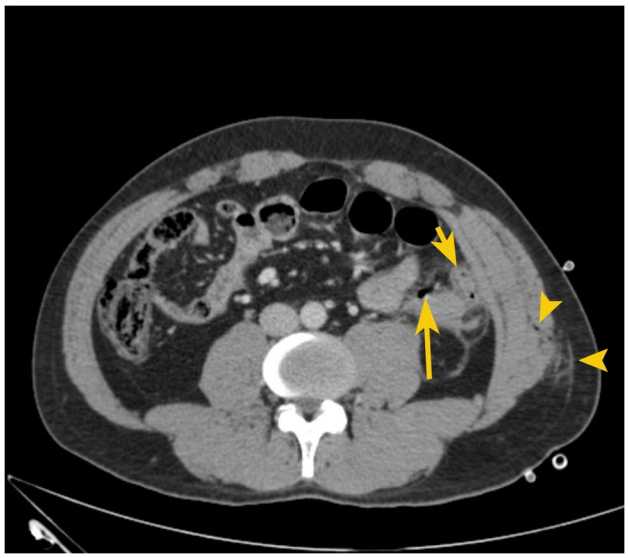

Fig. 3 Contrast-enhanced abdominal CT of a 30-year-old man admitted to the emergency department after a penetrating trauma. Subcutaneous linear densities and air bubbles (arrowheads) are seen at the level of injury on the lateral abdominal wall. Axial CT image demonstrated increased wall thickness in the descending colon (short arrow) and mesenteric free air (arrow) in close proximity. Perforation of the descending colon was confirmed at laparotomy

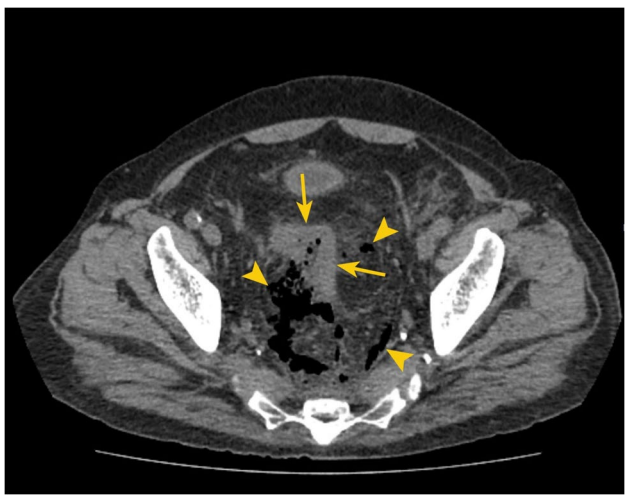

Fig. 4 Non-contrast CT of the abdomen and pelvis of a 75-year-old man who presented to the emergency department with sudden onset of abdominal pain and deterioration. Axial CT image shows increased wall thickness at the rectosigmoid junction (arrows) and pelvic free air (arrowheads). Surgery confirmed perforation at the rectosigmoid junction secondary to diverticulitis

Mesenteric free air was found to be a significant predictor in small bowel perforations. Hainaux et al. reported that concentrated free air bubbles close to the bowel wall might help determine the site of perforation because free air bubbles tend to be in the vicinity of the bowel wall as they arise,

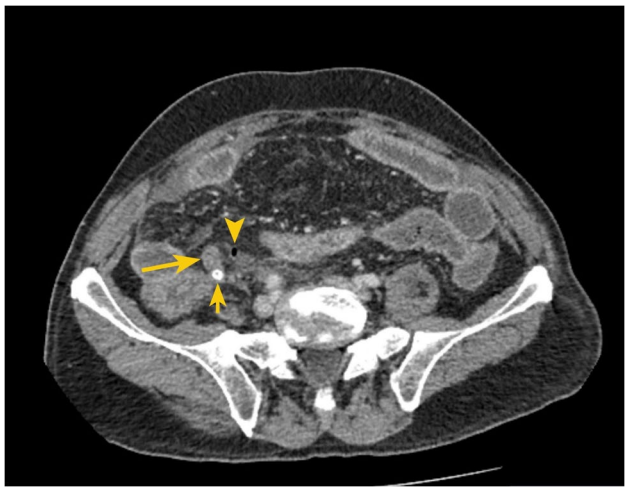

Fig. 5 Contrast-enhanced abdominal CT of a 70-year-old man admitted to the emergency department with right lower quadrant pain. Axial CT image shows increased diameter of the appendix (arrow), an appendicolith (short arrow) at the root of the appendix, and a small amount of free air (arrowhead) in the periappendicular area. Inflammation and perforation of the vermiform appendix was confirmed after surgery



Fig. 6 Non-contrast CT of the abdomen and pelvis of a 77-year-old man who presented to the emergency department with sudden onset of pain generalized throughout the abdomen. Axial CT image shows wall thickening of the ascending colon (arrow) and a large amount of extraluminal free air in the omentum (arrowheads)

especially when the amount of air is small [5]. In the present study, mesenteric free air was also found to be significant in distal colon perforations. Rectosigmoid colon is characterized by inadequate blood supply and high pressure due to less caliber, which is the rationale behind its frequent detection as a perforation site [25]. In the current study, 16 out of 20 patients with distal colon perforation had perforation at the rectosigmoid colon. In rectosigmoid perforation, free air is often detected in the sigmoid mesocolon, which is the

Table 1 Locations and causes of gastrointestinal tract perforations

Stomach-duodenum ($n=57$)	n	Small bowel ($n=19$)	n	Proximal colon ($n=8$)	n	Distal colon ($n=20$)	n	Rectum ($n=2$)	n	Appendix ($n=9$)	n
Ulcer	43	Trauma (penetrating)	3	Cancer	3	Diverticulitis	5	Cancer	1	Appendicitis	9
Cancer	5	Trauma (blunt)	2	Ischemia	3	Colitis	4	Unknown	1		
Trauma (penetrating)	2	Inflammation	4	Trauma (penetrating)	1	Cancer	4				
Trauma (blunt)	1	Diverticulitis	3	Unknown	1	Trauma (penetrating)	3				
Iatrogenic	2	Cancer	3			Trauma (blunt)	1				
Unknown	4	Ischemia	3			Ischemia	3				
		Unknown	1								

Table 2 Diagnostic values of free air locations in predicting the site of gastrointestinal perforation

Location of free air	*n*	Location of the perforation	Sensitivity (%)	Specificity (%)	PPV (%)	NPV (%)	Accuracy (%)	*P*-value
Perihepatic area	88	SD	86.4	40.3	58	75.8	62.8	0.001
Periportal area	51	SD	54.2	69.3	62.7	61.4	62	0.009
Perigastric area	82	SD	84.7	48.4	61	76.9	66.1	0.000
Mesentery	60	Jİ	78.9	55.9	25	93.4	59.5	0.005
Mesentery	60	DC	81	57	28.3	93.4	61.2	0.002
Pelvis	33	DC	76.2	83	48.5	94.3	81.8	0.000
Periappendiceal area	16	A	72.7	92.7	50	97.1	90.9	0.000

PPV, positive predictive value; *NPV*, negative predictive value; *SD*, stomach-duodenum; *Jİ*, jejunum-ileum; *DC*, distal colon; *A*, appendix vermiformis

mesentery of the sigmoid colon. The significance of mesenteric free air in distal colon perforations can be explained by the presence of mesentery in the sigmoid colon.

A significant relationship was found between periappendiceal free air and appendiceal perforations. The primary pathogenic event in acute appendicitis is luminal obstruction, so it is not surprising that the amount of extraluminal air is generally small or absent [11]. Although the specificity of periappendiceal free air in predicting perforated appendicitis is high (92.7%), the sensitivity was found to be lower (72.7%). The fact that pneumoperitoneum is not detected frequently in perforated appendicitis explains the lower sensitivity of periappendiceal free air in predicting perforated appendicitis found in our study.

Pelvic free air was found to be statistically significant in distal colon perforations, possibly due to anatomical proximity. H. Toprak et al. reported that free air in the minor pelvis, lower quadrants, and mesentery were statistically significant in lower GI tract perforations [14]. In another study, extraluminal air was present around the lower GI tract in 94.7% of patients and in the pelvic cavity in 63.2% of the patients [26]. None of the specific free air distributions was found to be statistically significant in the proximal colon or rectum perforations in the present study. In our opinion, more studies with a higher number of patients may be needed to find a significant relationship, especially in these rare perforation areas.

There are some potential limitations to our study. First, this study was retrospectively designed. The patient population was a selected group of patients who were already confirmed to have gastrointestinal tract perforation by surgery. The small number of cases with perforation at rectum and proximal colon reduces the reliability of the study, particularly for these GI regions. The fact that mesenteric free air was not divided into subgroups like small bowel mesentery and mesocolon may have led to errors in our results. Although two radiologists evaluated the images, this can be considered a single observer as consensus was reached during interpretation. Also, the retrospective nature of the study did not provide an assessment of the performance of the CT findings on patient management. Therefore, further prospective studies are still needed.

In conclusion, specific free air distributions in CT have been found useful in determining the perforation level in the GI tract. In patients with extraluminal free air detected on CT examinations, familiarity with these specific localizations may help to accurately predict the perforation site, changing the treatment plan. Therefore, CT can prompt the correct diagnosis and decrease the mortality and morbidity of the patient by shortening the time of the diagnosis for the emergent operation or other proper management.

Supplementary Information The online version contains supplementary material available at https://doi.org/10.1007/s10140-021-01990-7.

Author contribution HC, MAK and CA evaluated the CT scans regarding intraabdominal free air distribution. HC, MAK, and MS analyzed the data. HC prepared the original draft. CA and IBA helped in writing and editing. MS supervised the research.

Data availability The datasets during and/or analyzed during the current study available from the corresponding author on reasonable request.

Declarations

Ethics approval and consent to participate Our institutional review board approved this retrospective study. Due to its retrospective nature, informed consent was waived.

Consent for publication Available upon request.

Competing interests The authors declare that they have no conflict of interests.

References

1. Knight DJ, Girling KJ (2003) Gut flora in health and disease. Lancet 361(9371):1831. https://doi.org/10.1016/s0140-6736(03)13438-1

2. Ordoñez CA, Puyana JC (2006) Management of peritonitis in the critically ill patient. Surg Clin North Am 86:1323–1349. https://doi.org/10.1016/j.suc.2006.09.006
3. Langell JT, Mulvihill SJ (2008) Gastrointestinal perforation and the acute abdomen. Med Clin North Am 92:599–625. https://doi.org/10.1016/j.mcna.2007.12.004 (viii-ix)
4. Siu WT, Chau CH, Law BK, Tang CN, Ha PY, Li MK (2004) Routine use of laparoscopic repair for perforated peptic ulcer. Br J Surg 91:481–484. https://doi.org/10.1002/bjs.4452
5. Hainaux B, Agneessens E, Bertinotti R, De Maertelaer V, Rubesova E, Capelluto E, Moschopoulos C (2006) Accuracy of MDCT in predicting site of gastrointestinal tract perforation. Am J Roentgenol 187:1179–1183. https://doi.org/10.2214/AJR.05.1179
6. Francavilla ML, Pollock AN (2017) Perforated duodenal ulcer. Pediatr Emerg Care 33:219–220. https://doi.org/10.1097/PEC.0000000000001060
7. Yeung KW, Chang MS, Hsiao CP, Huang JF (2004) CT evaluation of gastrointestinal tract perforation. Clin Imaging 28:329–333. https://doi.org/10.1016/S0899-7071(03)00204-3
8. Miki T, Ogata S, Uto M, Nakazono T, Urata M, Ishibe R, Shinyama S, Nakajo M (2004) Multidetector-row CT findings of colonic perforation: direct visualisation of ruptured colonic wall. Abdom Imaging 29:658–662. https://doi.org/10.1007/s00261-003-0159-y
9. Ghekiere O, Lesnik A, Hoa D, Laffargue G, Uriot C, Taourel P (2007) Value of computed tomography in the diagnosis of the cause of nontraumatic gastrointestinal tract perforation. J Comput Assist Tomogr 31:169–176. https://doi.org/10.1097/01.rct.0000237809.11123.8e
10. Maniatis V, Chryssikopoulos H, Roussakis A, Kalamara C, Kavadias S, Papadopoulos A, Andreou J, Stringaris K (2000) Perforation of the alimentary tract: evaluation with computed tomography. Abdom Imaging 25:373–379. https://doi.org/10.1007/s002610000022
11. Furukawa A, Sakoda M, Yamasaki M, Kono N, Tanaka T, Nitta N, Kanasaki S, Imoto K, Takahashi M, Murata K, Sakamoto T, Tani T (2005) Gastrointestinal tract perforation: CT diagnosis of presence, site, and cause. Abdom Imaging 30:524–534. https://doi.org/10.1007/s00261-004-0289-x
12. Imuta M, Awai K, Nakayama Y, Murata Y, Asao C, Matsukawa T, Yamashita Y (2007) Multidetector CT findings suggesting a perforation site in the gastrointestinal tract: analysis in surgically confirmed 155 patients. Radiat Med 25:113–118. https://doi.org/10.1007/s11604-006-0112-4
13. Brofman N, Atri M, Hanson JM, Grinblat L, Chughtai T, Brenneman F (2006) Evaluation of bowel and mesenteric blunt trauma with multidetector CT. Radiographics 26:1119–1131. https://doi.org/10.1148/rg.264055144
14. Toprak H, Yilmaz TF, Yurtsever I, Sharifov R, Gültekin MA, Yiğman S, Yildiz Ş (2019) Multidetector CT findings in gastrointestinal tract perforation that can help prediction of perforation site accurately. Clin Radiol 74:736.e1-736.e7. https://doi.org/10.1016/j.crad.2019.06.005
15. Earls JP, Dachman AH, Colon E, Garrett MG, Molloy M (1993) Prevalence and duration of postoperative pneumoperitoneum: sensitivity of CT vs left lateral decubitus radiography. AJR Am J Roentgenol 161:781–785. https://doi.org/10.2214/ajr.161.4.8372757
16 Songne B, Jean F, Foulatier O, Khalil H, Scotté M (2004) Traitement non opératoire des perforations d'ulcère gastroduodénal. Résultats d'une étude prospective [Non operative treatment for perforated peptic ulcer: results of a prospective study]. Ann Chir 129:578–82. https://doi.org/10.1016/j.anchir.2004.06.012 (French)
17. van Dijk ST, Rottier SJ, van Geloven AAW, Boermeester MA (2017) Conservative treatment of acute colonic diverticulitis. Curr Infect Dis Rep 23(19):44. https://doi.org/10.1007/s11908-017-0600-y
18. Cao F, Li J, Li A, Fang Y, Wang YJ, Li F (2014) Nonoperative management for perforated peptic ulcer: who can benefit? Asian J Surg 37:148–153. https://doi.org/10.1016/j.asjsur.2013.10.002
19. Grassi R, Romano S, Pinto A, Romano L (2004) Gastro-duodenal perforations: conventional plain film, US and CT findings in 166 consecutive patients. Eur J Radiol 50:30–36. https://doi.org/10.1016/j.ejrad.2003.11.012
20. Kim HC, Yang DM, Kim SW, Park SJ (2014) Gastrointestinal tract perforation: evaluation of MDCT according to perforation site and elapsed time. Eur Radiol 24:1386–1393. https://doi.org/10.1007/s00330-014-3115-z
21. Choi AL, Jang KM, Kim MJ, Koh SH, Lee Y, Min K, Choi D (2011) What determines the periportal free air, and ligamentum teres and falciform ligament signs on CT: can these specific air distributions be valuable predictors of gastroduodenal perforation? Eur J Radiol 77:319–324. https://doi.org/10.1016/j.ejrad.2009.07.033
22. Cho HS, Yoon SE, Park SH, Kim H, Lee YH, Yoon KH (2009) Distinction between upper and lower gastrointestinal perforation: usefulness of the periportal free air sign on computed tomography. Eur J Radiol 69:108–113. https://doi.org/10.1016/j.ejrad.2007.08.024
23. Stoker J, van Randen A, Laméris W, Boermeester MA (2009) Imaging patients with acute abdominal pain. Radiology 253:31–46. https://doi.org/10.1148/radiol.2531090302
24. Kim HC, Shin HC, Park SJ, Park SI, Kim HH, Bae WK, Kim IY, Jeong DS (2004) Traumatic bowel perforation: analysis of CT findings according to the perforation site and the elapsed time since accident. Clin Imaging 28:334–339. https://doi.org/10.1016/S0899-7071(03)00244-4
25. Ishtiaq R, Niaz K, Masood D, Ishtiaq D, Yasin S, Chaudhry UH, Ashraf A (2017) Not a common rectosigmoid perforation. Cureus 13(9):e1465. https://doi.org/10.7759/cureus.1465
26. Oguro S, Funabiki T, Hosoda K, Inoue Y, Yamane T, Sato M, Kitano M, Jinzaki M (2010) 64-Slice multidetector computed tomography evaluation of gastrointestinal tract perforation site: detectability of direct findings in upper and lower GI tract. Eur Radiol 20:1396–1403. https://doi.org/10.1007/s00330-009-1670-5

Publisher's note Springer Nature remains neutral with regard to jurisdictional claims in published maps and institutional affiliations.