PSYCHIATRY AND CLINICAL PSYCHOPHARMACOLOGY
2019, VOL. 29, NO. 3, 293–297
https://doi.org/10.1080/24750573.2019.1637040

Taylor & Francis
Taylor & Francis Group

OPEN ACCESS Check for updates

Cerebellar volumes in early-onset bipolar disorder: a pilot study of a stereological measurement technique

Burcu Serim Demirgören [a], Aylin Özbek[a], Nüket Göçmen Karabekir[b], Bari Ay[a], Serkan Turan [a], Gökşin Nilüfer Yonguç[b], Selim Karabekir[c], Ayşe İpek Polat[d], Ayşe Semra Hız[d] and Özlem Gencer Kıdak[a]

[a]Department of Child and Adolescent Psychiatry, Faculty of Medicine, Dokuz Eylul University, Izmir, Turkey; [b]Department of Anatomy, Faculty of Medicine, Dokuz Eylul University, Izmir, Turkey; [c]Department of Neurosurgery, Faculty of Medicine, Dokuz Eylul University, Izmir, Turkey; [d]Department of Child Neurology, Faculty of Medicine, Dokuz Eylul University, Izmir, Turkey

ABSTRACT

OBJECTIVE: Recent data from the literature have recognized the importance of cerebellum in bipolar disorder. Brain imaging studies focusing on cerebellar volumetric changes in bipolar disorder demonstrated controversial data. The aim of this study is to investigate whether there is any difference between early-onset bipolar cases and healthy controls regarding cerebellar volumetric measurements.

METHODS: Patients with bipolar I disorder were compared to healthy controls in terms of total cerebellar volume, volumes of the right and left cerebellar hemispheres, and cerebellar volumetric asymmetry. All the sociodemographic, clinical data, and magnetic resonance image scans were collected retrospectively. Cerebellar volumes were evaluated using the stereological method. Asymmetry indices were calculated subsequently.

RESULTS: We recruited 10 bipolar I cases and 10 healthy controls. There were no statistically significant differences between the bipolar and the control groups for total cerebellar volumes, volumes of right and left cerebellar hemispheres, and cerebellar asymmetry indices.

CONCLUSION: Future studies focusing on cerebellar changes in early-onset bipolar disorder should include large case and control series and designed as follow-up studies for being able to determine the chronic effects of the illness on cerebellar volumes.

ARTICLE HISTORY
Received 15 April 2019
Accepted 24 June 2019

KEYWORDS
Early-onset bipolar disorder; cerebellum; stereology; magnetic resonance imaging; volumetric measurements; cerebellar asymmetry

Introduction

Bipolar disorder is a debilitating psychiatric illness characterized by severe changes in the mood [1,2]. Early-onset bipolar disorder is represented by slow response to treatment, persistent mood fluctuations, elevated risk for suicidal attempts, and severe psychosocial impairment [2]. Although the pathophysiology underlying the mood-state transitions in bipolar disorder remains largely unknown, many studies of the disorder using imaging techniques have implicated various brain structures such as the amygdala, anterior paralimbic cortices which are central to emotional processing [1,3].

Accumulating evidence have recognized the importance of cerebellum in emotional regulation and cognitive activities involving executive functioning, episodic memory, and sensorimotor processing in addition to its well-known motor control functions [3–5]. This feature provides a strong neuroanatomical basis for the involvement of the cerebellum in emotional regulation.

Functional magnetic resonance imaging studies found resting-state abnormalities of cerebellar functional connectivity in patients with bipolar disorder [6,7]. Cerebrocerebellar hypoconnectivity in specific brain networks may associate with abnormal timing, coordination, integration and signal processing observed as the cognitive, emotional, and behavioral symptoms of bipolar disorder [6].

Structural brain imaging studies focusing on volumetric changes of cerebellum did not find significantly smaller cerebellar hemispheres compared with healthy subjects in adult bipolar patients [8–11]. However, there is very limited data on the early-onset bipolar disorder. Adler et al. reported larger bilateral cerebellar grey matter volume in a mixed sample of adolescents and adults (age range 13–41 y) with bipolar I disorder in first-episode compared to healthy subjects [12]. Controversially, in a longitudinal study, patients with bipolar disorder showed a decrease in cerebellar grey matter density over 4 years, and this decline was more rapid than that observed in healthy control subjects [13].

James et al. [14] found loss of grey matter density in the cerebellum of adolescents with bipolar disorder. Studies investigating the importance of cerebellum in neuropsychiatric disorders have focused not only on cerebellar volumetric measurements but also on

CONTACT Burcu Serim Demirgören burcuserim@hotmail.com Department of Child and Adolescent Psychiatry, Faculty of Medicine, Dokuz Eylul University, Izmir, Turkey

© 2019 The Author(s). Published by Informa UK Limited, trading as Taylor & Francis Group
This is an Open Access article distributed under the terms of the Creative Commons Attribution License (http://creativecommons.org/licenses/by/4.0/), which permits unrestricted use, distribution, and reproduction in any medium, provided the original work is properly cited.

cerebellar asymmetry [15,16]. It has been indicated that there is a pattern of cerebellar asymmetry in all healthy humans. And the asymmetry index is positive as the right hemisphere volume is larger than the left [15,16]. There are some studies suggesting that cerebellar asymmetry is reversed in schizophrenia compared to healthy controls [15].

To our knowledge, there is no study exploring cerebellar volumetric asymmetry in early-onset bipolar disorder.

The aim of this study is to determine whether there are any differences between early-onset bipolar cases and healthy controls in terms of total cerebellar volume, volumes of the right and left cerebellar hemispheres, and cerebellar volumetric asymmetry.

Materials and methods

Features of the inpatient unit

The Child and Adolescent Pscyhiatry inpatient unit of Dokuz Eylül University has been founded in 2005 with a capacity of fifteen patients. The inpatient unit is a member of the Quality Network for Inpatient CAMHS (QNIC). QNIC is an initiative of the Royal College of Psychiatrists in the United Kingdom.

Sample and procedure

The study is retrospective in design. All of the children and adolescents who have been diagnosed as early-onset bipolar I disorder based on DSM-IV-TR [17] and received treatment between the years of 2005 and 2018 in our inpatient unit with magnetic resonance image (MRI) scans obtained during hospitalization composed the cases of our study. From the total of fourteen adolescents three male and one left-handed female case were excluded from the study since handedness and gender have been inquired for cerebellar volumes, asymmetry, connectivity, and activation [18,19].

The healthy control group composed of 10 age- and gender-matched right-handed children and adolescents who had admitted to the child neurology department of the same hospital for headaches. Those who had a normal neurological examination and normal MRI scan results, did not have a history of any neurological disorder, head trauma, any chronic disorder including any psychiatric disorder, and had no history of admission to psychiatric services for any reason are recruited to the study.

Sociodemographic, clinical, and MRI image acquisition data were collected retrospectively from the hospital records of both cases and controls.

This study was approved by the Medical Sciences Research Ethics Committee of Dokuz Eylul University with decision number 2017/25-18.

MRI acquisition and stereological analysis

MRI images were obtained via an MRI machine (1.5 Tesla Gyroscan Achieva, release 8:1; Philips Medical Systems, Best, The Netherlands) from bipolar cases and healthy controls. Volumetric measurements of cerebellum were performed by using a stereological method described by Cavalieri (Cavalieri principle combined with point counting) [20,21]. This stereological method is known as efficient, simple, unbiased, and reliable for volumetric evaluations of anatomical structures [21].

T1-weighted sagittal sections (3 mm thick) were obtained with a 1.5-T magnetic resonance (MR) machine. The stereological measurements of the total and hemi cerebellar volumes were performed by two blinded observers. An optimal plane was obtained using the smallest diameter of each anisotropic structure that can be measured in two-dimensional analyses on sagittal MRI sections. This value was multiplied by the cross-sectional thickness and the volume parameter. A uniform point grid with a point-associated area of 0.625 cm^2 was randomly superimposed on each MR image using the grid. Points that hit the cerebellum were manually counted for volume estimation. The cerebellar volumes were calculated according to formula as described below:

$$V = t \times [((SU) \times d)/SL]2 \times \Sigma P$$

In this formula, "t" defines the section thickness, "SU" the scale unit (the real length of the scale marked on the MRIs), "d" the distance between two points in the point grid, "SL" the scale length (the actual measure of the scale on MRI), and "P" the number of points counted.

Also, coefficient of error (CE) values, which provide information about the accuracy of volumetric sampling, were calculated [21].

To evaluate the interhemispheric asymmetry between the hemispheres, middle sections were identified by clear visualization of the cerebral aqueduct. The number of points of the middle section was divided by two and the results were added to the total point counts for each hemisphere separately. Thereby, the volumes of each cerebellar hemisphere were calculated. The stereological point counting technique representing the point grid superimposed on cerebellum is described in Figure 1.

Asymmetry index were calculated as described in our former study [((Right _ Left)/(Right _ Left)) * 100] [15,22].

Statistical analysis

Shapiro–Wilk test was used to assess the normality of distributions of the variables, and Levene's test was used to assess the homogeneity of variances in different groups. Independent sample *t*-test was used for comparison of the independent groups and paired sample

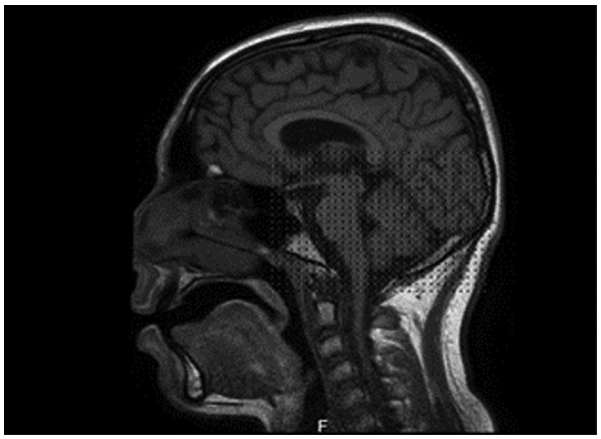

Figure 1. The stereological point counting technique.

t-test was used for dependent groups. The results of tests were expressed as the number of observations (*n*), the mean ± standard deviation (mean ± SD). Data analyses were performed with SPSS 24.0 software. A *P*-value less than .05 was considered as statistically significant.

Results

There were 10 bipolar I cases and 10 healthy controls. All the cases and the controls were right-handed girls. The mean (±SD) age was 184.40 (±21.73) months (15.30 ± 1.88 years) for bipolar cases and 183.30 (±22.54) months (15.30 ± 1.88 years) for healthy controls. Comparison of the ages of both groups did not display any significant differences ($P = .978$). Additional clinical data such as medication used and the results of clinical scales applied during treatment of the cases are provided in Table 1.

Table 1. Additional clinical data of bipolar patients.

Clinical measures applied	Scores of clinical measurements Mean (± SD)	Number of patients *N* (%)
YMRS	30.87 (10.28)	8 (80)
CDRS	53.0 (7.07)	2 (20)
CGAS	31.30 (7.10)	10 (100)
Type and dosage of atypical antipsychotic used for treatment	Mg/day Mean (± SD)	Number of patients *N* (%)
Aripiprazole	21.66 (9.30)	6 (60)
Clozapine	300	1 (10)
Quetiapine	600 (0.0)	2 (20)
Risperidone	1	1 (10)
Type and dosage of mood stabilizer used for treatment	Mg/day Mean (± SD)	Number of patients *N* (%)
Lithium	1050.0 (212.13)	2 (20)
Valproate	1187.50 (176.77)	8 (80)

Notes: YMRS: young mania rating scale, CDRS: the children's depression rating scale, CGAS: children's global assessment scale.

Table 2. Comparison of cerebellar volumes and cerebellar asymmetry indices between patients with early-onset bipolar disorder and controls.

	Mean (±SD)			Confidence interval (95%)	
Volumes	Bipolar *N* = 10	Control *N* = 10	*P**	Lower	Upper
Total cerebellar	98.23 (2.71)	98.60 (3.12)	.781	−2.38	3.12
Right cerebellar hemisphere	48.36 (1.27)	49.03 (1.92)	.373	−0.86	2.20
Left cerebellar hemisphere	49.86 (1.62)	49.56 (1.42)	.668	−1.73	1.13
Asymmetry indices	−1.51 (1.05)	−0.55 (1.33)	.091	−0.16	2.08

Note: Cerebellar volumes (cm^3) are reported as mean (S.D.). *P** values are given for comparison of cerebellar volumes between groups; Independent samples test.

Comparison of bipolar cases and controls for cerebellar volumes and cerebellar volumetric asymmetry indices

There were no statistically significant differences between the bipolar and the control group for total cerebellar volumes, volumes of right and left cerebellar hemispheres, and cerebellar asymmetry indices. Results are presented in Table 2.

In the bipolar group, mean CE values for right and left hemispheres were 0.029 ± 0.010 and 0.025 ± 0.008, respectively. In the control group, mean CE values for right and left hemispheres were 0.032 ± 0.009 and 0.051 ± 0.008, respectively. All calculated CE values were in an acceptable range reflecting the reliability of the stereological measurements [23,24].

Discussion

We did not find any statistically significant differences in any of cerebellar volumetric measures including asymmetry indices between bipolar patients and healthy controls.

In the literature, there are controversial data about cerebellar volumetric changes in patients with bipolar disorder. In some studies, conducted with adult patients with bipolar disorder, it was shown that cerebellar volumes did not differ according to healthy controls [8–11]. Mills et al. [10] found midline vermal changes in bipolar adult patients with a history of multiple mood episodes. Monkul et al. did not find any statistically significant differences between bipolar patients and healthy controls in any of the cerebellum and vermis regions measured [25]. However, they reported non-significant tendency for smaller vermis V2 (the superior posterior lobe) area in patients. They also found a significant inverse correlation between the number of prior affective episodes and V2 area in male bipolar patients [25]. James et al. [14] reported the loss of grey matter density in the cerebellum of paediatric bipolar disorders.

In their study, Brambilla et al. [9] compared bipolar patients who had a first-degree relative with a history of mood disorders with the bipolar patients who had not a first-degree relative with mood disorders in terms of cerebellar volumes. As an interesting result, they found that patients with a family history of

mood disorders had smaller cerebellar hemispheres and vermis volumes and larger left lateral ventricle volumes [9].

Although data from the literature showed cerebellar volumetric changes in the patients with bipolar disorder compared to healthy controls, our study did not display any difference between early-onset bipolar patients with an average age of 15 and matched controls. An explanation for this discrepancy might be related to the age of our cases. A search of the literature reveals data regarding the cerebellar volumes in bipolar patients come from adult patients with multiple mood episodes, therefore with a chronic course. Whereas our adolescent patients might not have been reflecting the chronic effects of multiple episodes of the disorder. Therefore, follow-up of our patients into adulthood might yield to different results.

In addition to cerebellar volumetric measurements, we also investigated the presence of cerebellar asymmetry in our study. Although there are some studies investigating cerebellar asymmetry in adult and early-onset schizophrenia, to our knowledge, there is no study exploring cerebellar volumetric asymmetry in both adult and early-onset bipolar disorder [15,16,22]. In their study, Szesko et al. [15] submitted that although patients and healthy comparison subjects did not differ in any of cerebellar volumes, cerebellar asymmetry is reversed in patients with schizophrenia. On the other hand, a study conducted by Özbek et al. [22] did not reveal any cerebellar asymmetry in early-onset schizophrenia cases in comparison to controls. Similar to Özbek et al.'s finding in early-onset schizophrenia patients, we could not find a significant difference in cerebellar asymmetry indices between early-onset bipolar cases and healthy controls. Similar to the other cerebellar volumetric changes, age of onset and level of chronicity might also account for this finding. Additionally, this novel issue needs to be investigated in early-onset bipolar disorder with a larger sample size with various ages of onset.

Strengths and limitations

The retrospective design of this study provides some advantages such as enabling the collection of data for a rare disorder from the hospital records and being cost-effective. But there are some limitations as well. An important limitation of this study is the low number of cases. Besides, none of our patients were medication free. Therefore, we cannot eliminate the effects of psychotropic medications. As another limitation, we used 3 mm slices to measure cerebellar volumes. Although 3 mm slice thickness is suggested to be sufficient for analysing brain MRIs, thinner slices might have provided different results [26]. In spite of several limitations, the findings of our study may have value in guiding future studies evaluating the role of cerebellum in bipolar disorder.

Disclosure statement

No potential conflict of interest was reported by the authors.

ORCID

Burcu Serim Demirgören http://orcid.org/0000-0002-1659-2798
Serkan Turan http://orcid.org/0000-0002-6548-0629

References

[1] Johnson CP, Christensen GE, Fiedorowicz JG, et al. Alterations of the cerebellum and basal ganglia in bipolar disorder mood states detected by quantitative T1ρ mapping. Bipolar Disord. 2018;20:381–390.
[2] Biederman J, Mick E, Faraone SV, et al. Pediatric mania: a developmental subtype of bipolar disorder? Biol Psychiatry. 2000;48:458–466.
[3] Baldaçara L, Nery-Fernandes F, Rocha M, et al. Is cerebellar volume related to bipolar disorder? J Affect Disord. 2011;135:305–309.
[4] Lin K, Shao R, Lu R, et al. Resting-state fMRI signals in offspring of parents with bipolar disorder at the high-risk and ultra-high-risk stages and their relations with cognitive function. J Psychiatr Res. 2018;98:99–106.
[5] Rapoport M, van Reekum R, Mayberg H. The role of the cerebellum in cognition and behaviour. J Neuropsychiatry Clin Neurosci. 2000;12:193–198.
[6] Shinn AK, Roh YS, Ravichandran CT, et al. Aberrant cerebellar connectivity in bipolar disorder with psychosis. Biol Psychiatry Cogn Neurosci Neuroimaging. 2017;2:438–448.
[7] Mamah D, Barch DM, Repovs G. Resting state functional connectivity of five neural networks in bipolar disorder and schizophrenia. J Affect Disord. 2013;150:601–609.
[8] DelBello MP, Strakowski SM, Zimmerman ME, et al. MRI analysis of the cerebellum in bipolar disorder: a pilot study. Neuropsychopharmacology. 1999;21:63–68.
[9] Brambilla P, Harenski K, Nicoletti M, et al. MRI study of posterior fossa structures and brain ventricles in bipolar patients. J Psychiatr Res. 2001;35:313–322.
[10] Mills NP, Delbello MP, Adler CM, et al. MRI analysis of cerebellar vermal abnormalities in bipolar disorder. Am J Psychiatry. 2005;162(8):1530–1532.
[11] Laidi C, d'Albisa M, Wessaf M, et al. Cerebellar volume in schizophrenia and bipolar I disorder with and without psychotic features. Acta Psychiatr Scand. 2015;131:223–233.
[12] Adler CM, DelBello MP, Jarvis K, et al. Voxelbased study of structural changes in first-episode patients with bipolar disorder. Biol Psychiatry. 2007;61(6):776–781.
[13] Moorhead TW, McKirdy J, Sussmann JE, et al. Progressive gray matter loss in patients with bipolar disorder. Biol Psychiatry. 2007;62:894–900.
[14] James A, Hough M, James S, et al. Structural brain and neuropsychometric changes associated with pediatric bipolar disorder with psychosis. Bipolar Disord. 2011;13:16–27.
[15] Szeszko PR, Gunning-Dixon F, Ashtari M, et al. Reversed cerebellar asymmetry in Men with first-episode schizophrenia. Biol Psychiatry. 2003;53:450–459.
[16] Bilder R, Wu H, Bogerts B, et al. Absence of regional hemispheric volume asymmetries in first-episode schizophrenia. Am J Psychiatry. 1994;151:1437–1447.

[17] American Psychiatric Association. Diagnostic and statistical manual of mental disorders: DSM-IV-TR. Washington, DC: American Psychiatric Association; 2000.
[18] Brossard-Racine M, Limperopoulos C. Normal cerebellar development by qualitative and quantitative MR imaging from the fetus to the adolescent. Neuroimag Clin N Am. 2016;26(3):331–339.
[19] Kavaklioglu T, Guadalupe T, Zwiers M, et al. Structural asymmetries of the human cerebellum in relation to cerebral cortical asymmetries and handedness. Brain Struct Funct. 2017;222(4):1611–1623.
[20] Zeinali R, Keshtkar A, Zamani A, et al. Brain volume estimation enhancement by morphological image processing Tools. J Biomed Phys Eng. 2017;7(4):379–388.
[21] Theophilus NA, Leila N, Migle M, et al. A comparative study of segmentation techniques for the quantification of brain subcortical volume. Brain Imaging Behav. 2018 Feb 13; doi:10.1007/s11682-018-9835-y.
[22] Özbek A, Mas NG, Turan S, et al. Cerebellar volumes in early onset schizophrenia; comparison with healthy controls and association with symptom severity. J Int Med Res. 2019;47(1):411–419.
[23] Gundersen HJG, Jensen EB. The efficiency of systematic sampling in stereology and its prediction. J Microsc. 1987;147:229–263.
[24] Gundersen HJG, Osterby R. Sampling efficiency and biological variation in stereology. Mikroskopie. 1980;37:143–148.
[25] Monkul ES, Hatch JP, Sassi RB, et al. MRI study of the cerebellum in young bipolar patients. Prog Neuropsychopharmacol Biol Psychiatry. 2008;32:613–619.
[26] Savio SJ, Harrison LC, Luukkaala T, et al. Effect of slice thickness on brain magnetic resonance image texture analysis. Biomed Eng Online. 2010;18(9):60, doi:10.1186/1475-925X-9-60.