Journal of Paediatrics and Child Health

doi:10.1111/jpc.16158

CASE REPORT

A complication of lysinuric protein intolerance: Intermittent haemophagocytic lymphohistiocytosis

Şefika Akyol [1], Şebnem Yılmaz [1], Özlem Tüfekçi [1], Nur Arslan [2] and Hale Ören [1]

Departments of [1]Pediatric Hematology, and [2]Pediatric Metabolic Diseases, Dokuz Eylül University, Faculty of Medicine, İzmir, Turkey

Case 1

An 18-month-old female patient was referred due to elevated lactate dehydrogenase (LDH) levels. She had no complaints, including fever, on admission. There was no known history of disease before. In physical examination, no pathological finding was detected except hepatosplenomegaly. The white blood cell count was 6400/μL, the absolute neutrophil count was 2200/μL, haemoglobin 11.5 g/dL, MCV 76 fL, platelet count 262 000/μL and reticulocyte 1.9%. Erythrocyte sedimentation rate (ESR) and C-reactive protein (CRP) were normal. LDH was 1584 U/L, ferritin 427 ng/mL, fibrinogen 0.6 g/L, and triglyceride 796 mg/dL, renal and liver function tests were within normal limits. No atypical cells were observed in the peripheral blood smear. Bone marrow aspiration (BMA) revealed histiocytes, most containing phagocytosed erythroid and pycnotic neutrophil nuclei in many areas, and also neutrophils with apoptotic, pycnotic nuclei. In Figure 1, BMA images of the patient are shown. Low arginine and lysine levels in plasma amino acids (AAs); high arginine, lysine and ornithine levels in urine AAs were detected and hence a diagnosis of lysinuric protein intolerance (LPI) was made. Oral citrulline and arginine were started, and a diet restricted in protein, and rich in carbohydrates and fats was arranged. Upon detection of hyperammonaemia, sodium benzoate was started. After the initiation of a special diet, her symptoms had improved and there was no need for specific haemophagocytic lymphohistiocytosis (HLH) treatment. Homozygous p.G86E (c.257G>A) mutation was detected in the SLC7A9 gene.

Key points

1 The diagnosis of lysinuric protein intolerance (LPI) or other metabolic disorders causing haemophagocytic lymphohistiocytosis (HLH) should be considered in every patient presenting with symptoms of HLH, even in adults. Therefore careful investigation of the patient's history, and clinical and laboratory findings are obligatory. The diagnosis and treatment should be addressed rapidly because of the life-threatening consequences.
2 Recognition of chronic intermittent HLH findings, initiation of effective treatment and ensuring metabolic control under appropriate conditions in patients with the diagnosis of LPI are of clinical importance.

Case 2

A 7-month-old male who was being followed up with the diagnosis of LPI was admitted to our clinic because of elevated ferritin, LDH and triglyceride levels. He was the younger sibling of the first case. Similar to his elder sister, a homozygous p.G86E (c.257G>A) mutation was detected in the SLC7A9 gene. The white blood cell count was 1600/μL, the absolute neutrophil count was 500/μL, haemoglobin 8.8 g/dL, MCV 66.8 fL, platelet count 208 000/μL and reticulocyte 2%. ESR and CRP were within normal limits. LDH was 3248 U/L, ferritin 354 ng/mL, fibrinogen 0.9 g/L, and triglyceride 1494 mg/dL, renal and liver function tests were normal. In addition, the ammonia level was 213 μmol/L, and this was attributed to his insufficient metabolic control. He had no fever and rash. In physical examination, massive hepatosplenomegaly was observed. Both the liver and spleen were 9 cm palpable in the subcostal area. In addition, the neurological developmental delay was identified in motor and mental areas. In BMA, normocellular bone marrow and lymphoid serial dominance were observed in accordance with age, erythroid serial activity was increased and nuclear dysplasia was present. Haemophagocytic histiocytes were observed in large numbers. Therefore, the patient's current diagnosis of LPI, the presence of impaired metabolic control, and clinical, laboratory and bone marrow findings were all evaluated together and a diagnosis of LPI-related HLH was considered. Fever was added to the clinical course within the first 24 h. The patient was administered intravenous immunoglobulin and dexamethasone at a dose of 1 g/kg and 10 mg/m^2/day, respectively. Besides, the treatment of the patient who had non-compliance with a specific metabolic diet

Correspondence: Şefika Akyol, Department of Pediatrics, Division of Pediatric Hematology and Oncology, Dokuz Eylul University, Faculty of Medicine, İnciraltı Mahallesi Mithatpaşa cad. no: 1606 Balçova/İzmir, Turkey; email: drsefikaakyol@gmail.com

Grants: None.

Conflict of interest: None declared.

Author contributions: All authors take responsibility for the content of the work submitted for review. The authors confirm contribution to the paper as follows: study conception and design: all authors; data collection: Şefika Akyol; analysis and interpretation of results: all authors; draft manuscript preparation: Şefika Akyol, Hale Ören. All authors reviewed the results and approved the final version of the manuscript. All the authors have accepted responsibility for the entire content of this submitted manuscript and approved submission.

Accepted for publication 26 July 2022.

© 2022 Paediatrics and Child Health Division (The Royal Australasian College of Physicians).

14401754, 0, Downloaded from https://onlinelibrary.wiley.com/doi/10.1111/jpc.16158 by Dokuz Eylul University, Wiley Online Library on [23/11/2022]. See the Terms and Conditions (https://onlinelibrary.wiley.com/terms-and-conditions) on Wiley Online Library for rules of use; OA articles are governed by the applicable Creative Commons License

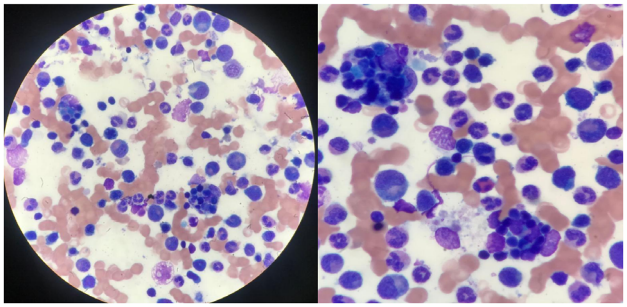

Fig. 1 Histiocytes phagocyting erythroid cells and pycnotic neutrophil nuclei and neutrophils with apoptotic nuclei.

was rearranged. On the ninth day of his hospitalisation, clinical and laboratory remission was achieved, and he was discharged on a weaning regime of dexamethasone and with a metabolic treatment programme. The patient, who is currently 36 months old, has been admitted with the clinical picture of LPI-related HLH four times in total and responds to treatment.

Discussion

HLH is a life-threatening syndrome of excessive immune activation, hyperinflammation, increased phagocytic activity and tissue damage, mainly seen in the paediatric age. In addition, a quarter of the cases are considered as familial. About 10% of the cases are diagnosed in the first 4 weeks and 70–80% of them are diagnosed in the first year.[1,2] Autoimmune diseases, genetic metabolic diseases and infectious processes may result in clinical features of HLH, and diagnostic difficulties may arise as there is no single pathognomonic test for diagnosis.[1–3] One of these diseases is LPI.

LPI is an autosomal recessively inherited disorder of dibasic amino acid metabolism.[4] It is inherited by pathological variants of the SLC7A7 gene located on the 14q11.2 locus of chromosome 14.[5,6] LPI has been considered as a benign urea cycle disease for a long while and suggested receiving adequate treatment with an appropriate low-protein diet and L-citrulline replacement. On the contrary, in the light of our current knowledge, it is an entity with high morbidity and mortality with multi-organ involvement.[6]

Our first case had high LDH levels, and changes in the levels of plasma and urinary organic acids, and these findings lead us to the diagnosis of LPI. Her BMA findings were interesting with histiocytes phagocyting erythroid cells and pycnotic neutrophil nuclei, and neutrophils with apoptotic nuclei. This image has been reported in patients with LPI.[7] The second patient who was being followed up with LPI diagnosis had exhibited clinical and laboratory findings of HLH with persistent fever and cytopenias. On account of this, HLH treatment was started quickly, in addition to arranging specific diet therapy. In this patient's scenario, because of the age at admission, gender, clinical signs and symptoms, and also laboratory findings; he could have been misdiagnosed as familial HLH.

In fact, LPI has some unique presentation findings that typically arise after weaning breast milk. Vomiting and diarrhoea, short stature, failure to thrive, feeling sick after protein-rich meals and associated malnutrition can be seen. Also, LPI should be considered in unexplained hyperammonaemic crises. It has been previously reported in the literature that splenomegaly, hyperlipidaemia and cytopenias, which are major criteria of HLH, are already present in LPI patients.[2,6,7] Therefore, a patient who has not been diagnosed with LPI may have a misdiagnosis of HLH. It should be kept in mind that, HLH may be the first presenting sign of LPI in the neonatal period and metabolic diseases should be excluded in such cases. HLH development based on LPI is a chronic intermittent course and hyperferritinaemia and LDH elevation are observed permanently in the laboratory findings of the patient.[8] In the clinical follow-up of one of our patients, noncompliance with diet persisted and HLH development reoccurred. Multi-organ involvement and cytopenias due to haematological involvement occurred. Hyperferritinaemia, elevated LDH and hepatosplenomegaly persisted in the periods between HLH attacks and worsened with the attacks. The main goal of LPI therapy is to provide adequate nutrition to the patient, thus preventing hyperammonaemia and long-term complications. Patients who achieve metabolic control by complying with diet and supportive treatments may experience fewer attacks.[5,6] Unfortunately, it took time to achieve metabolic control and decrease the frequency of attacks in our patients.

Ethics Statement

The local Institutional Review Board deemed the study. Informed consent for sharing images and content was obtained from the patients and their families.

References

1 Canna SW, Marsh RA. Pediatric hemophagocytic lymphohistiocytosis. *Blood* 2020; **135**: 1332–43.
2 Ponnatt TS, Lilley CM, Mirza KM. Hemophagocytic lymphohistiocytosis. *Arch. Pathol. Lab. Med.* 2022; **146**: 507–19.
3 Si SJ, Tasian SK, Bassiri H *et al*. Diagnostic challenges in pediatric hemophagocytic lymphohistiocytosis. *J. Clin. Immunol.* 2021; **41**: 1213–8.
4 Ogier de Baulny H, Schiff M, Dionisi-Vici C. Lysinuric protein intolerance (LPI): A multi organ disease by far more complex than a classic urea cycle disorder. *Mol. Genet. Metab.* 2012; **106**: 12–7.
5 Alqarajeh F, Omorodion J, Bosfield K, Shur N, Ferreira CR. Lysinuric protein intolerance: Pearls to detect this otherwise easily missed diagnosis. *Transl. Sci. Rare Dis.* 2020; **5**: 81–6.
6 Mauhin W, Habarou F, Gobin S *et al*. Update on lysinuric protein intolerance, a multi-faceted disease retrospective cohort analysis from birth to adulthood. *Orphanet J. Rare Dis.* 2017; **12**: 3.
7 Gürsel T, Koçak U, Tümer L, Hasanoğlu A. Bone marrow hemophagocytosis and immunological abnormalities in a patient with lysinuric protein intolerance. *Acta Haematol.* 1997; **98**: 160–2.
8 Duval M, Fenneteau O, Doireau V *et al*. Intermittent hemophagocytic lymphohistiocytosis is a regular feature of lysinuric protein intolerance. *J. Pediatr.* 1999; **134**: 236–9.

© 2022 Paediatrics and Child Health Division (The Royal Australasian College of Physicians).

14401754, 0, Downloaded from https://onlinelibrary.wiley.com/doi/10.1111/jpc.16158 by Dokuz Eylul University, Wiley Online Library on [23/11/2022]. See the Terms and Conditions (https://onlinelibrary.wiley.com/terms-and-conditions) on Wiley Online Library for rules of use; OA articles are governed by the applicable Creative Commons License