# Unexpanded coronary stent due to rupture of  stent balloon

Adam Uf Turk, Ayşe Çolak, Hacer Uysal, Sercan Karaoğlan
DOKUZ EYLÜL ÜNİVERSİTESİ HASTANESİ - KARDİYOLOJİ ANABİLİMDALI -İZMİR

## introduction

*Rare stent complications ,including dislodgement of stent , unexpanded stent ,stent fracture and stent loss can ocur during percutaneous coronary interventions .*
*Rupture of coronary stent balloon is a rare complication of coronary interventions,it can lead to stent dislodgement,stent loss and can lead to serious events including cerebrovascular embolism,myocardial infarction or even death.*

*İn this case report we present a semi-expanded stent due to rupture of the stent balloon.*

## Case report

A 73-year-old male patient presented to the emergency department with chest pain was diagnosed with NSTEMİ,he has a history of coronary PCİ performed 4 years ago. on the angiogram there was no significant lesion in the CX and RCA and there was an in-stent %80 lesion in the distal LAD stent that was implanted before, there was a %70 lesion in the proximal portion of the stent, a %95 lesion was observed in the first Diagonal branch. we started the procedure by engaging a 6F Judskin guiding catheter to the LMCA ostium, after that a floppy guidewire was crossed through the first diagonal another floppy guidewire was crossed through the distal LAD stent successfully, we predilated the lesion in the first diagonal branch by using a 2x12 mm balloon and then we planned to implant a 2,5x21 mm Firehawk DES to the residue lesion.



while inflating the stent balloon we recognized a dye leakage and we observed that the stent was not expanding successfully(figure 1).we performed the stent boost technique to evaluate the expansion of the stent,we observed that only the head and the end portions of the stent were inflated and the middle portion was unabled to inflate correctly (figure2). we planned to pull the ruptured balloon of the stent and to inflate a 1,25x12 mm PTCA,2x15mm PTCA, 2,5x15 mm NC respectively in the unexpanded part of the stent.
But while trying to pull the balloon we noticed that the struts of the stent were moving backwards with the balloon so we decided to pull the stent back from the coronary tree,because the head of the stent was expanded we could not take the stent back into the catheter and because the risk of stent loss we pulled all of the equipment back while keeping the stent struts attached to the tip of the catheter.The stent was removed from the patient without any dissection or perforation(figüre 3)
After that we engaged an EBU 3.5 catheter to the LMCA and we successfully implanted a 2,25x19 mm FİREHAWK DES to the first diagonal and a 2,75x13 mm FİREHAWK DES to the distal LAD and the procedure was performed with a TIMI-3 flow in the LAD and first diagonal.

figure 1

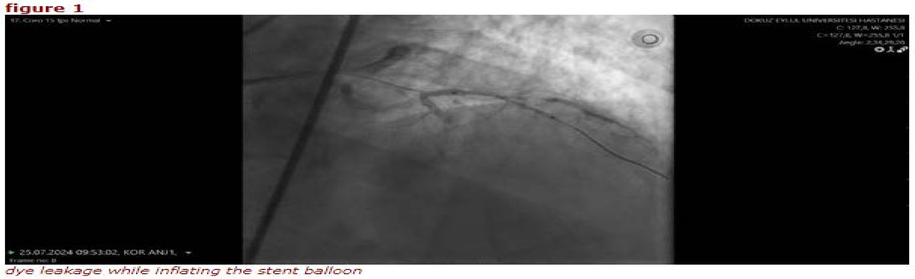

dye leakage while inflating the stent balloon

figure 2

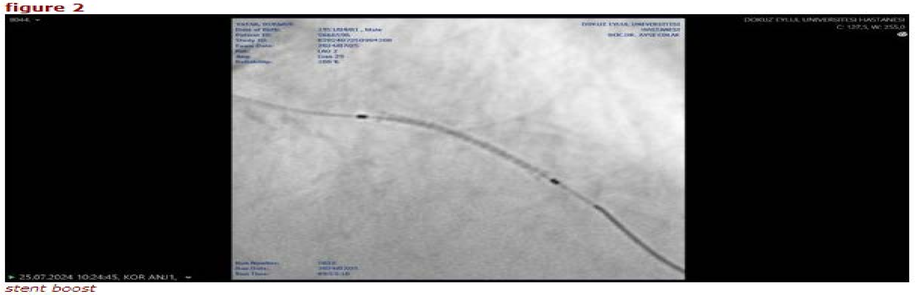

stent boost

## DİSCUSSİON

Rupture of the stent balloon is a rare complication of coronary interventions .
A reasonable explanation to our case may be rupture of the stent balloon during inflation .the rupture might have been due to calcific lesions , or a manifacturing defect in the balloon
Another possible scenario may be perforation of the balloon done by the operatör during insertion into the guidewire or placement into the guiding catheter .

Unexpanded or semi-expanded stent are rare complications in the era of the second -generation stents ,
İn the era of the first-generation stents these complications were more likely to develop because the stent struts were crimped to the balloon by the operatör .
However these complications may still happen and the operatör should be aware of material related complications and know how to manage them .