Transpl Int (2004) 17: 188–194
DOI 10.1007/s00147-004-0692-9

ORIGINAL ARTICLE

Hüseyin Astarcıoğlu
Sedat Karademir
Koray Atila
Özgül Sağol
Hilal Koçdor
Ahmet Çoker
İbrahim Astarcıoğlu

The effects of vascular bed expansion in steatotic rat liver graft viability

Received: 11 April 2003
Revised: 3 September 2003
Accepted: 21 October 2003
Published online: 24 April 2004
© Springer-Verlag 2004

H. Astarcıoğlu · S. Karademir
K. Atila · A. Çoker · İ. Astarcıoğlu
Department of Surgery, Dokuz Eylul University School of Medicine, Izmir, Turkey

S. Karademir (✉)
Mithatpasa cad. 860/15,
35 290 Göztepe Izmir, Turkey
E-mail: sedat.karademir@deu.edu.tr
Tel.: +90-232-4122908
Fax: +90-232-2772666

Ö. Sağol
Department of Pathology, Dokuz Eylul University School of Medicine, Izmir, Turkey

H. Koçdor
Department of Biochemistry, Dokuz Eylul University School of Medicine, Izmir, Turkey

Abstract Disturbed microcirculation caused by fat accumulation in hepatocytes has been implicated in poor graft preservation and reperfusion. The aim of this study was to investigate the effect of vascular bed expansion (VBE) during cold preservation in graft survival Moderate liver steatosis in male Wistar rats (240–280 g) was induced by choline-deficient diet. Normal, steatotic or VBE-pretreated steatotic grafts were transplanted after 1 h or 9 h of cold preservation. Graft viability was determined by 7-day survival, serum liver enzymes, plasma tumour necrosis factor (TNF)-α, interleukin (IL)-6, and malondialdehyde (MDA) levels. Post-reperfusion bile flow and liver histology were also examined. After 9 h of preservation, VBE-pretreated steatotic liver grafts were associated with significantly reduced serum liver enzyme, plasma TNF-α, IL-6, and MDA levels, as well as increased bile flow and higher survival rates compared with untreated ones. The present study shows that VBE protects fatty liver grafts from subsequent long-term cold preservation and reperfusion injury in a rat liver transplantation model.

Keywords Steatosis · Transplantation · Cold ischaemia · Vascular bed expansion

Introduction

Clinical experience suggests that steatotic liver grafts are more susceptible to cold preservation than are non-steatotic grafts, which results in primary poor or non-function (PNF) after orthotopic liver transplantation (OLT) [1, 2]. Therefore, fatty livers are not commonly transplanted. However, because of the shortage of donor organs, the discarding of fatty liver grafts as unsuitable for transplantation is of concern, and it is, therefore, important that research continues into the use of steatotic livers as safe grafts. The exact mechanism of injury has not been elucidated. One hypothesis is that in fatty livers, the sinusoids are markedly compressed and distorted by solidified fat globules during cold preservation, which results in impaired hepatic microcirculation following reperfusion [2, 3, 4, 5, 6, 7]. In addition, the inherited sinusoidal disturbance in steatotic livers may lead to inadequate perfusion with preservation solution during organ retrieval and subsequent suboptimal protection of the graft throughout the cold storage. In normal rat livers a method of vascular bed expansion (VBE), which was established during prolonged cold storage, was shown to improve subsequent graft reperfusion and function [8]. Apart from the uniform exposure of the entire graft to the UW solution, VBE was

thought to prevent sinusoidal collapse by expanding the hepatic microvasculature, which subsequently led to decreased resistance for the reperfusion blood flow [8]. We hypothesized that VBE pretreatment in steatotic rat liver grafts would attenuate hepatic injury and improve graft viability and function subsequent to revascularization.

In this study, steatotic rat liver grafts with and without VBE pretreatment were transplanted after different periods of preservation. We examined the effect of VBE on the damage induced by cold preservation of fatty liver tissue. The parameters studied included recipient survival, serum alanine transaminase (ALT), aspartate transaminase (AST), lactic dehydrogenase (LDH), plasma cytokines [tumour necrotizing factor (TNF)-α and interleukin (IL)-6], malondialdehyde (MDA), bile flow and liver histology.

Materials and method

Animals and induction of fatty livers

The study design was approved by the Dokuz Eylul University Medical School's Animal Care and Use Committee. Inbred male Wistar rats weighing 240–280 g were obtained from the Multi-disciplinary Research Unit (Izmir, Turkey). We fed donors with a choline-deficient diet (CDD) (Harlan Teklad, Madison, USA) for 4 weeks to induce moderate (30%–60%, predominantly macrovesicular) steatosis in the livers [3, 7]. The recipient and control donor rats were fed a standard laboratory diet. All animals were housed in individual cages with controlled light/dark cycles and given free access to water.

Animal preparation and surgical procedures

CDD-fed rats and control rats were used as liver donors. Rat orthotopic liver transplantations (OLTs) were performed under ether anaesthesia by use of a modified Kamada technique [9]. Following systemic heparinization, the donor liver was flushed with 10 ml of cold (4°C) UW solution through the portal vein. VBE in liver grafts was performed as described by Zeng et al. [8]. The steatotic graft was removed after it had been flushed with UW via the portal vein, and both the suprahepatic and the infrahepatic vena cava were ligated with 6-0 silk ties. Each graft was weighed, and an additional amount of UW solution (40 ml/100 g—40% of the liver weight) was infused into the graft via the portal vein, which was ligated following infusion. Immediately before transplantation all the grafts were flushed with 5 ml of cold lactated Ringer's solution. At the end of the transplantation procedure the recipient rats were given 2 ml of lactated Ringer's solution through the penile vein. No antibiotic treatment was administered. In rats selected for survival analysis, bile duct continuity was established by the use of an indwelling stent (PE 50, Baxter). In the remaining rats, PE-50 tubes were inserted into the donor bile duct for measurement of bile flow early after reperfusion.

Animal groups for experiments

The rats were divided into six groups (each group included 14 OLTs).

1. OLT after 1 h of cold preservation
   - Normal graft (N-1)
   - Steatotic graft (S-1)
   - Steatotic grafts pretreated with VBE (S + VBE-1)
2. OLT after 9 h of cold preservation
   - Normal grafts (N-9)
   - Steatotic grafts (S-9)
   - Steatotic grafts pretreated with VBE (S + VBE-9)

In each group, eight rats were assessed for 7-day survival, and six were selected for laboratory tests and bile flow analysis, only. Blood samples were taken via cardiac puncture for measurement of serum liver enzymes (ALT, AST and LDH), plasma cytokines (TNF-α and IL-6) and MDA levels at 120 min after reperfusion, following which their livers were removed for histology.

Biochemical assay of hepatic injury

To assess the damage to hepatic parenchymal cells, we measured the activities of serum AST, ALT, and LDH, using a Technicon OpeRa autoanalyzer.

Plasma TNF-α and IL-6 assay

Blood samples were collected into heparinized sterile tubes. Plasma was separated by centrifugation at 4,000 *g* for 10 min and stored at −84°C.Assays were performed in a 96-well micro-titre plate, by use of a rat TNF-α test kit (Endogen, Wolburn, Mass., USA) and rat IL-6 test kit (Endogen) based on an enzyme-linked immunosorbent assay. All samples were tested in duplicate. The plate was read on a microplate reader (Bio-Rad Novapath) at 450–595 nm, and the TNF-α and IL-6 concentrations in experimental samples were calculated from a standard curve.

Plasma MDA assay

We determined lipid peroxidation in the liver by measuring the levels of MDA, which is the end product of lipid metabolism. Blood samples were transferred

immediately to tubes on ice then centrifuged without delay at 4,000 *g* for 10 min at 4°C. The plasma obtained was stored at −80°C until required for analysis. Plasma MDA concentrations were assayed by a high-performance liquid chromatographic method that used a Shimatzu Class VP analyzer (mobile phase, 60/10 mmol/l; KH_2PO_4:40 methanol; pH 6.8; flow rate 0.5 ml/min; detector: UV-532 nm; injection volume 50 µl; C18 column, length 15 cm, pore diameter 5 µm).

Bile flow rate

Bile output was measured for 10 min after revascularization, with a PE-50 tube. Data were expressed as the length of the tube in centimetres per 10 minutes.

Histopathological examination

The removed livers were fixed in 10% formalin, routinely processed and embedded in paraffin. Sections of 5 µm thickness were stained with haematoxylin and eosin and evaluated by one pathologist (ÖS) who was blind to the study groups and laboratory data. The amount of fatty change was graded semi-quantitatively, depending on the degree of fatty infiltration: mild (< 30%), moderate (30%–60%) and severe (> 60%) [10]. We determined the extent of reperfusion injury by assessing the hepatocyte swelling, necrosis and sinusoidal neutrophilic exudation subjectively.

Table 1 Comparison of 7-day survival rates between the groups

Cold preservation time	Normal	Steatotic	Steatotic + VBE
1 h	8/8	7/8	7/8
9 h	8/8 [b,c]	0/8 [b]	6/8 [a,c]

[a]Versus steatotic, $P < 0.01$
[b]Versus normal, $P < 0.01$
[c]Versus normal, P = n.s.

Statistical analysis

Data were expressed as mean ● SEM. We used one-way analysis of variance, followed by the Kruskal–Wallis method of multiple comparisons, to compare group means. Using Fisher's exact test, we compared the animals' survival times. A probability value less than 0.05 was considered to be significant.

Results

Survival

After 1 h, preservation survival rates were similar for all the groups (Table 1). After 9 h preservation, however, there was a significant drop in survival for the group with transplanted steatotic livers [normal (N) = 8/8 vs steatotic (S) = 0/8, $P < 0.001$]. All recipients were lost within the 48 h following transplantation. However, in the treatment group, VBE resulted in a significant improvement in survival (S = 0/8 vs S + VBE = 6/8, $P < 0.01$).

Serum liver enzymes

Serum enzyme levels in the steatotic liver grafts (S and S + VBE) were significantly higher than the normal controls at each corresponding time point of cold preservation ($P < 0.05$) (Table 2). After 9 h of preservation, S + VBE-9 revealed significantly lower serum liver enzyme levels than S-9 ($P < 0.05$). After 1 h of preservation, VBE pretreatment resulted in lower serum liver enzymes levels than in the group with no treatment with steatotic grafts, but the difference did not reach statistical significance (S + VBE-1 vs S-1, P = n.s.).

Plasma TNF-α

Plasma TNF-α levels from steatotic livers were significantly higher than in controls after 1 h and 9 h of

Table 2 Serum AST, ALT, and LDH levels (mean ± SE) at 120 min of reperfusion following OLT

Parameter	Cold preservation time (h)					
	Normal		Steatotic[a]		Steatotic + VBE[a]	
	1 h	9 h	1 h[c]	9 h[b]	1 h[c]	9 h[b]
AST (IU/l)	290 ± 40	580 ± 70	1,258 ± 447	2,270 ± 684	1,154 ± 346	1,520 ± 434
ALT (IU/l)	190 ± 30	396 ± 54	954 ± 265	1,640 ± 482	876 ± 468	1,100 ± 352
LDH (IU/l)	604 ± 46	974 ± 118	4,150 ± 894	8,572 ± 1,168	3,446 ± 338	5,082 ± 832

[a]Versus normal, $P < 0.05$
[b]Steatotic vs steatotic + VBE, $P < 0.05$
[c]Steatotic vs steatotic + VBE, P = n.s.

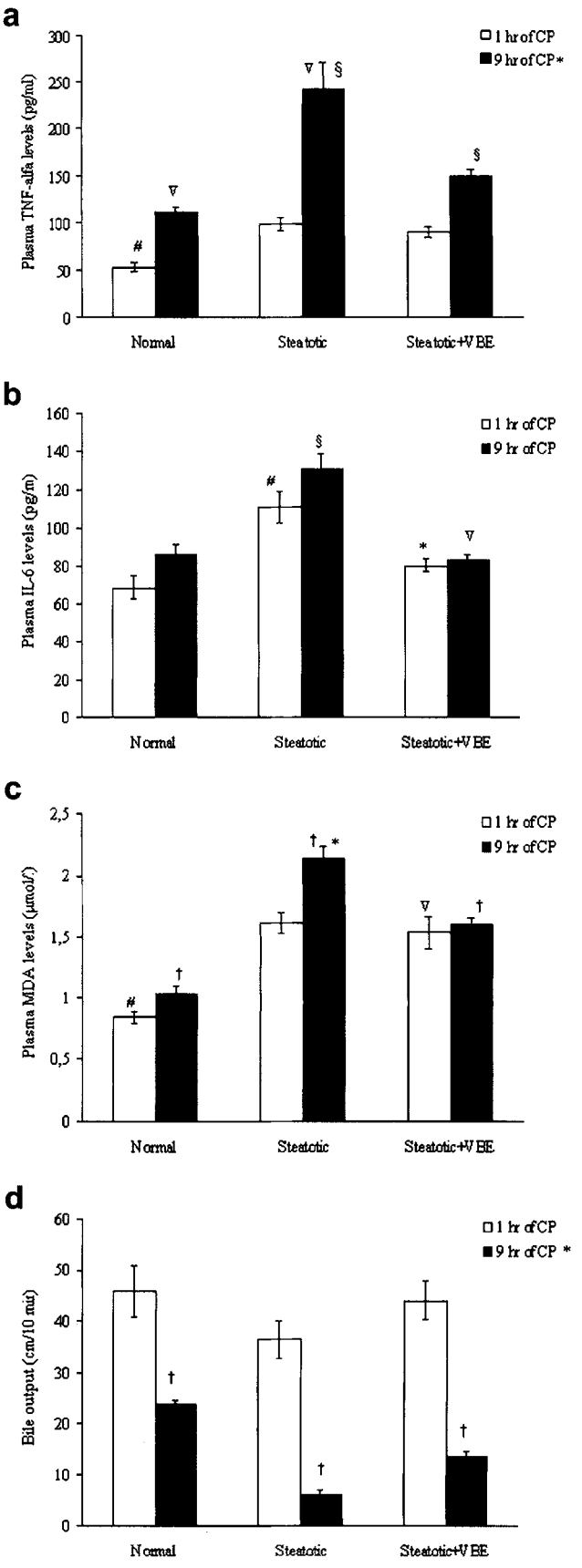

Fig. 1a–d Post-reperfusion plasma levels of (**a**) TNF-α, (**b**) IL-6, (**c**) malondialdehyde, and (**d**) bile flow in rats that received VBE-treated or untreated steatotic liver grafts after long-term (9 h) or short-term (1 h) preservation. Control groups received normal livers. Bile output was measured after revascularization by use of a PE-50 tube for 10 min. Bile flow data are expressed as length of bile in tube in centimetres per 10 minutes. *CP* cold preservation

preservation ($P<0.01$). Although VBE treatment resulted in a significant reduction in TNF-α levels at both preservation times, the levels were still significantly higher than in controls (Fig. 1a). After 9 h of preservation, S+VBE-9 yielded significantly lower levels of plasma TNF-α than S-9 (150 ± 6.8 pg/ml and 243 ± 29 pg/ml, respectively, $P<0.01$). However, VBE treatment did not result in a significant difference between the groups after short-term preservation (S-1 vs S+VBE-1, P=n.s.). For all study groups there was a significantly elevated plasma TNF-α level at 9 h compared with 1 h ($P<0.01$) (Fig. 1a).

Plasma IL-6

Plasma IL-6 levels in the steatotic groups (S-1 and S-9), were significantly higher than in the controls (N-1 and N-9) ($P<0.01$). After VBE pretreatment (S+VBE), plasma IL-6 levels obtained from the steatotic grafts were significantly decreased and close to the levels of normal controls at corresponding time points (Fig. 1b).

Plasma MDA

After 1 h of preservation, there was a significantly higher plasma MDA level in both steatotic groups (S-1 and S+VBE-1) compared with the control group (N-1) ($P<0.01$) (Fig. 1c). However, no statistical difference was observed between the S-1 and S+VBE-1 groups (P=n.s.). For the groups subjected to 9 h of preservation, MDA levels in the control, steatotic and VBE-treated steatotic groups were 1.03 ± 0.07 µmol/l, 2.14 ± 0.1 µmol/l, and 1.6 ± 0.06 µmol/l ($P<0.01$) (Fig. 1c).

Bile output

After 1 h of preservation there was no significant difference in bile flow rates between the three groups (P=n.s.) (Fig. 1d). In contrast, after 9 h of preservation post-reperfusion, bile secretion in the groups of N, S and S+VBE were 23.8 ± 1.8 cm/10 min, 6.2 ± 0.5 cm/10 min, and 13.7 ± 0.9 cm/10 min, respectively, which was statistically significant ($P<0.01$). For all groups, long-term preservation resulted in significantly less bile

secretion than short-term preservation ($P < 0.01$) (Fig. 1d).

Histopathology

Liver grafts from CDD-fed rats demonstrated a moderate amount (30%–60%) of fatty infiltration, which was primarily macrovesicular (Fig. 2). Compared with normal livers, after 120 min of reperfusion, steatotic liver grafts revealed more prominent parenchymal injury, seen as hepatocyte swelling, spotty necrosis of hepatocytes with neutrophilic or mononuclear cell infiltrates and neutrophils within the sinusoids. However, on light microscopy no significant difference in terms of necroinflammatory changes was observed between the treated and untreated steatotic grafts, after either 1 h or 9 h of preservation (Fig. 3). Furthermore, there was no difference in the histology of the livers, as observed after 1 h or 9 h of preservation, in any of the groups.

Discussion

The success of liver transplantation has dramatically increased during the past 15 years, and OLT has become the standard treatment for patients with a variety of end-stage liver disease. However, donor organ shortage remains a serious problem. Even in centres with a high throughput, 10% to 30% of transplant candidates die while awaiting a donor organ [11]. In order for the increasing demand to be met, marginal donor livers, especially those with steatosis, have been used. Mildly steatotic (up to 30%) donor livers are successfully transplanted, with patient and graft survival similar to non-steatotic ones [12], whereas severely steatotic (>60%) livers are almost always discarded [13]. The outcome with moderately steatotic (30%–60%) livers, however, is associated with increased tendency for the development of severe ischaemic injury as well as PNF [1, 2]. This observation has made them unsuitable for elective OLT, and, consequently, approximately 10% of recovered donor livers are rejected due to hepatic steatosis [2]. It is, therefore, useful for us to investigate methods of using steatotic livers as safe grafts.

In steatotic livers, the total hepatic blood flow is reduced by half [3, 4, 5, 14, 15], and the flow in the hepatic microcirculation falls to approximately 16% of that in normal controls [5]. One possible explanation for this might be that only a proportion of the liver blood flow is passing through the sinusoids, while the rest is being shunted. The narrowed and distorted sinusoidal architecture, caused by fat accumulation, has been implicated in flow reduction. In liver transplantation, inherently high microvascular resistance and markedly reduced flow in the sinusoidal lumen of fatty livers might lead to impaired perfusion with cold preservation solution during organ retrieval [4, 5]. Thus, these grafts will be subject to the consequences of inadequate distribution and exposure of preservation solution. Blebs and solidified fat globules released into the sinusoidal space at the time of hypothermia will further compromise the microvascular space [4, 5, 6, 7].

UW is the most commonly used preservation solution, and its favourable effect has not been evident in fatty livers compared with the normal ones [3, 16]. However, with conventional static storage techniques, even in normal livers, organ preservation solution does not completely fill the microvasculature or remain there [17, 18]. The fluid can freely drain out of open vessels and create a suboptimum preservation environment, especially for lining endothelial cells [6, 19]. The resulting

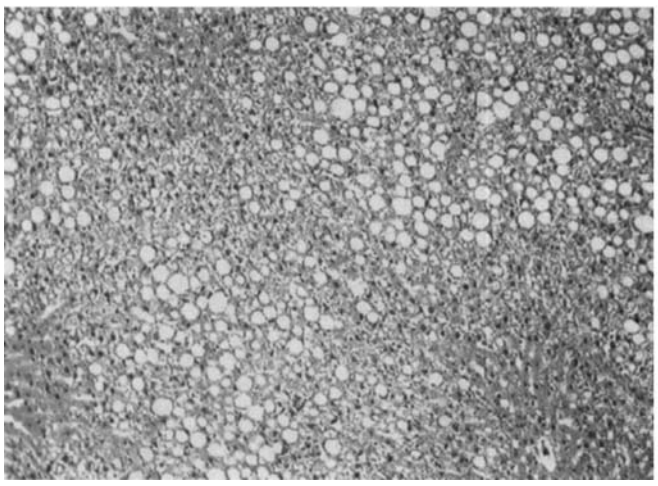

Fig. 2 Moderate amount of macrovesicular steatosis caused by CDD diet. (H&E; original magnification ×40)

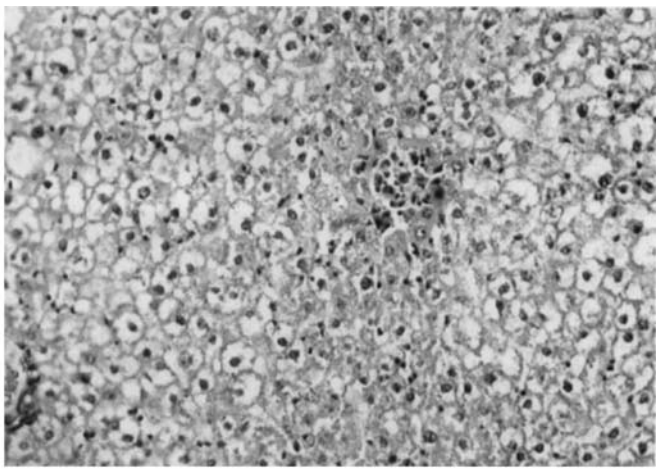

Fig. 3 Prominent hepatocyte swelling and a focus of cell necrosis accompanying fatty changes after 120 min of reperfusion (H&E; original magnification ×100)

increased cold ischaemic damage may compound the exaggerated reperfusion injury associated with steatosis.

In steatotic livers several factors, including fat globules, fibrin microthrombi and cellular elements in the blood, may cause microcirculatory impairment following reperfusion [4, 20]. Furthermore, the ability to generate ATP is decreased in steatotic livers [3, 21, 22]. Poor recovery of energy metabolism results in loss of hepatocyte integrity and cell death, which is predominantly by necrosis [23]. As the lipids released in the sinusoidal space are used as substrate for lipid peroxidation, increased formation of free radicals results in further disruption of the microcirculation [24, 25]. The production of pro-inflammatory mediators such as TNF-α and IL-6, and free radicals by activated Kupffer cells may cause a decline in the antioxidants and cellular energy stores of the fatty liver [4, 26]. Taken together, multiple mechanisms are potentially involved in the impaired tolerance to ischaemic injury of steatotic livers. Recently, ischaemic preconditioning, a brief period of ischaemia prior to a prolonged ischaemic insult, was found to control lipid peroxidation, hepatic microcirculation failure and neutrophil accumulation, reducing the subsequent hepatic injury in fatty livers [27]. However, currently no protective strategy is available in the clinical setting.

In rats, Zeng et al. have established a method of VBE during cold storage by infusing UW solution via the portal vein, followed by occlusion of all vessels to trap the fluid throughout the intrahepatic vasculature [8]. VBE has been shown to increase the resistance of non-steatotic donor livers to prolonged cold ischaemic injury (up to 30 h) and to maintain uniform distribution of portal blood after reperfusion. Aside from the uniform exposure of the entire graft to the preservation solution, VBE is thought to facilitate reperfusion by avoiding sinusoidal collapse during static preservation. Our study assesses whether VBE, demonstrated to be effective in normal livers, could also confer protection in the presence of steatosis.

In the majority of fatty donor livers the fat globules are macrovesicular. Microvesicular steatosis is less common in liver donors. In contrast to the use of livers with macrovesicular steatosis, the use of donor livers with even severe microvesicular steatosis has been shown to be associated with graft survival rates similar to those of non-steatotic grafts [28]. In this study, the donor rats were fed a choline-deficient diet for 4 weeks, which has been shown to result in fatty livers that were predominantly macrovesicular in nature [3, 7]. According to criteria described above, the steatotic livers in this series would be classified as moderate [10].

The present study verified the clinical observation that steatotic grafts are more susceptible to cold ischaemic injury than normal ones. After the livers had undergone 1 h of preservation, the outcome for recipients transplanted with either normal or steatotic grafts was similar. In contrast, 9 h of preservation resulted in a significant reduction in the post-transplant viability of the steatotic graft. We found that the survival of recipients transplanted with steatotic livers declined markedly in correlation with the duration of preservation. After 9 h of preservation, no recipient rat with a steatotic graft survived. However, VBE pretreatment appeared to be beneficial by all outcome indices. The most important observation was that, with VBE, survival was possible with moderately steatotic liver grafts, even after 9 h of preservation. Similarly, serum liver enzyme levels were also markedly improved after VBE pretreatment. Activation of Kupffer cells, during cold storage and subsequent reperfusion, was indicated by the increased release of TNF-α [29]. After 120 min of reperfusion, TNF-α and IL-6 levels were significantly increased in steatotic livers compared with the controls. However, both pro-inflammatory cytokines were decreased in those livers subjected to VBE pretreatment. MDA analysis, a marker of lipid membrane integrity, also directly correlated with graft function and survival. High plasma MDA levels, demonstrated with steatotic grafts, were markedly decreased after VBE pretreatment. In addition, we evaluated the amount of post-reperfusion bile flow, which has been shown to correlate with the ATP levels in hepatocytes after ischaemia and reperfusion injury [30]. In our series, the markedly impaired bile flow rates in steatotic grafts were found to improve following VBE pretreatment.

VBE pretreatment appeared to be beneficial for steatotic donor livers transplanted after prolonged, rather than short, preservation periods. This imitates the clinical situation where 9 h of cold ischaemia is common practice, whereas transplantation after 1 h is less likely.

Histopathologically, after 120 min of reperfusion, no significant difference in terms of parenchymal necro-inflammatory changes were found on light microscopy, between the VBE-pretreated and untreated steatotic livers at corresponding preservation times. This might be explained by insufficient duration of reperfusion to induce parenchymal injury to an extent such that necro-inflammatory differences between the treated and untreated steatotic livers became evident.

In conclusion, our results show that in steatotic rat liver grafts, VBE might attenuate the damage induced by prolonged cold preservation and reperfusion, resulting in improved early graft function and subsequent graft survival. As the number of available liver grafts is limited in clinical practice, VBE might be a possible method of improving the safety of steatotic livers.

Acknowledgements We thank Prof. Gül Güner and Memduh Bülbül, Ph.D. [Dept. of Biochemistry, Research Laboratory (AR-LAB)] for their technical assistance in high-performance liquid chromatographic analysis.

References

1. Adam R, Reynes M, Johann M, et al. The outcome of steatotic grafts in liver transplantation. Transplant Proc 1991; 23:1538.
2. Todo S, Demetris AJ, Makowka L, et al. Primary nonfunction of hepatic allografts with preexisting fatty infiltration. Transplantation 1989; 47:903.
3. Hayashi M, Tokunaga Y, Fujita T, Tanaka K, Yamaoka Y, Ozawa K. The effects of cold preservation on steatotic grafts viability in rat liver transplantation. Transplantation 1993; 56:282.
4. Teramoto K, Bowers JL, Kruskal JB, Clouse M. Hepatic microcirculatory changes after reperfusion in fatty and normal liver transplantation in the rat. Transplantation 1993; 56:1076.
5. Seifalian AM, Piasecki C, Agarwal A, Davidson BR. The effect of graded steatosis on flow in the hepatic parenchymal microcirculation. Transplantation 1999; 68:780.
6. Fukumori T, Ohkohchi N, Tsukamoto S, Satomi S. The mechanism of injury in a steatotic liver graft during cold preservation. Transplantation 1999; 67:195.
7. Teramoto K, Bowers JL, Khettry U, Palombo JD, Clouse ME. A rat fatty liver transplant model. Transplantation 1993; 55:737.
8. Zeng QH, Todo S, Murase N, et al. Modified simple cold storage of rat livers with UW solution. Transplantation 1994; 58:408.
9. Kamada N, Calne RY. A surgical experience with five hundred thirty liver transplants in the rat. Surgery 1983; 93:64.
10. D'Allesandro A, Kalayoglu M, Sollinger H, et al. The predictive value of donor liver biopsies for the development of primary nonfunction after orthotopic liver transplantation. Transplantation 1991; 51:157.
11. Trevisani F, Colantoni A, Caraceni P, Van Thiel DH. The use of donor fatty liver for liver transplantation: a challenge or a quagmire? J Hepatology 1996; 24:114.
12. Mor E, Klintmalm GB, Gonwa TA, et al. The use of marginal donors for liver transplantation. Transplantation 1992; 53:383.
13. Markin RS, Wisecarver JL, Radio SJ, et al. Frozen section evaluation of donor livers before transplantation. Transplantation 1993; 56:1403.
14. Ohara K. Study of microcirculatory changes in experimental dietary fatty liver J Med Hokkaido 1989; 64:177.
15. Hakamada K, Sasaki M, Takahashi K, Umehara Y, Konn M. Sinusoidal flow block after warm ischemia in rats with diet-induced fatty liver. J Surg Res 1997; 70:12.
16. Belzer FO, Southard JH. Principles of solid-organ preservation by cold storage. Transplantation 1988; 45:673.
17. Caldwell-Kenkel LC, Currin RT, Tanaka Y, Thurman RG, Lemasters JJ. Reperfusion injury to endothelial cells following cold ischemic storage of rat livers. Hepatology 1989; 10:292.
18. Momii S, Koga A. Time-related morphological changes in cold-stored rat livers. A comparison of Euro-Collins solution with UW solution. Transplantation 1990; 50:745.
19. Thurman RG, Bunzendahl H, LeMasters JL. Role of sinusoidal lining cell in hepatic reperfusion injury following cold preservation and transplantation. Semin Liver Dis 1993; 13:93.
20. Nakano H, Nagasaki H, Yoshida K, et al. N-acetylcysteine and anti-ICAM-1 monoclonal antibody reduce ischemia-reperfusion injury of the steatotic rat liver. Transplant Proc 1998; 30:3763.
21. Fukumori T, Ohkohchi N, Tsukamoto S, Satomi S. Why is fatty liver unsuitable for transplantation? Deterioration of mitochondrial ATP synthesis and sinusoidal structure during cold preservation of a liver with steatosis. Transplant Proc 1997; 29:412.
22. Hui AM, Kawasaki S, Makuuchi M, Nakayama J, Ikegami T, Miyagawa S. Liver injury following normothermic ischemia in steatotic rat liver. Hepatology 1994; 20:1287.
23. Selzner M, Rudiger HA, Sindram D, Madden J, Clavien PA. Mechanisms of ischemic injury are different in the steatotic and normal rat liver. Hepatology 2000; 32:1280.
24. Letteron P, Fromenty B, Terris B, Degott C, Pessayre D. Acute and chronic hepatic steatosis lead to in vivo lipid peroxidation in mice. J Hepatol 1996; 24:200.
25. Takahashi K, Hakamada K, Totsuka E, Umehara Y, Sasaki M. Warm ischemia and reperfusion injury in diet-induced canine fatty livers. Transplantation 2000; 69:2028.
26. Yang SQ, Lin HZ, Lane MD, Clemens M, Diehl AM. Obesity increases sensitivity to endotoxin liver injury: implications for the pathogenesis of steatohepatitis. Proc Natl Acad Sci U S A 1997; 94:2557.
27. Serafin A, Rosello-Catafau J, Prats N, Xaus C, Gelpi E, Peralta C. Ischemic preconditioning increases the tolerance of fatty liver to hepatic ischemia-reperfusion injury in the rat. Am J Pathol 2002; 161:587.
28. Fishbein TM, Fiel MI, Emre S, et al. Use of livers with microvesicular fat safely expands the donor pool. Transplantation 1997; 64:248.
29. Arii S, Monden K, Adachi Y, et al. Pathogenic role of Kupffer cell activation in the reperfusion injury of cold-preserved liver. Transplantation 1994; 58:1072.
30. Kamiike W, Nakahara M, Nakao K, et al. Correlation between cellular ATP level and bile excretion in the rat liver. Transplantation 1985; 39:50.