doi:10.1093/brain/awx222 BRAIN 2017: 140; 1–5 | e65

BRAIN
A JOURNAL OF NEUROLOGY

LETTER TO THE EDITOR

Biallelic *MCM3AP* mutations cause Charcot-Marie-Tooth neuropathy with variable clinical presentation

Mert Karakaya,[1,*] Neda Mazaheri,[2,3,*] Ipek Polat,[4,*] Diana Bharucha-Goebel,[5,6,*] Sandra Donkervoort,[5] Reza Maroofian,[7,8] Gholamreza Shariati,[3,9] Irmgard Hoelker,[1] Kristin Monaghan,[10] Sara Winchester,[11] Robert Zori,[12] Hamid Galehdari,[2] Carsten G. Bönnemann,[5] Uluc Yis[4] and Brunhilde Wirth[1]

*These authors contributed equally to this work.

1 Institute of Human Genetics, Center for Molecular Medicine Cologne, Institute of Genetics, and Center for Rare Diseases Cologne, University of Cologne, Cologne, Germany
2 Department of Genetics, Faculty of Science, Shahid Chamran University of Ahvaz, Ahvaz, Iran
3 Narges Medical Genetics and Prenatal Diagnosis Laboratory, East Mihan Ave., Kianpars, Ahvaz, Iran
4 Dokuz Eylül University, Department of Pediatric Neurology, Izmir, Turkey
5 Neuromuscular and Neurogenetic Disorders of Childhood Section, National Institute of Neurological Disorders and Stroke, National Institutes of Health, Bethesda, USA
6 Division of Neurology, Children's National Health System, Washington, DC, USA
7 Genetics and Molecular Cell Sciences Research Centre, St George's University of London, Cranmer, 16 Terrace, London, UK
8 Medical Research, RILD Welcome Wolfson Centre, Exeter Medical School, Royal Devon and Exeter NHS Foundation Trust, Exeter, UK
9 Department of Medical Genetics, Faculty of Medicine, Ahvaz Jundishapur University of Medical Sciences, Ahvaz, Iran
10 GeneDx, Gaithersburg, MD, USA
11 Child Neurology Center of Northwest Florida, Pensacola, FL, USA
12 Division of Genetics and Metabolism, University of Florida, Gainesville, FL, USA

Correspondence to: Professor Dr. Brunhilde Wirth
Institute of Human Genetics
University of Cologne
Kerpener Str. 34
50931 Cologne, Germany
E-mail: brunhilde.wirth@uk-koeln.de

Sir,

With great interest, we read the article by Ylikallio *et al.* (2017) presenting the first cases with functional molecular analysis of *MCM3AP*-related Charcot-Marie-Tooth neuropathy (CMT) and mild intellectual disability. *MCM3AP* has first been proposed as a candidate disease-causing gene for intellectual disability, polyneuropathy and ptosis (Schuurs-Hoeijmakers *et al.*, 2013). Minichromosome maintenance complex component 3 associated protein (*MCM3AP*, OMIM 603294) functions as an acetyltransferase that acetylates the replication protein, MCM3, and translocates MCM3 into the nuclei from cytoplasm (Takei *et al.*, 2001). Through the interaction with MCM3, MCM3AP inhibits the cell cycle progression to control the DNA replication occurring only once per cell cycle (Takei *et al.*, 2002). Germinal center-associated nuclear protein (GANP) is an alternatively splice variant of *MCM3AP*, with a carboxyl-domain that is shared with MCM3AP protein (Abe *et al.*, 2000). In addition to this shared carboxyl-terminal domain, GANP is composed of four more functional domains, FG (phenylalanine-glycine) repeat, DNA primase, Sac3 (suppressor of actin) and CID (Cdc31 interaction domain) (Ylikallio *et al.*, 2017). The Sac3 domain is responsible for exporting mRNAs to the cytoplasm through the nuclear pores (Wickramasinghe

Advance Access publication September 13, 2017
© The Author (2017). Published by Oxford University Press on behalf of the Guarantors of Brain. All rights reserved.
For Permissions, please email: journals.permissions@oup.com

Downloaded from https://academic.oup.com/brain/article/140/10/e65/4157881 by Dokuz Eylul University Library (DEU) user on 02 September 2021

et al., 2010). A depletion of GANP blocks mRNA export and leads to accumulation of mRNA in punctate foci within the nucleus (Wickramasinghe *et al.*, 2010). Decreased expression of GANP has been shown to be involved in neoplasms originating in the CNS (Ohta *et al.*, 2009).

We report four affected individuals with hereditary sensorymotor polyneuropathy and distal weakness, with or without mild intellectual disability, strabismus and/or ophthalmoparesis. Written informed consent for next-generation sequencing and photos of the affected individuals were obtained from the parents and the affected individual under the respective study in Germany, UK and US. The collaboration among three centres was established through GeneMatcher (Sobreira *et al.*, 2015).

In Family A (Table 1), the 8-year-old female from a consanguineous family with Kurdish origin has been followed since 3 years of age for delay in motor development, gait difficulty, and ophthalmoparesis. She was able to sit independently at 2.5 years of age, and walk without support at 4 years of age. Neuromuscular examination at 6 years of age showed distal muscle atrophy and weakness at both upper and lower extremities, absent deep tendon reflexes, scoliosis, strabismus and ophthalmoparesis (Fig. 1D and Supplementary Video 1). At 8 years of age, she learnt reading at school with slight delay; however, her fine motor skills were still delayed, as she was unable to hold a glass with one hand (Supplementary Video 1). Cranial MRI scans at 4 years of age was normal. Nerve conduction studies revealed axonal sensorymotor neuropathy (data not shown).

After a negative MLPA analysis of the *PMP22* gene, Mendeliome sequencing was performed, which enables targeted sequencing of 4813 genes with known clinical phenotypes and Mendelian inheritance (TruSight One Sequencing Panel, Illumina). Mendeliome sequencing revealed a homozygous missense variant, c.2633G>A (p.Arg878His), in *MCM3AP* (NM_003906.3) as the primary candidate mutation (Fig. 1A and K). The variant was not present in Greater Middle East Variome Project (GME Variome) and it was only observed in heterozygous state in 3 of 243 616 alleles in the Genome Aggregation Database (GnomAD).

In Family B (Table 1), we report two affected sisters aged 30 and 27 years old from a consanguineous Iranian family. Both sisters had normal developmental milestones. At the age of 10–13 years, both sisters slowly began to show weakness in upper and lower extremities and absent reflexes with bilateral thenar atrophy, mild wasting of the intrinsic hand muscles and distal spinal muscular atrophy resulting in hand weakness, writing difficulty and claw hands. Both displayed bilateral pes cavus with Achilles tendon shortness or rigidity, developed difficulty walking, frequent falls and abnormal gait (Fig. 1E–G and Supplementary Video 1). They could not climb stairs without support and lost the ability to run. Electrophysiological studies showed low motor nerve conduction velocities (NCV) of upper and lower extremities in both sisters (ranged from 32 to 36 m/s in the median nerve) and normal sensory nerve conduction of upper and lower extremities. Brain and thoracic spine MRI of the older sister was normal at the age of 19. They had no auditory, visual and cognition impairment.

Whole exome sequencing (WES) in two affected sisters revealed a homozygous missense variant, c.2851T>C (p.Ser951Pro) in the *MCM3AP* gene (Fig. 1B and K) residing within a shared ~20 Mb run of homozygosity. The variant segregated fully with the phenotype and it was not found in GME Variome Project or GnomAD database, or in ~600 in-house control exomes.

In Family C (Table 1), we report on a 13-year-old female from non-consanguineous parents. There was a history of decreased foetal movements, but no other immediate neonatal concerns. The patient had delayed acquisition of head control and motor milestones from within the first year of life, and a history of global developmental delays. She sat independently at 12 months, pulled to stand at 11 months, walked at 3 years old, and never ran well. Since 11 years old, she experienced progression of her foot drop, finger/wrist drop (Fig. 1H) and increasing difficulty with independent ambulation. She had fine motor delay and speech delays. She has mild intellectual disability (Full Scale IQ 63). She has developed kyphosis, high arched feet, and has several lipomas in her lower extremities (Fig. 1I and J). Brain MRI was essentially normal. EMG/NCS showed axonal sensorimotor neuropathy. Sural nerve biopsy (at 12 years old) showed mild chronic axonal neuropathy with mild loss of large diameter axons and minimal small fibre loss (data not shown). WES revealed mutations in the *MCM3AP* gene: maternally inherited c.4360_4377dup18 (p.Ser1454_Leu1459dup) and *de novo* c.5410C>T (p.Gln1804*) (Fig. 1C and K). The variants were not found in GnomAD database.

In silico CADD analysis of the two missense and two truncating *MCM3AP* variants revealed a high-deleterious score (C-score: Arg878His: 35, Ser951Pro: 29.6, Gln1804*: 50 and Ser1454_Leu1459dup: 35). The location of missense substitutions (Arg878 and Ser951) are located in Sac3 homology domain and fully conserved among the orthologues, as well as the other homozygous mutation reported by Ylikallio *et al.* (2017)

Our results confirm the pathogenicity of biallelic mutations in the GANP protein encoded by the *MCM3AP* gene. Affected individuals in Families A and B have homozygous missense mutations in the Sac3 domain resulting in a slowly progressive phenotype and so far no loss of ambulation. However, we cannot arrive at a clear genotype–phenotype correlation as a similar homozygous missense mutation (Met762Thr) in the Turkish patient in Ylikallio's report, resulting in loss of independent ambulation at 10 years of age, hence signifying a more severe course. In addition, none of the siblings in Family B has intellectual disability or ophthalmoparesis, again complicating a direct correlation of mutation type and clinical severity.

Downloaded from https://academic.oup.com/brain/article/140/10/e65/4157881 by Dokuz Eylul University Library (DEU) user on 02 September 2021

Table 1 Summary of clinical features of the patients

	Subject			
	A-III.2	**B-III.1**	**B-III.2**	**C-III.1**
MCM3AP mutation, protein	Arg878His	Ser951Pro	Ser951Pro	Gln1804* Ser1454_Leu1459dup
Gender	F	F	F	F
Ethnicity	Kurdish	Iranian	Iranian	Irish/French
Consanguinity	Yes	Yes	Yes	No
Age at evaluation, years	8	30	27	13
Age at onset, years	3	13	10	Birth
Eye symptoms	Ophthalmoplegia, strabismus	Normal	Normal	Intermittent strabismus, myopic astigmatism
Hearing	Normal	Normal	Normal	Asymmetric bilateral conductive hearing loss
Cognition/language	Mild intellectual delay	Normal/stuttering since early childhood	Normal	Mild intellectual disability (FSIQ 63); Speech and language delays
Motor development	Delayed	Normal	Normal	Delayed
Maximum motor activity	Ambulant, difficulty in writing and holding glass, gait problems, difficulty in climbing stairs	Difficulty in writing, abnormal gait, climbing stairs with support, inability to run	Difficulty in writing, abnormal gait, climbing stairs with support, inability to run	Ambulant (±walker), gait problems; never ran
Weakness/atrophy	Upper and lower distal extremity muscles, bilateral thenar atrophy	Weakness in upper and lower extremities, severe involvement of upper extremities, bilateral thenar atrophy, distal spinal muscular atrophy	Weakness in upper and lower extremities, severe involvement of upper extremities, bilateral thenar atrophy, distal spinal muscular atrophy	Distal upper and lower extremity muscles
Musculoskeletal deformities	Scoliosis	Bilateral pes cavus deformity, claw hands	Bilateral pes cavus deformity, claw hands	Kyphosis, high arches, asymmetric axillary folding, lipomas
Deep tendon reflexes	Reduced	Reduced	Reduced	Reduced
EMG	Neurogenic	Neurogenic	Neurogenic	Neurogenic
Nerve conduction studies	Axonal sensorymotor neuropathy	motor involvement	"Mild" Axonal, motor involvement	Axonal sensorymotor neuropathy
Brain MRI	Normal	Normal	N/A	Minimal colpocephaly
Spinal MRI	N/A	Normal (thoracic spine)	N/A	N/A
Progression	Slowly progressive	Slowly progressive (more rapid in the first 5 years)	Slowly progressive (more rapid in the first 5 years)	Moderate (more rapid since age 11 years)

FSIQ = Full Scale Intelligence Quotient.

Downloaded from https://academic.oup.com/brain/article/140/10/e65/4157881 by Dokuz Eylul University Library (DEU) user on 02 September 2021

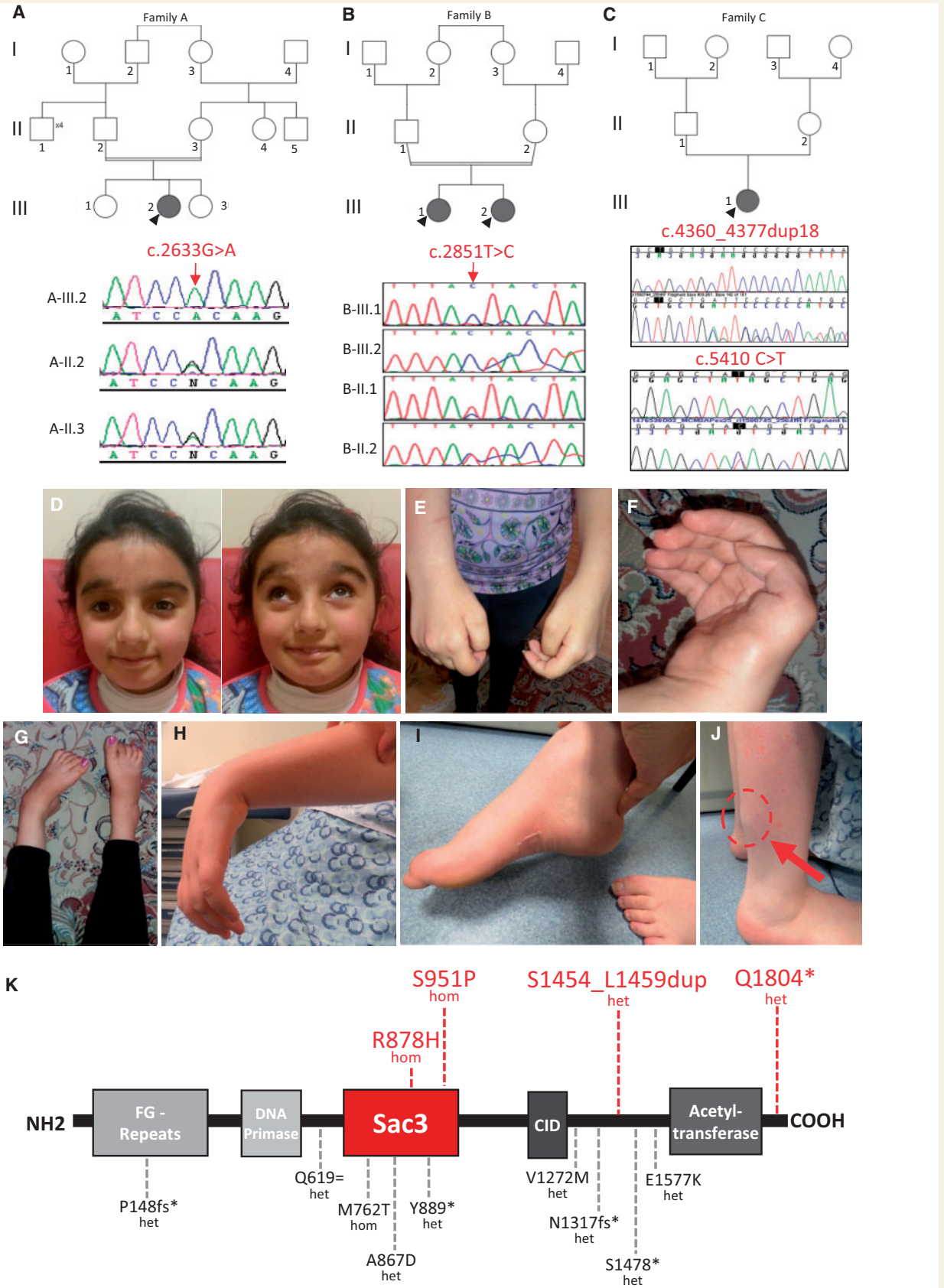

Figure 1 Pedigree of the families, clinical hallmarks and identified mutations. (**A–C**) Pedigrees and Sanger sequencing results of three unrelated families with homozygous missense mutations (**A** and **B**) and biallelic truncating mutations (**C**) in *MCM3AP*. (**D**) Sequential photos from the affected individual in Family A illustrate the ophthalmoparesis and strabismus. (**E–G**) Distal muscle atrophy and subsequent distal contractures in the affected individual (B-III.2) in Family B. (**H–J**) Wrist and finger drop (**H**), high arch and hammertoe deformity (**I**) in the affected individual in Family C. Red arrow indicates one of several lipomas seen in the lower extremities (**J**) of this affected individual. (**K**) GANP protein structure and mutations identified: homozygous missense mutations in the Sac3 domain, and biallelic truncating mutations proximal to the acetyltransferase domain and the carboxyl-terminal (*top*, red). Other recessive mutations identified by Ylikallio *et al.* (*bottom*, black) that disperse through the different domains of the protein.

Downloaded from https://academic.oup.com/brain/article/140/10/e65/4157881 by Dokuz Eylul University Library (DEU) user on 02 September 2021

According to previous studies, insufficient mRNA export and nuclear accumulation of mRNA underpin the cellular degeneration of GANP-depleted cells (Wickramasinghe *et al.*, 2010). In particular to motor neuron degeneration, the role of Sac3 in actin cytoskeleton and microtubule function (Bauer and Kolling, 1996) should be also considered as a possible pathomechanism in the development of motor neuron degeneration. Apart from toxic effect of accumulated mRNA in the nucleus, no other pathomechanism has been put forward in the development of sensory motor degeneration.

Web resources

The URLs for data presented herein are as follows:
NHLBI Exome Sequencing Project (ESP); http://evs.gs.washington.edu/EVS/
Online Mendelian Inheritance in Man; http://www.ncbi.nlm.nih.gov/Omim
PubMed; http://www.ncbi.nlm.nih.gov/pubmed/
GeneCards; http://www.genecards.org/
Gene Matcher, http://www.genematcher.org
The 1000 Genomes Browser; http://browser.1000genomes.org/index.html
The Greater Middle East Variome Project; http://igm.ucsd.edu/gme/index.php
Genome Aggregation Database; http://gnomad.broadinstitute.org/
UCSC Human Genome Database; http://www.genome.ucsc.edu
Combined Annotation Dependent Depletion (CADD); http://cadd.gs.washington.edu/
NeurOmics: http://rd-neuromics.eu/

Acknowledgements

We would like to thank to the family members described herein for participating in this study. We thank to Dr. Suman Ghosh and Dr. Peter Kang; Division of Neurology; University of Florida for the support at clinical follow up, diagnostics and the genetic analysis.

Funding

The research leading to these results has received funding from the European Community's Seventh Framework Programme (FP7/2007-2013) under grant agreement n° 2012-305121 "Integrated European –omics research project for diagnosis and therapy in rare neuromuscular and neurodegenerative diseases (NEUROMICS)".

Supplementary material

Supplementary material is available at *Brain* online.

References

Abe E, Kuwahara K, Yoshida M, Suzuki M, Terasaki H, Matsuo Y, et al. Structure, expression, and chromosomal localization of the human gene encoding a germinal center-associated nuclear protein (GANP) that associates with MCM3 involved in the initiation of DNA replication. Gene 2000; 255: 219–27.

Bauer A, Kolling R. The SAC3 gene encodes a nuclear protein required for normal progression of mitosis. J Cell Sci 1996; 109 (Pt 6): 1575–83.

Ohta K, Kuwahara K, Zhang Z, Makino K, Komohara Y, Nakamura H, et al. Decreased expression of germinal center-associated nuclear protein is involved in chromosomal instability in malignant gliomas. Cancer Sci 2009; 100: 2069–76.

Schuurs-Hoeijmakers JH, Vulto-van Silfhout AT, Vissers LE, van de Vondervoort II, van Bon BW, de Ligt J, et al. Identification of pathogenic gene variants in small families with intellectually disabled siblings by exome sequencing. J Med Genet 2013; 50: 802–11.

Sobreira N, Schiettecatte F, Valle D, Hamosh A. GeneMatcher: a matching tool for connecting investigators with an interest in the same gene. Hum Mutat 2015; 36: 928–30.

Takei Y, Assenberg M, Tsujimoto G, Laskey R. The MCM3 acetylase MCM3AP inhibits initiation, but not elongation, of DNA replication via interaction with MCM3. J Biol Chem 2002; 277: 43121–5.

Takei Y, Swietlik M, Tanoue A, Tsujimoto G, Kouzarides T, Laskey R. MCM3AP, a novel acetyltransferase that acetylates replication protein MCM3. EMBO Rep 2001; 2: 119–23.

Wickramasinghe VO, McMurtrie PI, Mills AD, Takei Y, Penrhyn-Lowe S, Amagase Y, et al. mRNA export from mammalian cell nuclei is dependent on GANP. Curr Biol 2010; 20: 25–31.

Ylikallio E, Woldegebriel R, Tumiati M, Isohanni P, Ryan MM, Stark Z, et al. MCM3AP in recessive Charcot-Marie-Tooth neuropathy and mild intellectual disability. Brain 2017; 140: 2093–103.

Downloaded from https://academic.oup.com/brain/article/140/10/e65/4157881 by Dokuz Eylul University Library (DEU) user on 02 September 2021