The healing effect of topical tea tree oil on pressure ulcers in a rat model

Objective: The effects of topical tea tree oil (TTO) on the healing of pressure ulcers (PUs) in an animal model was evaluated.
Method: To induce PUs, ischaemia–reperfusion cycles were performed by the external application of magnetic plates, with an ischaemic period of eight hours and a reperfusion period of 16 hours. Male and female Wistar rats were divided into three equally sized groups (n=20): one group received topical glycerin twice daily, another group received topical 10% (volume/volume (v/v)) TTO in glycerin twice daily; and the remaining group was untreated. The animals were assessed after one, four, seven and 14 cycles of ischaemia–reperfusion by thermal camera imaging, and then euthanised and sampled to investigate the degree of inflammation, collagen synthesis and apoptosis in the PUs.
Results: Although topical glycerin alone suppressed local inflammation and apoptosis, this suppressive effect was accentuated at all timepoints by the application of topical TTO + glycerin. Similarly, an increase in collagen synthesis was observed in the glycerin group and this was accentuated by TTO at all timepoints. Parallel to the histological findings, the local temperature had decreased significantly on days 4 and 7 for both treatment groups (glycerin and TTO + glycerin).
Conclusion: In this study, treatment with 10% (v/v) TTO in glycerin effectively suppressed skin inflammation and apoptosis, while it increased collagen synthesis during PU formation.
Declaration of interest: The study was supported by the Scientific Research Project Office of Dokuz Eylül University (Project number: 2019.KB.SAG.023). The authors have no conflicts of interest to declare.

animal model • glycerin • pressure ulcer • tea tree oil • wound • wound care • wound dressing • wound healing

Although more than 100 years have passed since its first description in the literature, pressure ulcers (PUs) continue to pose a major challenge among patients who are bedbound, with a global prevalence of up to 15–20% in hospital settings.[1] While it decreases patient quality of life, increases the length of hospital stay, and increases the risk of death, it also puts substantial burden on healthcare providers, systems and society.[1] This unresolved problem highlights the need for rigorous pre-clinical and clinical studies to develop knowledge for better prevention and treatment of PUs.

Besides the skin/tissue abrasion due to mechanical reasons, ischaemia and reperfusion has been defined as major contributing factors in the generation of PUs.[2] Wound healing, in general, is a complex process involving local inflammatory cell infiltration, granulation tissue formation with neo-angiogenesis, fibroblast migration with collagen accumulation and, finally, re-epithelialisation. Upon microscopic examination, the persistence of apoptotic and inflammatory cells is a hallmark of PUs.[3]

Tea tree oil (TTO) (*Melaleuca alternifolia*) has been incorporated into a plethora of skincare products owing to its antimicrobial, anti-inflammatory, and antioxidant properties, primarily due to its major constituent terpinen-4-ol.[4,5] Furthermore, it is widely applied to effectively treat various skin diseases,[6] including meticillin-resistant *Staphylococcus aureus* infections.[7] However, according to our extensive literature search, the effect of TTO on PUs has not yet been investigated. This study therefore aimed to investigate the possible beneficial effects of TTO on the prevention and treatment of PUs in an animal model.

Methods

A total of 62 male and female Wistar albino rats (weight 250–300g) were housed at a constant room temperature and humidity. They were maintained in individual cages during the experiments under a 12-hour light/dark cycle. The institutional animal ethics committee of Dokuz Eylül University approved this study (No: 2019/2018240). The animals were randomly divided into the following groups with equal amounts of males and females:

- Glycerin group (n=20) containing rats with PUs treated with glycerin
- TTO group (n=20) containing rats with PUs treated with glycerin + TTO
- Control group (n=20) containing rats with PUs receiving no treatment.

Additionally, one male and one female rat were

Nazan Tuna Oran,[1] PhD*; **Nurten Alan**,[2] PhD; **Pınar Akokay**,[3] PhD; **Sibel Büyükçoban**,[4] MD; **Bekir Uğur Ergür**,[5] MD
***Corresponding author email**: nazan.oran@ege.edu.tr
1 Ege University, Faculty of Health Sciences, İzmir, Turkey. **2** Dokuz Eylul University, Faculty of Nursing, İzmir, Turkey. **3** Kavram Vocational School, Medical Laboratory Section, İzmir, Turkey. **4** Department of Anesthesiology and Reanimation, Dokuz Eylül University Faculty of Medicine, İzmir, Turkey **5** Kyrenia University, Faculty of Health Sciences, Cyprus.

© 2023 MA Healthcare Ltd

used to characterise the normal histological features of rat skin.

Wound model and treatment

The rats were shaved and disinfected with 75% ethanol. Commercially available 10×2mm neodymium circular magnets were used to induce pressure. All magnets were re-sterilised using dry heat before application. The dorsal skin (epidermis, dermis and hypodermis) was gently pulled up and positioned between two magnets (Fig 1).

The components of TTO values have already been established.[8] Commercially available TTO must contain minimum terpinen-4-ol levels of 30%, a major bioactive ingredient, according to the international standard.[9] In the literature, TTO has been applied topically using a 5–50% dilution.[6] We preferred using a 10% dilution, which is frequently used for the topical administration of medicinal plant extracts.[8]

A 50µl aliquot of glycerin (medical grade, 99.5% purity) or TTO (in glycerin at 10% (volume/volume (v/v)) (TTO group)) was applied over the wounds and allowed to absorb for 30 minutes, followed by placement of the magnets. The same topical treatment was applied eight hours later, following the release of the magnet. The control group also underwent the same magnet placement method but remained untreated. The magnets were applied for eight hours, followed by a release period of 16 hours, constituting one cycle. The animals were investigated after one, four, seven and 14 cycles using thermal camera imaging.

Thermal camera analysis

The wounds were photographed on days 1, 4, 7 and 14 using a thermal camera (FLIR One Pro, FLIR Systems Inc., US) attached to a smartphone. The environmental factors such as temperature and the focal length were kept constant at the time of photography for all the cases. Using real-time thermal camera imaging, the temperature of the wound was recorded (Fig 2).

Histomorphological examination

The skin tissues were placed in 10% buffered formaldehyde and fixed in paraffin, and 5µm sections were prepared and stained with haematoxylin and eosin (H&E) as well as with Masson's trichrome. The sections were primarily used to assess leukocyte infiltration and collagen accumulation; the former was used to assess inflammation and the latter was used to quantify the wound healing process.

Immunohistochemistry

The streptavidin–biotin method was used for immunohistochemistry. The sections were placed on lysine-coated slides, kept in a 60°C oven overnight, passed through a xylol series, deparaffinised and then rehydrated through an alcohol series. The sections were treated with 10mM citrate buffer at 95°C for five minutes to unmask the antigens. The sections were circumscribed using a Dako pen (Dako, Denmark) and incubated in a 37°C oven for 15 minutes with 3% hydrogen peroxide to inhibit endogenous peroxidase activity. The sections were subsequently incubated with a normal serum-blocking solution for 30 minutes and incubated with primary antibodies against caspase 3 (Casp3) and caspase 9 (Casp9) (well-known apoptosis assays[9]) overnight in a humidity chamber of 30–60%. The next day, the sections were washed with phosphate-buffered saline (PBS) and then incubated with biotinylated immunoglobulin (Ig)G and then with streptavidin–peroxidase conjugate (Histostain-Plus Kit Broad Spectrum, 85-9043,

Fig 1. Photograph showing rat dorsal skin sandwiched between two magnets



Fig 2. Temperature measurement at the centre of the wound using a thermal camera **(a)**. A corresponding photograph showing the wound created by the magnets **(b)**

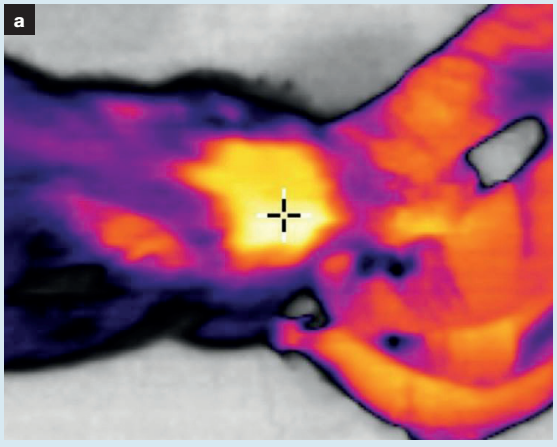

© 2023 MA Healthcare Ltd

Invitrogen, US). After the sections were washed three times in PBS, they were incubated with 3,3'-diaminobenzidine (DAB) (Roche, Germany) for two minutes to detect immunoreactivity. Finally, the sections were covered with entellan (Merck, Germany) after staining with Mayer's haematoxylin (Sigma Aldrich, Germany) for 10 seconds.

TUNEL staining

The In Situ Cell Death Detection Kit (Roche, Germany) was used for terminal deoxynucleotidyl transferase dUTP nick end labeling (TUNEL) staining, another well-known apoptosis assay.[10] The sections were kept in a 60°C oven overnight and subsequently turned transparent with three changes of xylene for 30 minutes each. Then, the sections were rinsed in distilled water and dehydrated in a decreasing alcohol series. The sections were immersed in sodium citrate solution and heated in a 600 watt microwave for six minutes and left to cool for 20 minutes. The sections were washed three times in PBS. Excess water around the tissue was removed using blotter paper after each wash. Then, the sections were immersed in 3% hydrogen peroxide for 10 minutes to block endogenous peroxidase activity. The sections were washed again in PBS and placed in equilibration buffer for 10 minutes. The sections were incubated with terminal deoxynucleotidyl transferase enzyme solution at 37°C in the oven for one hour, washed in PBS, and placed in stop buffer solution (Sigma Alrich, Germany) for 10 minutes. They were then washed again in PBS and stained with DAB to detect the TUNEL reaction. After washing in distilled water, the sections were stained with Mayer's haematoxylin, dehydrated in an increasing alcohol series, treated with xylene and covered with entellan.

Fig 3. Semi-quantitative assessment of leukocyte infiltration in the control, glycerin, and tea tree oil (TTO) groups. Although the suppressive effect on infiltration was apparent in the glycerin group at all timepoints, this effect was significant in the TTO group compared with the control group. The stars denote significant differences *p<0.01

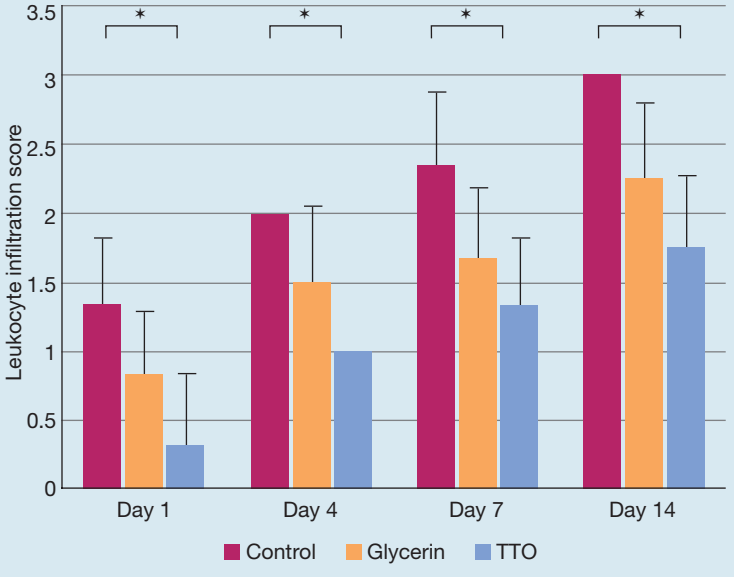

Image analysis

All tissue sections were examined under a light microscope (BX-50, Olympus, Japan) and images were transferred to a computer using a high-resolution camera (DP-70, Olympus, Japan). An image analysis system (UTHSCA Image Tool software version 3.0, University of Texas Health Science Center, US) was used to quantify the images. The entire wound area on the slide was observed under different magnifications, and the positive signals were scored semi-quantitatively as: 1=low; 2=medium; 3=high; and 4=very high for Casp3, Casp9, TUNEL and collagen staining. Leukocyte infiltration was scored as: 0=absent; 1=low; 2=medium, or 3=high.

Statistical analysis

The data are reported as the mean±standard deviation. The statistical analysis was performed using the SPSS software (version 24.0, SPSS Inc., US). The Kruskal–Wallis test was used to compare the results between groups. A p-value of <0.05 was considered significant.

Results

Histologically confirmed inflammatory cell infiltration and apoptosis were first observed at the beginning of the pressure/release cycle on day 1. Inflammatory cell infiltration was suppressed in both the glycerin and TTO groups at all timepoints; however, the difference was only significant in the TTO group ($p<0.01$) (Fig 3). Apoptosis was also suppressed in both the glycerin and TTO groups at all timepoints and reached the maximum level on day 14. The suppressive effect of glycerin alone was significant compared with the control group on days 1 (TUNEL) and 14 (Casp3, Casp9 and TUNEL) (Figs 4a–6a) ($p<0.01$). Apoptosis suppression induced by glycerin was accentuated by TTO throughout the experiment; the differences in Casp3 and Casp9 levels were significant on days 7 and 14 ($p<0.01$). Differences in the TUNEL assay results were significant at all timepoints, compared with those in the control group ($p=0.05$ for day 4, $p<0.01$ for other timepoints). In line with the suppressed inflammation and apoptosis, the local temperature increase was less prominent at all timepoints in both the glycerin and TTO groups. The temperature difference between the TTO group and the control group was significant on days 4 and 7 ($p<0.02$). The local temperature values further declined in all groups on day 14 (Fig 7). Collagen synthesis was suppressed in the control group at all timepoints—an indicator of a sustained and progressive wound. However, collagen synthesis was accentuated in both treatment groups, with TTO being the most prominent. This beneficial effect of treatment reached the statistically significant level at day 14 ($p<0.01$) (Fig 8a).

© 2023 MA Healthcare Ltd

Discussion

In this animal model, clinically relevant duration of pressure application induced PU formation over time. As a powerful and well-known humectant, glycerin alone suppressed inflammation and apoptosis at all timepoints. However, adding 10% (v/v) TTO to the glycerin significantly strengthened this suppressive effect at all timepoints evaluated. Besides, glycerin and TTO accentuated collagen accumulation in the wound and TTO was more powerful in this respect than glycerin alone. Thus, topical application of 10% (v/v) TTO in glycerin suppressed local inflammation and apoptosis. It also increased collagen synthesis and, thus, may have slowed the formation of PUs with subsequent beneficial effects on wound healing.

Intermittent skin-fold compression using a dual magnet on the murine dorsum is an easy way to induce PU formation that does not necessitate immobilisation, anaesthesia or surgical intervention.[11–17] Common findings detected in these animal studies include decreased skin perfusion accompanied by hypoxia, local infiltration of inflammatory cells, and increased levels of inflammatory markers/cytokines, oxidative stress, apoptosis, and angiogenesis/tissue regeneration markers.[11–17]

Although pressure-related ischaemia and/or breakdown of tissue are widely accepted as the aetiology of PUs, reperfusion injury, defined as the return of the blood supply after ischaemia, is another major contributor to PU formation in humans.[2] Repeated ischaemia–reperfusion increases the production of free radicals, which leads to an exaggerated local inflammatory reaction and accelerated apoptosis. The imbalanced metabolic status of the body and infected body parts are other facilitative factors.[18] In a seminal study by Allman et al.,[19] unblanchable erythaema,

Fig 4a. Semi-quantitative assessment of Caspase 3 staining in the control, glycerin, and tea tree oil (TTO) groups. Caspase 3 staining was significantly weaker in the glycerin group than in the control group on day 14, and significantly weaker in the TTO group than in the control group on both days 7 and 14. The stars denote significant differences *p<0.01

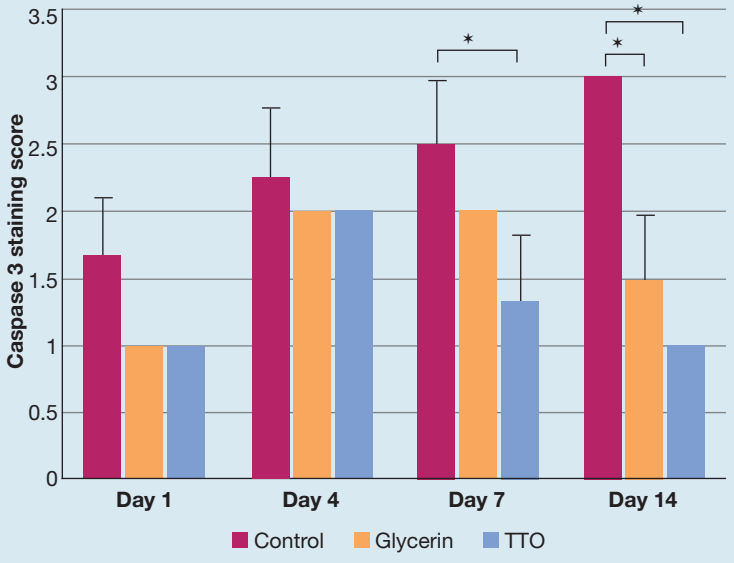

Fig 4b. Examples of Caspase 3 staining in all groups at all timepoints. TTO—tea tree oil

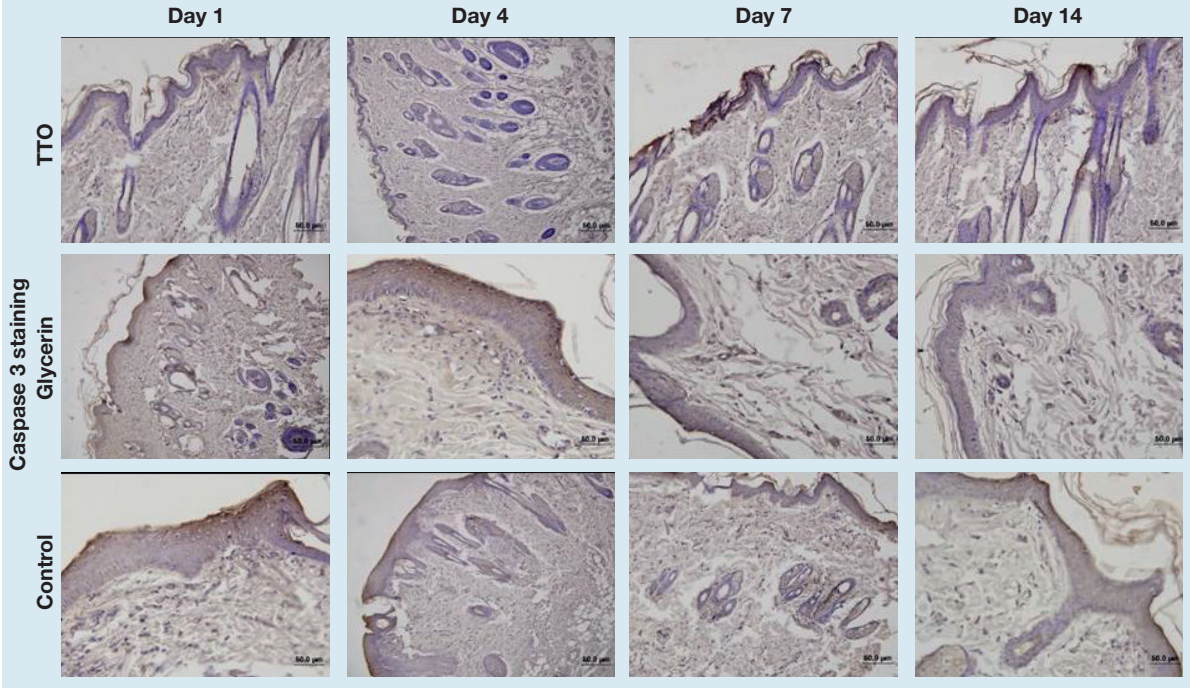

© 2023 MA Healthcare Ltd

Fig 5a. Semi-quantitative assessment of Caspase 9 staining in the control, glycerin and tea tree oil (TTO) groups. Caspase 9 staining was significantly weaker in the glycerin group than the control group on day 14 and significantly weaker in the TTO group than the control group on both days 7 and 14. The stars denote significant differences *p<0.01

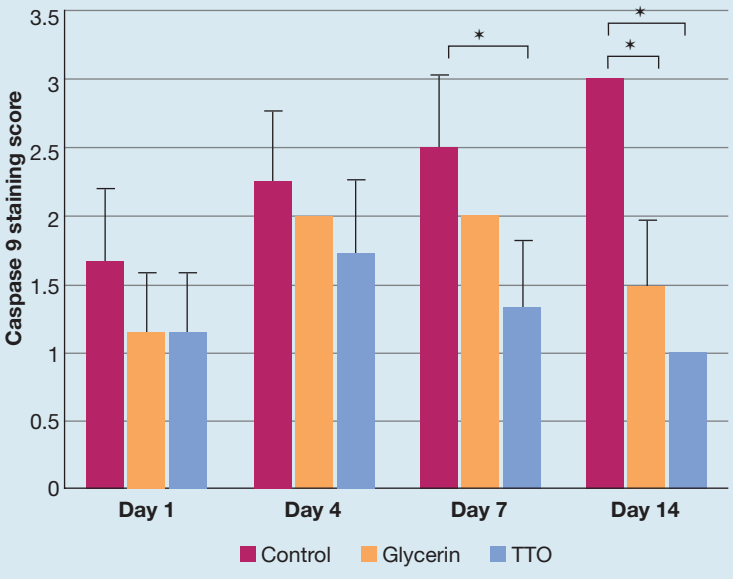

lymphopenia, dry skin, and decreased body weight were independent and significant risk factors for PU formation in activity-limited hospitalised patients.[18] Therefore, keeping the skin clean and appropriately hydrated in patients who are bedbound has been a common clinical practice worldwide. According to clinical practice guidelines proposed in 2019, regular application of a moisturiser is suggested for promoting skin hydration and preventing skin conditions, such as dry skin and skin tears.[20]

We used topical TTO and demonstrated its suppressive effect on local inflammation and apoptosis as well as its enhancing effect in collagen synthesis, which in turn may suppress the generation of PUs. We selected glycerin as the TTO carrier for two reasons. First, topical glycerin has been used clinically as a carrier for many medicines and cosmetics. Second, glycerin is a powerful humectant that attracts, binds, and holds moisture at the application sit. As skin-moisturising agents are recommended by the 2019 clinical practice guidelines,[20] glycerin is an appropriate carrier agent for delivering topical TTO and preventing PUs. Glycerin penetrates the skin rapidly, retains water in the stratum corneum, promotes wound healing and improves skin barrier function.[21] Our study showed that topical glycerin alone had anti-inflammatory, anti-apoptotic and collagen-enhancing effects during PU formation, and those beneficial effects were significantly strengthened by 10% (v/v) TTO dissolved in glycerin. Besides, many other beneficial effects of TTO have already been reported, such as its antimicrobial, anti-inflammatory and antioxidant properties,[4,5] and has been used to treat various skin diseases.[6,7] The wound-healing effect of TTO has recently been demonstrated in an animal model.[22]

Fig 5b. Examples of Caspase 9 staining in all groups at all timepoints

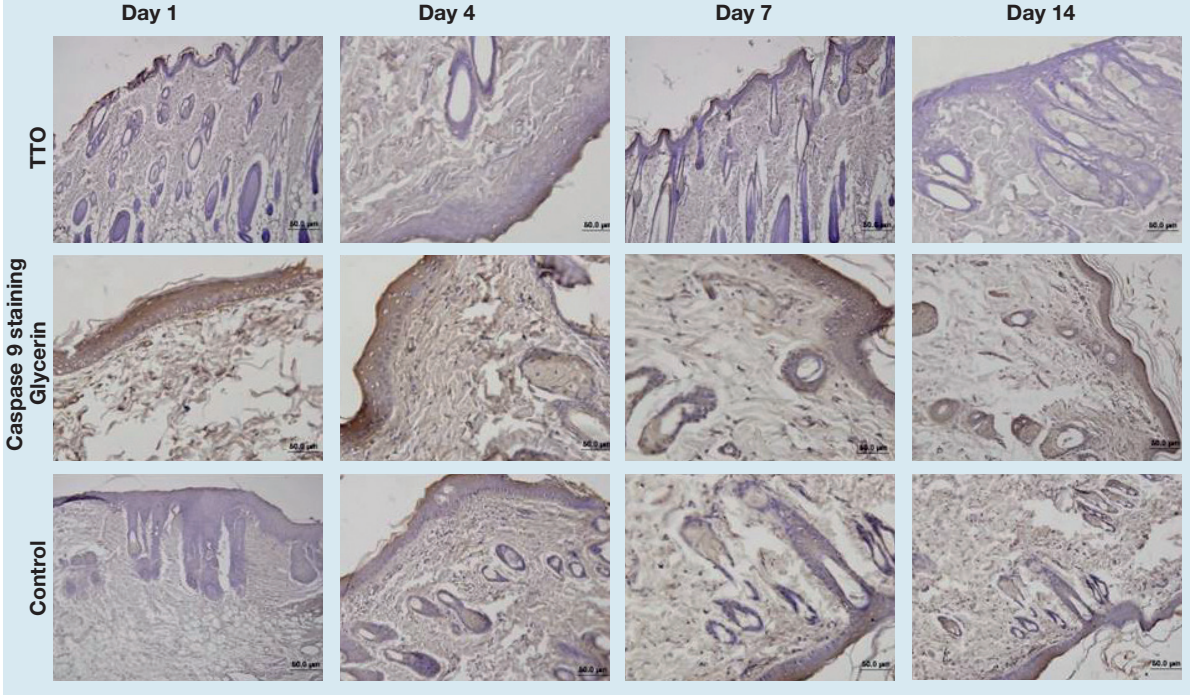

© 2023 MA Healthcare Ltd

Infrared thermography has been the emerging diagnostic tool for the assessment of PU inflammation accompanied by increased blood flow which can lead to hyperthermia, whereas poor perfusion is responsible for a hypothermic pattern.[23] In a human study, the infrared thermography was found to be useful as a prognostic tool during the treatment of PUs, with the ability to predict the course of healing.[23] We showed that the local temperature had raised at the beginning of the experiment, parallel to the generation of a local inflammatory reaction. The temperature then dropped to lower values, probably due to pressure-induced irreversible damage of the skin capillaries with subsequent blood perfusion deficiency at the later phase of experiment, where irreversible skin necrosis was apparent. The lowering effect of TTO and glycerin on the raised local temperature further confirmed the healing effect of this topical treatment during the generation of PUs.

Limitation

In spite of the data generated, the pathophysiological understanding of the therapeutic effect of TTO was not specificially addressed in this study.

Conclusion

In this animal study, TTO in a glycerin carrier effectively suppressed skin inflammation and apoptosis, and enhanced collagen synthesis during the formation of PUs which was followed by an accentuated healing process. We recommend further studies to investigate the molecular mechanism involving biological properties of TTO in preventing and healing PUs. **JWC**

Fig 6a. Semi-quantitative assessment of terminal deoxynucleotidyl transferase dUTP nick end labeling (TUNEL) staining in the control, glycerin and tea tree oil (TTO) groups. TUNEL staining intensity was significantly lower in the glycerin group than the control group on days 1 and 14 and in the TTO group than the control group at all time points. The stars denote a significant difference *p=0.05 for day 4, *p<0.01 for other timepoints

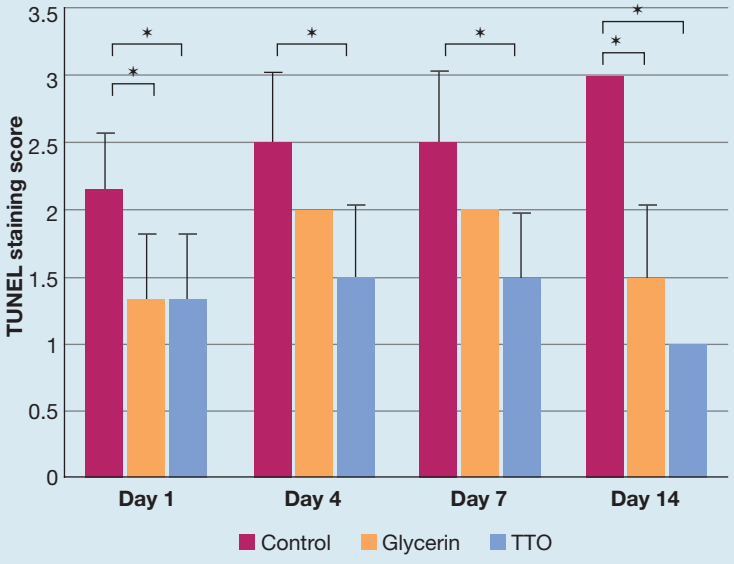

Fig 6b. Examples of TUNEL staining in all groups at all timepoints

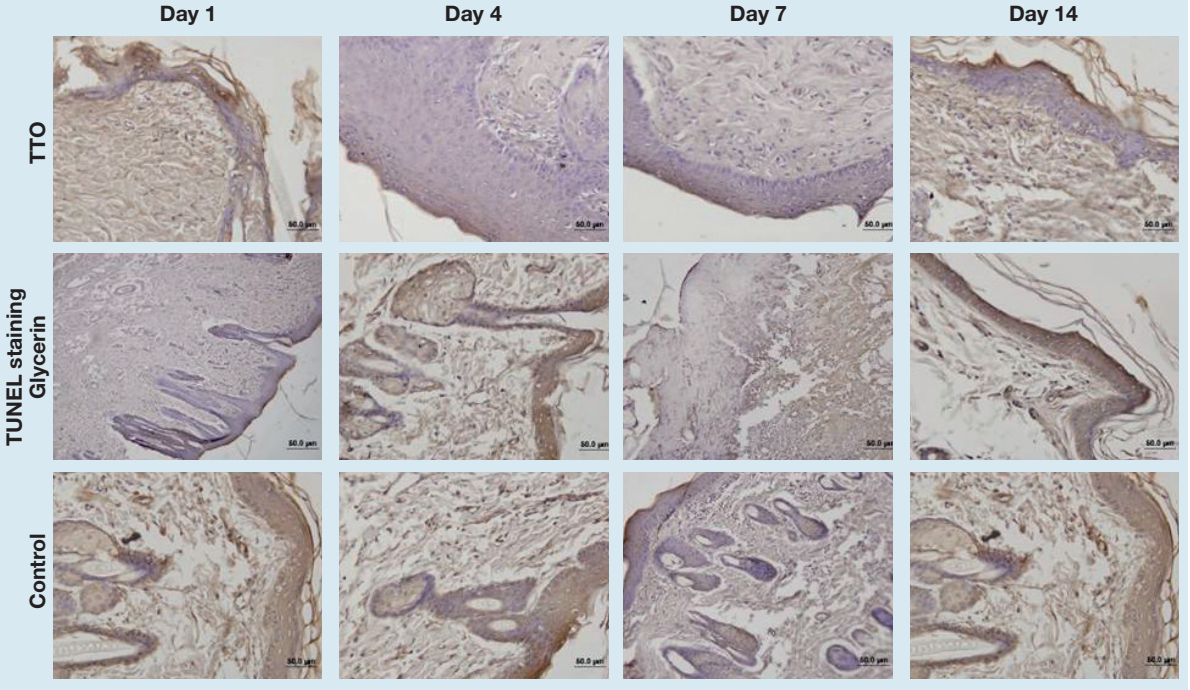

© 2023 MA Healthcare Ltd

Fig 7. The local temperature (in celsius) rise was significantly attenuated in the glycerin and tea tree oil (TTO) groups compared with the control group, suggesting a suppressive effect on inflammation by glycerin and TTO

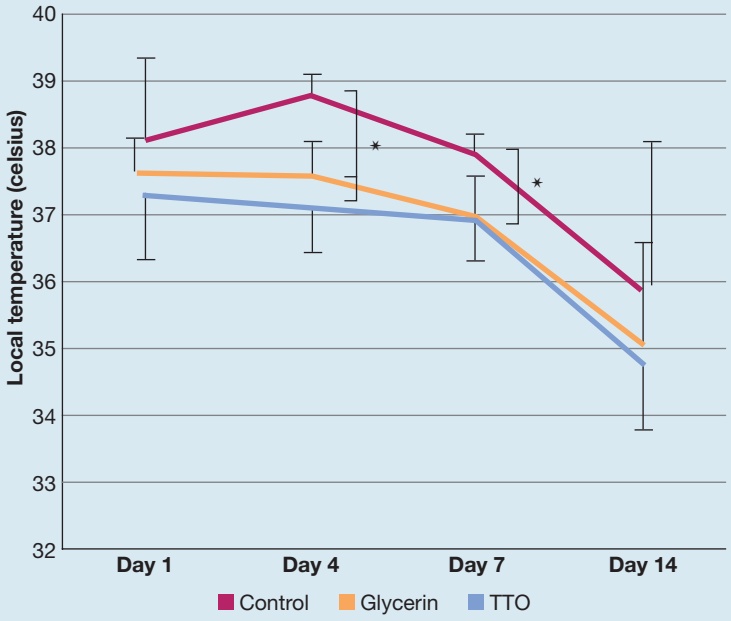

Fig 8a. Semi-quantitative assessment of Masson's trichrome staining in the control, glycerin and tea tree oil (TTO) groups. Note the progressively suppressed collagen synthesis in the magnet (i.e., no treatment) group during the experiment. The enhanced collagen synthesis could be observed in glycerin and more evidently in the TTO group throughout the experiment. The stars denote a significant difference *p<0.01

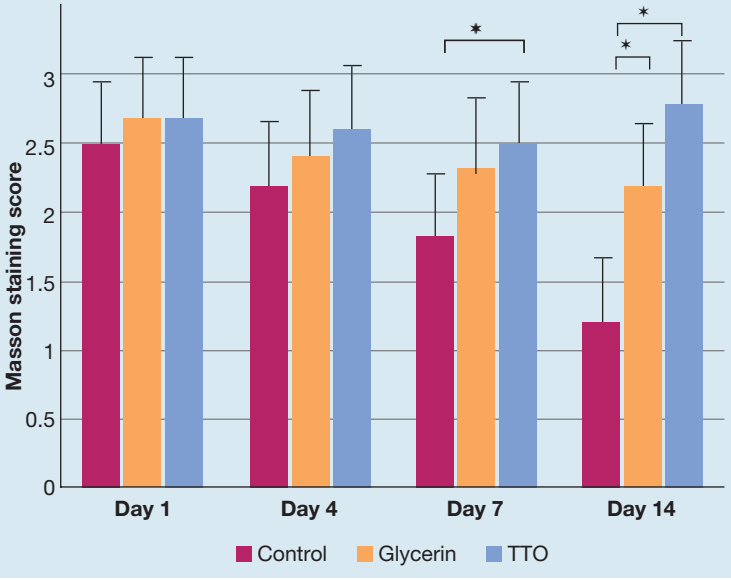

Acknowledgement: We thank Prof. Murat Bektaş for the statistical analysis of the study.

References

1 Van Damme N, Van Hecke A, Remue E et al. Physiological processes of inflammation and edema initiated by sustained mechanical loading in subcutaneous tissues: a scoping review. Wound Repair Regen 2020; 28(2):242–265. https://doi.org/10.1111/wrr.12777
2 Peirce SM, Skalak TC, Rodeheaver GT. Ischemia-reperfusion injury in chronic pressure ulcer formation: a skin model in the rat. Wound Repair Regen 2000; 8(1):68–76. https://doi.org/10.1046/j.1524-475x.2000.00068.x
3 Salcido R, Donofrio JC, Fisher SB et al. Histopathology of pressure ulcers as a result of sequential computer-controlled pressure sessions in a fuzzy rat model. Adv Wound Care 1994; 7(5):23–24.
4 Farag RS, Shalaby AS, El-Baroty GA et al. Chemical and biological evaluation of the essential oils of different Melaleuca species. Phytother Res 2004; 18(1):30–35. https://doi.org/10.1002/ptr.1348
5 Carson CF, Hammer KA, Riley TV. Melaleuca alternifolia (tea tree) oil: a review of antimicrobial and other medicinal properties. Clin Microbiol Rev 2006; 19(1):50–62. https://doi.org/10.1128/CMR.19.1.50-62.2006
6 Pazyar N, Yaghoobi R, Bagherani N, Kazerouni A. A review of applications of tea tree oil in dermatology. Int J Dermatol 2013; 52(7):784–790. https://doi.org/10.1111/j.1365-4632.2012.05654.x
7 Lee RL, Leung PH, Wong TK. A randomized controlled trial of topical tea tree preparation for MRSA colonized wounds. Int J Nurs Sci 2014; 1(1):7–14. https://doi.org/10.1016/j.ijnss.2014.01.001
8 Gharaboghaz MN, Farahpour MR, Saghaie S. Topical co-administration of Teucrium polium hydroethanolic extract and Aloe vera gel triggered wound healing by accelerating cell proliferation in diabetic mouse model. Biomed Pharmacother 2020; 127:110189. https://doi.org/10.1016/j.biopha.2020.110189
9 Homer LE, Leach DN, Lea D, et al. Natural variation in the essential oil content of Melaleuca alternifolia Cheel (Myrtaceae). Biochem Syst Ecol 2000; 28(4):367-382. https://doi.org/10.1016/s0305-1978(99)00071-x
10 Martinez MM, Reif RD, Pappas D. Detection of apoptosis: A review of conventional and novel techniques. Anal Methods 2010; 2(8):996–1004. https://doi.org/10.1039/c0ay00247j
11 Stadler I, Zhang RY, Oskoui P et al. Development of a simple, noninvasive, clinically relevant model of pressure ulcers in the mouse. J Invest Surg 2004; 17(4):221–227. https://doi.org/10.1080/08941930490472046
12 Tong M, Tuk B, Hekking IM et al. Heparan sulfate glycosaminoglycan mimetic improves pressure ulcer healing in a rat model of cutaneous ischemia-reperfusion injury. Wound Repair Regen 2011; 19(4):505–514. https://doi.org/10.1111/j.1524-475X.2011.00704.x
13 Kasuya A, Sakabe J, Tokura Y. Potential application of in vivo imaging of impaired lymphatic duct to evaluate the severity of pressure ulcer in mouse model. Sci Rep 2015; 4(1):4173. https://doi.org/10.1038/srep04173
14 Strong AL, Bowles AC, MacCrimmon CP et al. Characterization of a murine pressure ulcer model to assess efficacy of adipose-derived stromal cells. Plast Reconstr Surg Glob Open 2015; 3(3):e334. https://doi.org/10.1097/GOX.0000000000000260
15 Thomé Lima AM, da Silva Sergio LP, da Silva Neto Trajano LA et al. Photobiomodulation by dual-wavelength low-power laser effects on infected pressure ulcers. Lasers Med Sci 2020; 35(3):651–660. https://doi.org/10.1007/s10103-019-02862-w
16 Inoue Y, Uchiyama A, Sekiguchi A et al. Protective effect of dimethyl fumarate for the development of pressure ulcers after cutaneous ischemia-reperfusion injury. Wound Repair Regen 2020; 28(5):600–608. https://doi.org/10.1111/wrr.12824
17 Yamazaki S, Sekiguchi A, Uchiyama A et al. Apelin/APJ signaling suppresses the pressure ulcer formation in cutaneous ischemia-reperfusion injury mouse model. Sci Rep 2020; 10(1):1349. https://doi.org/10.1038/s41598-020-58452-2
18 Mervis JS, Phillips TJ. Pressure ulcers: pathophysiology, epidemiology, risk factors, and presentation. J Am Acad Dermatol 2019; 81(4):881–890. https://doi.org/10.1016/j.jaad.2018.12.069
19 Allman RM, Goode PS, Patrick MM et al. Pressure ulcer risk factors among hospitalized patients with activity limitation. JAMA 1995; 273(11):865–870. https://doi.org/10.1001/jama.1995.03520350047027
20 Pressure Ulcer Advisory Panel, National Pressure Injury Advisory Panel, and Pan Pacific Pressure Injury Alliance. Prevention and treatment of pressure ulcers/injuries: clinical practice guideline. The international guideline. Emily Haesler (ed.). EPUAP/NPIAP/PPPIA. 2019. https://tinyurl.com/58spycbe (accessed 2 February 2023)
21 Fluhr JW, Darlenski R, Surber C. Glycerol and the skin: holistic approach to its origin and functions. Br J Dermatol 2008; 159(1):23–34. https://doi.org/10.1111/j.1365-2133.2008.08643.x
22 Labib RM, Ayoub IM, Michel HE et al. Appraisal on the wound healing potential of Melaleuca alternifolia and Rosmarinus officinalis L. essential oil-loaded chitosan topical preparations. PLoS One 2019; 14(9):e0219561. https://doi.org/10.1371/journal.pone.0219561
23 Bilska A, Stangret A, Pyzlak M et al. Skin surface infrared thermography in pressure ulcer outcome prognosis. J Wound Care 2020; 29(12):707–718. https://doi.org/10.12968/jowc.2020.29.12.707

© 2023 MA Healthcare Ltd

Fig 8b. Examples of Masson's trichrome staining in all groups at all timepoints

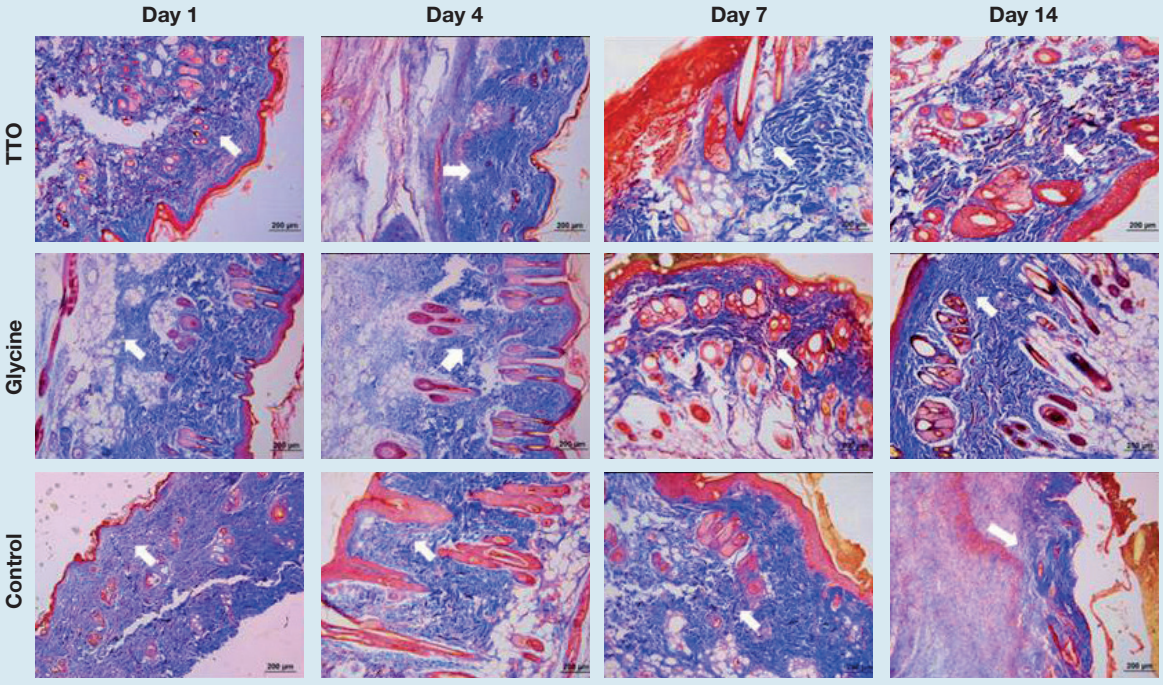

Reflective questions

- What is the mechanism underlying the generation of a pressure ulcer (PU)?
- What factors can facilitate the generation of a PU?
- What measures should be taken to prevent the development of a PU?



© 2023 MA Healthcare Ltd