ABSTRACT CC-1521 · CUTANEOUS ONCOLOGY

Giant Scalp Melanoma Misdiagnosed as Seborrheic Dermatitis: Diagnostic Delay and Fulminant Fatal Course

Dokuz Eylul University
Faculty of Medicine · Izmir

Yagiz Ustundag[1], Ozlem Ozbagcivan[1], Yasemin Cakir[2]

[1]Department of Dermatology, Dokuz Eylul University Faculty of Medicine, Izmir, Turkey · [2]Department of Pathology, Dokuz Eylul University Faculty of Medicine, Izmir, Turkey

KEY FACTS

~5%
of melanomas arise on the scalp

~10%
of melanoma deaths are scalp-related

82
years old at presentation

4 weeks
from diagnosis to death

INTRODUCTION

Delayed diagnosis, rich vascularization, increased Breslow thickness, neurotropism, and difficulty achieving adequate margins make scalp melanomas disproportionately deadly — often referred to as "invisible killers" in the literature.[1,2,3]

We report a rare giant scalp melanoma with delayed diagnosis, rapid clinical deterioration, and a fatal outcome.

CLINICAL TIMELINE

~1 year before
Crusted scalp plaques first appear

5 months prior
Misdiagnosed as seborrheic dermatitis; topical corticosteroids, no response

Progressive course
Lesion enlarges into a confluent infiltrative scalp mass

Admission
Facial erythema/fever; giant scalp tumor; cervical lymphadenopathy

Work-up
Biopsy confirms melanoma; PET-CT shows hepatic, splenic, and nodal metastases

4 weeks after diagnosis
Ipilimumab/nivolumab started; fulminant hepatic and renal failure and death

CLINICAL IMAGE



Figure 1. Large infiltrative lesion involving the frontoparietotemporal scalp, characterized by black, gray, and violaceous papules, nodules, and tumor masses with scaling, crusting, and satellite lesions.

CASE PRESENTATION

An 82-year-old woman presented with a 1-week history of facial erythema, fever, and headache. Examination revealed erythema and edema of the left malar region consistent with erysipelas, plus a large infiltrative frontoparietotemporal scalp lesion with black, gray, and violaceous papules, nodules, and tumoriform masses with scale, crusting, and satellite lesions (Figure 1). Left cervical lymphadenopathy was also noted.

Dermoscopy demonstrated irregular black, gray, and brown structureless areas with scale and crusts, white shiny lines and structures, focal ulceration, and peripheral pink-red structureless areas with white shiny streaks (Figure 2A-C). Admission labs showed elevated CRP (11.8 mg/L) and LDH (1394 U/L), with leukocytosis and neutrophilia; liver and renal function were normal.

Three incisional biopsies from the frontal, parietal, and postauricular regions revealed an atypical melanocytic proliferation with a mitotic rate of 10/mm² and no histopathological ulceration, lymphovascular invasion, or perineural invasion. Prominent solar elastosis favored lentigo maligna melanoma; tumour cells were positive for S100, HMB45, Melan-A, and SOX10 (Figure 2D-F). A subsequent excisional biopsy of a frontal satellite lesion confirmed the diagnosis of melanoma.

PET-CT demonstrated extensive hypermetabolic scalp lesions, bilateral cervical lymph node involvement, pleural effusion, and hepatic, splenic, periportal, and paraaortic metastases; brain MRI showed no intracranial involvement. The patient developed jaundice and worsening hepatic dysfunction (AST 154, ALT 202, GGT 522 U/L; LDH peak 4605 U/L), consistent with a visceral crisis from extensive liver metastases.

Given rapidly progressive metastatic disease, combination immunotherapy with ipilimumab and nivolumab was initiated. She subsequently developed acute hepatic and renal failure with hyperkalemia in the setting of extensive metastatic disease and died four weeks after diagnosis. In the present case, the rapid clinical deterioration and death within four weeks of diagnosis did not allow molecular profiling or further systemic therapy.

DERMOSCOPY & HISTOLOGY

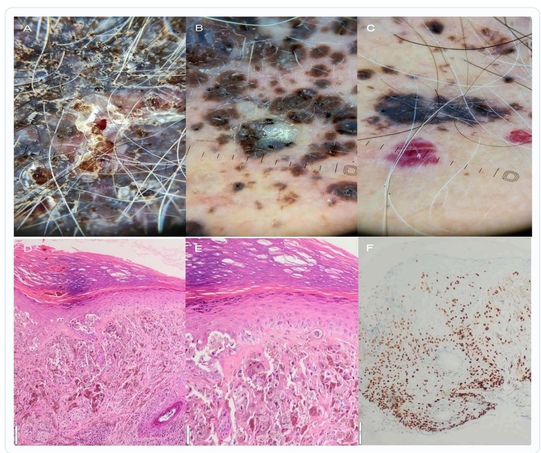

Figure 2. (A–C) Dermoscopy: structureless black/gray/brown areas with scales and crusts, white shiny lines, focal ulceration, and peripheral pink-red structureless areas with white shiny streaks. (D, E) Melanoma with pleomorphic cells and an intraepidermal component (H&E, ×200 and ×400). (F) SOX10 nuclear positivity in melanoma cells (×200).

REPORTED GIANT SCALP MELANOMAS

Case	Age/ sex	Metastasis	Treatment
Ching A et al, 2012[4]	70/M	No	Surgical excision + lymph node dissection
Panajotovic L et al, 2007[5]	57/M	No	Surgical excision
González-González A et al, 2026[6]	72/M	No	BRAF/MEK inhibitors
Current case, 2026	82/F	Yes	Ipilimumab + nivolumab (1 cycle) — death

Table 1. Unlike prior non-metastatic cases managed surgically, the present case already had systemic dissemination at diagnosis.

CONCLUSION

Giant scalp melanoma is rare,[4,5,6,7,8] and delayed recognition may allow extensive local progression and metastatic dissemination. In this case, a lesion initially diagnosed as seborrheic dermatitis progressed to a giant infiltrative melanoma with widespread visceral metastases.

Persistent, treatment-resistant, atypical or rapidly progressive scalp lesions should prompt early reassessment and histopathological confirmation.

The rapid clinical deterioration in this case, with death four weeks after diagnosis, highlights the potential consequences of diagnostic delay in advanced scalp melanoma.

CLINICAL TAKE-HOME MESSAGE

Melanoma should be considered in atypical, persistent, treatment-resistant or rapidly progressive scalp lesions.

Early biopsy is essential when the clinical course is unexplained or refractory to treatment, as diagnostic delay may permit extensive tumour progression and metastatic dissemination.

KEY LEARNING POINTS

- Scalp melanoma may mimic inflammatory or benign dermatoses.
- Persistent or treatment-resistant scalp lesions require early biopsy.
- Advanced scalp melanoma may progress rapidly despite initiation of systemic therapy.

REFERENCES

1. Wood RP, Heyworth JS, McCarthy NS, et al. Association of known melanoma risk factors with primary melanoma of the scalp and neck. Cancer Epidemiol Biomarkers Prev. 2020;29(11):2203–2210.
2. Porto AC, Pinto Blumetti T, Oliveira Santos Filho IDA, et al. Primary cutaneous melanoma of the scalp: patterns of clinical, histological and epidemiological characteristics in Brazil. PLoS One. 2020;15(10):e0240864.
3. Licata G, Scharf C, Ronchi A, et al. Diagnosis and management of melanoma of the scalp: a review of the literature. Clin Cosmet Investig Dermatol. 2021;14:1435–1447.
4. Ching A, et al. Giant scalp melanoma: a case report and review of the literature. Dermatol Surg. 2012;38(5):782–786.
5. Panajotovic L, et al. Extensive melanoma of the scalp: management challenges. J Plast Reconstr Aesthet Surg. 2007;60(4):439–443.
6. González A, et al. Giant scalp melanoma in an immunosuppressed patient. JAAD Case Rep. 2026.
7. Müller CS, Hinterberger L, Vogt T, Pföhler C. Giant melanoma of the scalp — discussion of a rare clinical presentation. BMJ Case Rep. 2011;2011:bcr1220103643.
8. Grisham AD. Giant melanoma: novel problem, same approach — 5-mm punch biopsy. South Med J. 2010;103:1161–1162.