J Pediatr Res 2022;9(3):307-13
DOI: 10.4274/jpr.galenos.2022.05579

Case Report

Virilizing Adrenocortical Carcinoma Oncocytic Variant in a Child with Heterosexual Precocious Puberty and a Literature Review

Seyran Bulut[1], Gönül Çatlı[2], Berna Eroğlu Filibeli[1], Hayrullah Manyas[1], İlkay Ayrancı[1], Rabia Meral[1], Deniz Kızmazoğlu[3], Bumin Nuri Dündar[2]

[1]University of Health Sciences Turkey, İzmir Tepecik Training and Research Hospital, Clinic of Pediatric Endocrinology, İzmir, Turkey
[2]İzmir Katip Çelebi University Faculty of Medicine, Department of Pediatric Endocrinology, İzmir, Turkey
[3]University of Health Sciences Turkey, İzmir Tepecik Training and Research Hospital, Clinic of Pediatric Hematology and Oncology, İzmir, Turkey

ABSTRACT

Androgen-secreting adrenal tumors are aggressive cancers in childhood; however, they are rare in clinical practice. Children with adrenal carcinoma usually present with peripheral precocious puberty, premature pubarche, signs of virilization and clitoromegaly. We present a case of 4 year-old girl with premature pubarche, clitoromegaly and bone age advancement, who was subsequently diagnosed with pure androgen-secreting oncocytic adrenal carcinoma. After the removal of the adrenal tumor, our patient developed precocious puberty. In patients with functioning adrenocortical carcinoma who have had surgical removal, clinical follow-up and hormonal marker examination for the secondary effects of excessive hormone secretion at least every 2 or 3 months may be a useful option after surgery. The aim of this article is to emphasize that adrenal tumors can be seen in patients presenting with virilization findings. We also present a literature review of these tumors, which are very rare in childhood.

Keywords: Oncocytic variant adrenocortical cancer, peripheral precocious puberty, clitoromegaly

Introduction

Adrenocortical carcinoma (ACC) is an endocrine neoplasm arising in the outer part of the adrenal gland. Although most cases of ACC are sporadic, they have an association with hereditary cancer syndromes such as Li-Fraumeni syndrome and Beckwith-Wiedemann syndrome (1,2). They are categorized as functional (hormone-secreting), which are most commonly found in children and adolescents, or non-functional (silent), which are usually found in adults with symptoms of abdominal discomfort or back pain caused by the large mass of the tumor (3,4). ACC has a bimodal distribution; the first peak is in children less than five years and the second around the fifth decade (5). It comprises 0.3-0.5% of neoplasms detected in patients under the age of 15. ACC can be benign or malignant. The most common clinical presentation of ACC in children is peripheral puberty precocious observed in approximately 50-84.2% of cases and Cushing's syndrome in the remaining patients (6,7). Pure androgen-secreting adrenal tumors (PASATs) are rare in clinical practice (1). The majority of cases present with a combination of clinical features of Cushing's syndrome and hyperandrogenism. Oncocytic adrenocortical

Address for Correspondence
Seyran Bulut, University of Health Sciences Turkey, İzmir Tepecik Training and Research Hospital, Clinic of Pediatric Endocrinology, İzmir, Turkey
Phone: +90 555 233 94 14 E-mail: seyran-bulut@hotmail.com ORCID: orcid.org/0000-0001-6738-2646
Received: 30.11.2021 **Accepted:** 09.05.2022

©Copyright 2022 by Ege University Faculty of Medicine, Department of Pediatrics and Ege Children's Foundation
The Journal of Pediatric Research, published by Galenos Publishing House.

tumor is a rare subtype which represents approximately 10% of adrenocortical tumors with a challenging diagnosis and histo-prognostic assessment. It is usually accepted that oncocytic adrenocortical tumors have a more moderate clinical behavior than conventional adrenocortical tumors. Here, we describe the rare case of a 4-year-old girl with pure androgen secreting adrenal oncocytic carcinoma who presented with premature pubarche, clitoromegaly and advanced bone maturation. In this article, we also aimed to review the literature on functional adrenocortical cancers in childhood.

Case Report

A 4-year-old girl presented with a complaint of pubic hair development which had been ongoing for about one month. She had no history of axillary hair growth or thelarche. She was born at full-term without any perinatal problems and had no history of previous hospitalizations. Her parents were not related. On physical examination, her body weight was 21 kg [1.17 standard deviation (SD)], height was 111.5 cm (0.94 SD) and body mass index was 0.93 kg/m^2. The target height was 157.7 cm (-0.91 SD) which was 1.8 SD below her current height SD. Her blood pressure was 100/70 mmHg. Pubertal examination revealed no breast development or axillary hair; however, pubic hair was compatible with Tanner stage 3. She had an enlarged clitoris, 20 mm in length, with a normal vaginal opening (Figure 1). Clitoromegaly had not been recognized by her parents before and there were no other signs of genital ambiguity, systemic disease or Cushing syndrome. Abdominal examination revealed no palpable mass.

Laboratory investigations indicated hyperandrogenemia; serum total testosterone 206 ng/dL (<10 ng/dL), Dehydroepiandrosterone sulfate (DHEA-S) 447 mcg/dL (9-42 mcg/dL) and pre-pubertal gonadotropin levels follicle-stimulating hormone 0.8 U/L (0.4-3U/L), luteinizing hormone (LH) 0.2 U/L (<0.1U/L) and Estradiol <20 pg/mL (<16 pg/mL). Table I shows the laboratory values of our patient before and after the operation. Her bone age was seven years and ten months according to the Greulich & Pyle method. A standard dose adrenocorticotropic hormone test was performed in order to rule out classic or late-onset congenital adrenal hyperplasia and it was normal. An abdominal ultrasound showed a 22 mm by 31 mm well-defined and hypoechoic solid lesion in the right adrenal gland. Abdominal magnetic resonance confirmed a mass with a smooth contour that did not contain significant fat (Figure 2).



Figure 1. The appearance of the patient's external genitalia: cliteromegaly and vaginal opening

Table I. Pre-and post-operative hormone levels of the patient

	Pre-operative	Post-operative	Normal range
Total testosterone (ng/dL)	206	<10	(<10)
DHEA-S (mcg/L)	447	8.4	(<9-42)
FSH (U/L)	0.8	7.47	(0.4-3)
LH (U/L)	0.2	1.04	(<0.1)
Estradiol (pg/mL)	<20	25.25	(<16)
Cortisole (08:00 a.m.) (µg/dL)	9.95	13	(5-21)

The patient was diagnosed with an androgen secreting adrenocortical tumor based on the clinical, biochemical, and radiological investigations. Although she had no signs of Cushing's syndrome, hypertension or electrolyte abnormalities, further hormonal analyses were performed to identify any accompanying cortisol or aldosterone excess. An over-night dexamethasone suppression test revealed normal suppression at the cortisol level. Plasma renin activity and aldosterone levels were also in the normal ranges. The patient underwent right open adrenalectomy. The resected mass was a well encapsulated tumor of dimensions 4x3.2x1.3 cm.

Histopathological examination revealed oncocytic variant ACC (Figure 3). A metastatic work-up including chest computed tomography (CT) and positron emission tomography (PET)-CT scans revealed negative findings. The patient's tumor was stage 1. The patient was evaluated by the pediatric oncology council. Rigorous follow-up was decided upon without further postoperative chemoradiotherapy based on the borderline pathological classification criteria and no evidence for metastatic. After the operation, her total testosterone and DHEA-S values returned to normal levels. However, serum LH level increased to pubertal values. The patient developed central precocious puberty due to hypothalamic-pituitary-ovarian activation following the surgical removal of the androgen-producing tumor. The gonadotropin-releasing hormone agonist (leuprolide acetate) was started at 3.75 mg every 28 days.

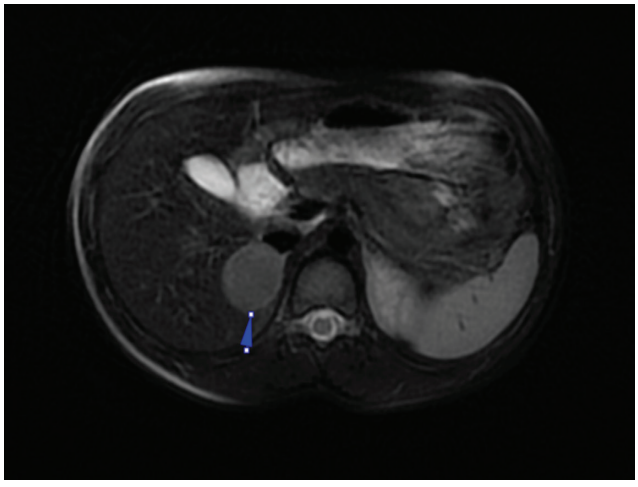

Figure 2. Abdominal MRI of the patient
MRI: Magnetic resonance imaging

Discussion

ACC is diagnosed at a frequency of 0.3 to 0.4 per million children annually (6-8). Pediatric ACCs are more commonly diagnosed in early childhood (<4 years) and predominantly affect girls (9). ACC can arise as either a non-functional or functional tumor. Non-functional ACC is most common in adults, whereas more than 90% of childhood ACCs are functional (10). Virilization alone or signs of other adrenal hormone overproduction are the most common endocrine presentation in pediatric patients (11). Isolated Cushing's syndrome, the primary symptom of adult ACC, is extremely rare, as is Conn's syndrome. Most cases of pediatric ACC are initially diagnosed based on their clinical and biochemical laboratory findings. Hagemann et al. (11) reported that approximately 90% of pediatric ACCs are hormonally active and the type of hormone secretion can lead to varied clinical presentations. In a large cohort of children with ACC, more than 90% of young children had virilizing features. In contrast, there was a tendency toward Cushing's syndrome and non-functional tumors

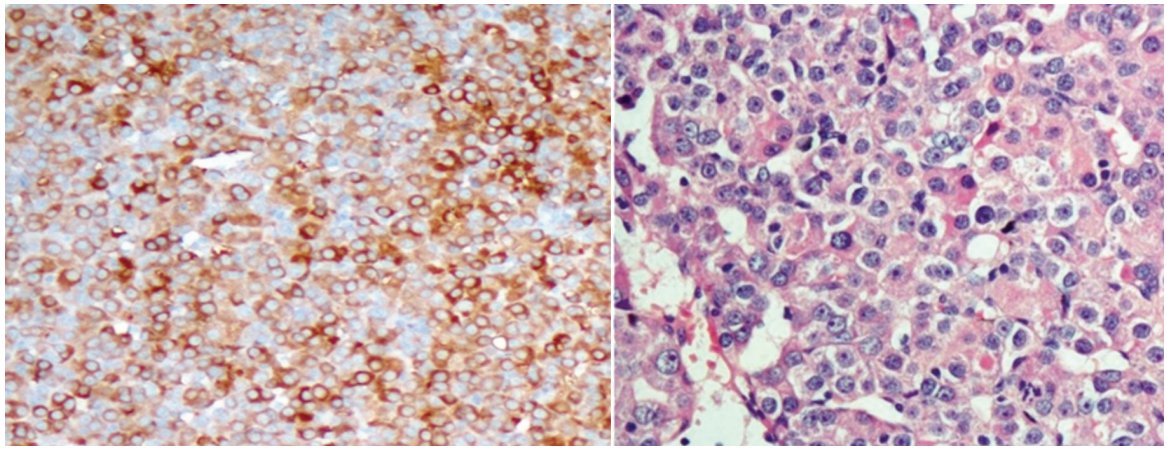

Figure 3. Microscopic findings of the oncocytic variant adrenocortical tumor

in adolescents (6). Our patient had a PASAT, which is extremely rare. In 2017, Tong et al. (12) reported 9 patients with PASATs, whose ages ranged between 3.5 and 64 years. Kamilaris et al. (13) reported two further girls aged 15 and 12 years of age with PASATs that predominantly secreted testosterone (14). These patients presented with primary amenorrhea and virilization. As illustrated by our case, signs of androgen hypersecretion can include accelerated growth velocity, bone age advancement, clitoromegaly, and premature pubarche. Michalkiewicz et al. (5) also pointed out that these children often do not appear to be ill and in fact their accelerated growth in the early stages can initially be mistaken as a sign of good health.

The diagnostic criteria for oncocytic ACC are different from those for conventional ACC. Oncocytomas are a rare etiology of the adrenal mass and they are defined as neoplasms consisting of cells with an abundant amount of eosinophilic granular cytoplasm packed with swollen mitochondria and composed solely or primarily of oncocytes (15). By definition, these tumors are made up of at least 50% oncocytic cells and are either mixed (50-90% oncocytic cells) or pure (>90%). The diagnostic criteria for oncocytic ACC are different from those for conventional ACCs. Identification of the oncocytic character of tumor cells is the first diagnostic difficulty. Prognostic evaluation of these tumors is the second difficulty given the multiplicity of scoring systems and the risk of overestimating potential malignancy, such as with the Weiss score, owing to parameters that are intrinsic to oncocytic cells (eosinophilic character, elevated Fuhrman grade, usually diffuse architectural structure, a minimum Weiss score of 3). The Lin-Weiss-Bisceglia (LWB) score, specifically developed for this type of tumor (16), has been the most commonly used since the publication of the Wong et al. (16) study and was recently recommended by the World Health Organization in 2017 LWB system: (1) major criteria (a mitotic rate of more than 5 mitoses per 50 high-power fields, any atypical mitoses or venous invasion), (2) minor criteria [large size (>10 cm and/or >200 gr), necrosis, capsular invasion or sinusoidal invasion] and (3) definitional criteria (predominantly cells with eosinophilic-granular cytoplasm, high nuclear grade and diffuse architectural pattern). It is often challenging to differentiate benign from malignant adrenocortical oncocytic carcinoma. Most studies demonstrated that a combination of clinical, biochemical and, in particular, histological features can distinguish adenoma from carcinoma. The presence of fibrous encapsulation in contrast imagining is suggestive of oncocytoma. According to the LWB system, our patient had 2 of the major criteria (atypical mitosis and a mitosis rate of more than 5 mitoses) and 2 of the minor criteria (capsule invasion, sinusoidal invasion) used for oncocytic tumors.

Metastatic work-up included a chest CT scan and a PET-CT scan, which revealed negative findings. Our patient's stage was 1. Based on the borderline criteria of the pathologic classification and no metastatic evidence, we decided just to observe her without further post-operative chemoradiotherapy.

Oncocytic ACCs are uncommon and their incidence is not precise. In the current literature, one hundred and fifty cases have been reported which were most often single cases or small series. The most extensive study consisted of 43 patients (15) with an average age of 47.5 years (38 between 55.8). Of these tumors, 28 were reported to be pure oncocytic tumors (>90% oncocyte), while 15 were mixed tumors (50-90% oncocyte with standard adrenal tumor cell components).

Oncocytic ACCs are rare in adults and they are even rarer in children. Oncocytic adrenocortical tumors are rare, with few cases reported in the literature. No more than 20 cases in children have been reported (17). A literature review of adrenocortical cancer is given below (Table II).

In a Turkish study published in 2017, 3 patients were diagnosed with oncocytic ACC between 2011-2016 (18).

In 2020, Akın et al. (19) reported on a children who had an oncocytic ACC and rhabdomyosarcoma at the same time. The patient was an 18-month-old boy and he was admitted with virilization of the genital area, penis enlargement and erection which had begun six months prior. Serum total testosterone, androstenedion, and DHEAS were measured in higher than normal ranges. A right adrenal mass was detected. After adrenalectomy, histopathological examination revealed oncocytic ACC.

Our patient had functional ACC which synthesized androgens only and presented with virilization findings. We made this case report to draw attention to this very rare disease.

Conclusion

In conclusion, virilization is an important manifestation of adrenocortical tumors in both sexes. We report the case of virilizing functional oncocytic ACC in a girl with accelerated skeletal maturation, clitoromegaly and premature pubarche. A high index of suspicion and an

Table II. Cases of oncocytic adrenocortical tumor in children reported in the literature

Ref.	Age in year	G	Clinical features	Size	Treatment	Follow-up	Prognosis
Gumy-Pause et al. (20)	12	F	Fatigue, headache, acne vulgaris, and abdominal pain	5.0 cm × 4.3 cm × 2.2 cm	Open adrenalectomy	Normal hormone levels 18 month after diagnosis	No recurrence
Lim et al. (21)	14	F	Deepening of the voice and excessive hair	17.5 cm × 15 cm × 14 cm	Open adrenalectomy	Normal hormone levels 2 week after operative resection	No recurrence
Tahar et al. (22)	6	F	Precocious puberty	3.0 cm × 2.0 cm × 1.5 cm	Open adrenalectomy	Twelve month after operative resection, he manifestations of pseudoprecocious puberty were effectively reduced	No recurrence
Subbiah et al. (23)	31/2	F	Premature pubarche, clitoromegaly	2.5 cm x 2 cm	Open adrenalectomy	Normal hormone levels 1 month after operative resection	No recurrence
Kawahara et al. (24)	11	F	Fever, weight loss, increased inflammatory markers	4.5 cm x 4.5 cm x 2.5 cm	Open adrenalectomy	The inflammatory markers and IL-6 levels normalized within 2 week after tumor resection	No recurrence
Yoon et al. (25)	10	F	Precocious puberty	6 cm x 4 cm	Open adrenalectomy	One year after surgery without new lesions	No recurrence
Akin et al. (26)	11	M	Metabolic, alkalosis, polyuria, polydipsia, hypokalemia	4.5 cm x 2.5 cm x 2.5 cm	Laparoscopic surgery	After the operation, the patient's polyuria and hypokalemia resolved, and his aldosterone level returned to normal	No recurrence
Ranganathan et al. (27)	5	M	Precocious puberty, acne	4.2 cm × 3.9 cm × 2.6 cm	Laparoscopic surgery	Three month later, the patient had lost 3.2 kg and had grown 3.5 cm. Clinically, his symptoms resolved with no progression of pubic hair, axillary hair, or acne	No recurrence
Mardi (28)	14	F	Hirsuitism	18 cm × 8.0 cm × 7.0 cm	Open adrenalectomy	The hirsuitism resolved gradually following surgery	No recurrence
Chen et al. (29)	15	M	Lower back pain	9 cm x 6.3 cm	Laparoscopic surgery	Lower back pain relief	No recurrence
Yordanova et al. (30)	9	F	Virilization	2.2 cm x 2.2 cm	Laparoscopic surgery	Eleven month after the surgery, the girl's appearance was less masculine, with significantly reduced body hairs but still no changes in the voice	No recurrence
Pereira et al. (31)	5.8	F	Weight gain, precocious puberty	3.2 cm x 4.5 cm	Open adrenalectomy	The patient is in complete remission after 64 month of follow-up	No recurrence
Kolev et al. (32)	9	F	Deepening of the voice and excessive hair	3 cm x 2.8 cm x 3.5 cm	Laparoscopic surgery	Normal hormone levels 2 week after operative resection	No recurrence
Agarwal and Agarwal (33)	2.5	F	Virilization	-	Open adrenalectomy, biopsy	Poor prognosis	No resection, infiltration into adjacent organs

increased awareness by pediatricians can play an important role in the early diagnosis and treatment of this disease.

Ethics

Informed Consent: Written consent was obtained from patient's family for this case.

Peer-review: Externally peer-reviewed.

Authorship Contributions

Concept: S.B., G.Ç., B.E.F., H.M., İ.A., R.M., D.K., B.N.D., Design: S.B., G.Ç., B.E.F., H.M., İ.A., R.M., D.K., B.N.D., Data Collection and/or Processing: S.B., G.Ç., B.E.F., H.M., İ.A., R.M., D.K., B.N.D., Analysis and/or Interpretation: S.B., G.Ç., B.E.F., H.M., İ.A., R.M., D.K., B.N.D., Writing: S.B., G.Ç., B.E.F., H.M., İ.A., R.M., D.K., B.N.D.

Conflict of Interest: The authors declared that there were no conflicts of interest.

Financial Disclosure: The authors declared that this study has received no financial support.

References

1. Chatterjee G, Das Gupta S, Mukherjee G, et al. Usefulness of Wieneke criteria in assessing morphologic characteristics of adrenocortical tumors in children. Pediatr Surg Int 2015; 31:563-71.
2. Lodish MB, Stratakis CA. Rare and unusual endocrine cancer syndromes with mutated genes. Semin Oncol 2010; 37:680-90.
3. Kim MS, Yang EJ, Cho DH, Hwang PH, Lee DY. Virilizing adrenocortical carcinoma advancing to central precocious puberty after surgery. Korean J Fam Med 2015; 36:150-153.
4. Ng L, Libertino JM. Adrenocortical carcinoma: diagnosis, evaluation and treatment. J Urol 2003; 169:5-11.
5. Michalkiewicz E, Sandrini R, Figueiredo B, et al. Clinical and outcome characteristics of children with adrenocortical tumors: a report from the International Pediatric Adrenocortical Tumor Registry. J Clin Oncol 2004; 22:838-45.
6. Cacciari E, Cicognani A, Pirazzoli P, et al. Adrenocortical tumours in children: our experience with nine cases. Acta Endocrinol Suppl (Copenh) 1986; 279:264-74.
7. Duregon E, Volante M, Cappia S, et al. Oncocytic adrenocortical tumors: diagnostic algorithm and mitochondrial DNA profile in 27 cases. Am J Surg Pathol 2011; 35:1882-93.
8. Sandrini R, Ribeiro RC, DeLacerda L. Childhood adrenocortical tumors. J Clin Endocrinol Metab 1997; 82:2027-31.
9. Rodriguez-Galindo C, Figueiredo BC, Zambetti GP, Ribeiro RC. Biology, clinical characteristics, and management of adrenocortical tumors in children. Pediatr Blood Cancer 2005; 45:265-73.
10. Sutter JA, Grimberg A. Adrenocortical tumors and hyperplasias in childhood--etiology, genetics, clinical presentation and therapy. Pediatr Endocrinol Rev 2006; 4:32-9.
11. Hagemann K, Zanolari Calderari M, Perren A, Cree I, Mullis PE, Flück C. A typical presentation of a hormonally active adrenocortical tumor in an adolescent leading to delayed diagnosis. Hormones (Athens) 2011; 10:317-25.
12. Tong A, Jiang J, Wang F, Li C, Zhang Y, Wu X. Pure Androgen-Producing Adrenal Tumor: Clinical Features And Pathogenesis. Endocr Pract 2017; 23:399-407.
13. Kamilaris TC, DeBold CR, Manolas KJ, Hoursanidis A, Panageas S, Yiannatos J. Testosterone-secreting adrenal adenoma in a peripubertal girl. JAMA 1987; 258:2558-61.
14. Sorgo W, Meyer D, Rodens K, et al. Testosterone-secreting adrenocortical tumor in a pubertal girl. Case report and review of the literature. Horm Res 1988; 30:217-23.
15. Renaudin K, Smati S, Wargny M, et al. Clinicopathological description of 43 oncocytic adrenocortical tumors: importance of Ki-67 in histoprognostic evaluation. Mod Pathol 2018; 31:1708-16.
16. Wong DD, Spagnolo DV, Bisceglia M, Havlat M, McCallum D, Platten MA. Oncocytic adrenocortical neoplasms--a clinicopathologic study of 13 new cases emphasizing the importance of their recognition. Hum Pathol 2011; 42:489-99.
17. Chen XC, Tang YM, Mao Y, Qin DR. Oncocytic adrenocortical tumor with uncertain malignant potential in pediatric population: A case report and review of literature. World J Clin Cases 2021; 9:5675-82.
18. Ertan Y, Argon A, Özdemir M, Yürekli BPS, Dökümcü Z, Makay Ö. Oncocytic Adreno Cortical Tumors: Pathological Features of 16 Cases and Review of the Literature. J Environ Pathol Toxicol Oncol 2017; 36:237-44.
19. Akın O, Ataş E, Atasoy İA, Durmaz N, Kartal Ö. Two Subsequent Metachroneus Solid Tumors: Oncocytic Variant Adrenocortical Carcinoma and Rhabdomyosarcoma of Childhood: Case Report and Literature Review. J Clin Res Pediatr Endocrinol 2021; 13:225-31.
20. Gumy-Pause F, Bongiovanni M, Wildhaber B, Jenkins JJ, Chardot C, Ozsahin H. Adrenocortical oncocytoma in a child. Pediatr Blood Cancer 2008; 50:718-21.
21. Lim YJ, Lee SM, Shin JH, Koh HC, Lee YH. Virilizing adrenocortical oncocytoma in a child: a case report. J Korean Med Sci 2010; 25:1077-9.
22. Tahar GT, Nejib KN, Sadok SS, Rachid LM. Adrenocortical oncocytoma: a case report and review of literature. J Pediatr Surg 2008; 43:E1-3.
23. Subbiah S, Nahar U, Samujh R, Bhansali A. Heterosexual precocity: rare manifestation of virilizing adrenocortical oncocytoma. Ann Saudi Med 2013; 33:294-7.
24. Kawahara Y, Morimoto A, Onoue A, Kashii Y, Fukushima N, Gunji Y. Persistent fever and weight loss due to an interleukin-6-producing adrenocortical oncocytoma in a girl--review of the literature. Eur J Pediatr 2014; 173:1107-10.
25. Yoon JH, Cha SS, Yoon SK. Computed tomography and magnetic resonance images of adrenocortical oncocytoma cases. J Korean Med Sci 2014; 29:445-51.
26. Akin M, Erginel B, Tanik C, et al. The first laparoscopic resection of an aldosterone-secreting adrenocortical oncocytoma in a child. J Pediatr Surg Case Rep 2014; 2: 424-7.
27. Ranganathan S, Lynshue K, Hunt JL, Kane T, Jaffe R. Unusual adrenal cortical tumor of unknown biologic potential: a nodule in a nodule in a nodule. Pediatr Dev Pathol 2005; 8:483-8.

28. Mardi K. Virilizing adrenocortical oncocytic neoplasm with uncertain malignant potential in a child: A rare case report Indian J Cancer 2016; 53:203-4.

29. Chen GX, Zhang XS, Li ZH, Gong ZQ. Clinicopathological Features and Minimal Invasive Management of Oncocytic Adrenal Neoplasm. Zhongguo Weichuangwaike Zazhi 2018; 18:694-8.

30. Yordanova G, Iotova V, Kalchev K, et al. Virilizing adrenal oncocytoma in a 9-year-old girl: rare neoplasm with an intriguing postoperative course. J Pediatr Endocrinol Metab 2015; 28:685-90.

31. Pereira BD, Rios ES, Cabrera RA, Portugal J, Raimundo L. Adrenocortical oncocytoma presenting as Cushing's syndrome: an additional report of a paediatric case. Endocr Pathol 2014; 25:397-403.

32. Kolev NY, Tonev AY, Ignatov VL, et al. The role of 3-D endorectal ultrasound in rectal cancer: our experience. Int Surg 2014; 99:106-11.

33. Agarwal S, Agarwal K. Rare pediatric adrenocortical carcinoma with oncocytic change: a cytologic dilemma. Endocr Pathol 2011; 22:40-3.