Table-1

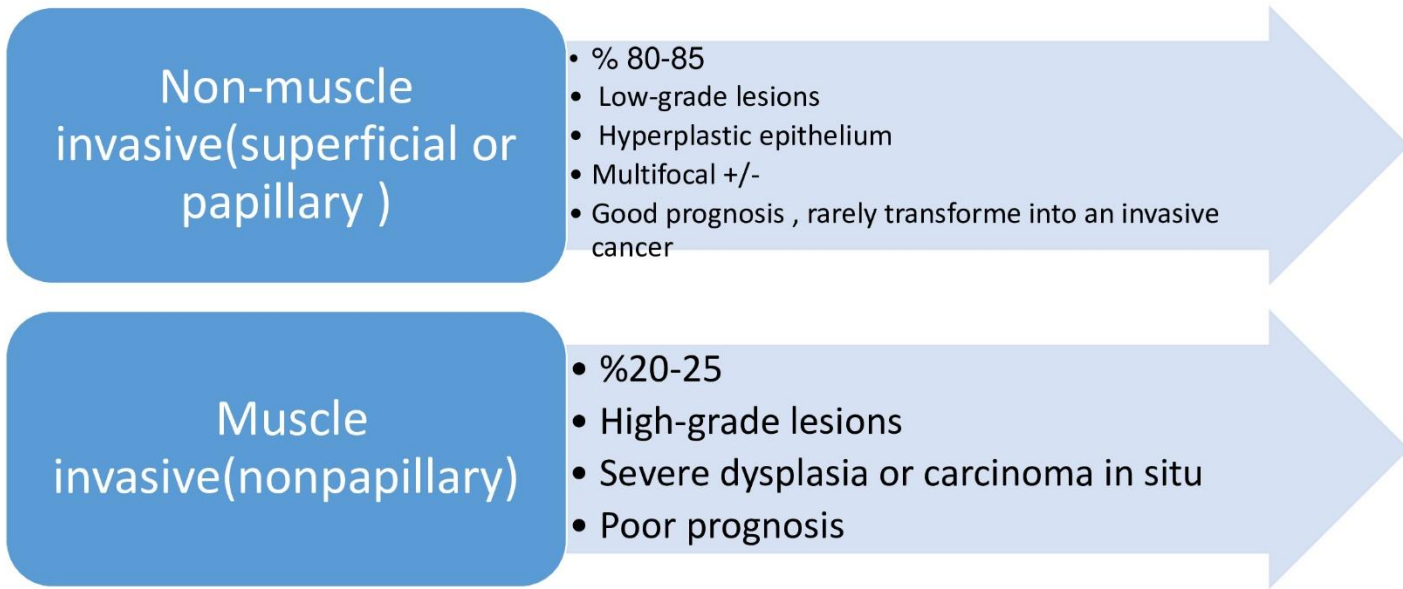
Non-muscle invasive(superficial or papillary)
% 80-85
Low-grade lesions
Hyperplastic epithelium
Multifocal +/-
Good prognosis , rarely transforme into an invasive cancer
Muscle invasive(nonpapillary)
%20-25
High-grade lesions
Severe dysplasia or carcinoma in situ
Poor prognosis

Table-2

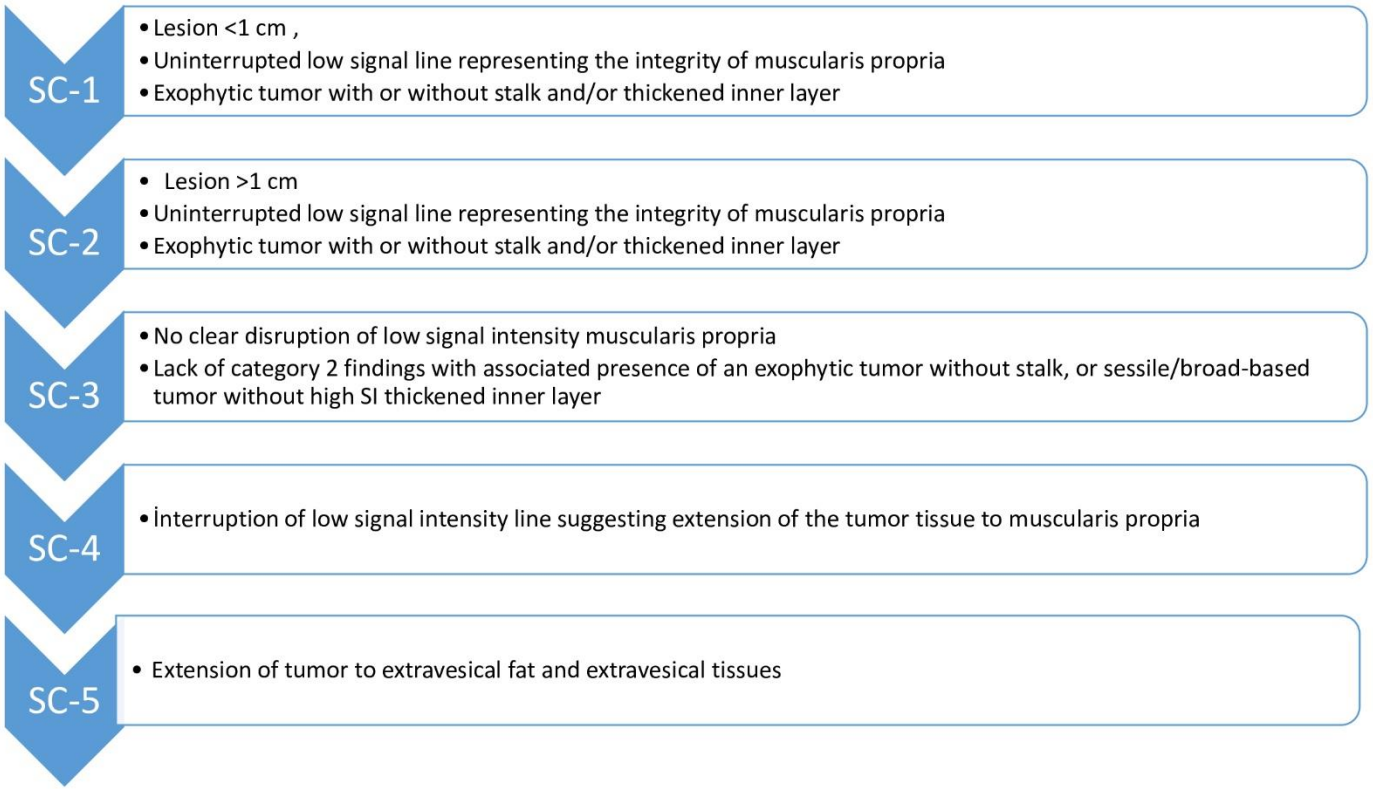
SC-1
• Lesion <1 cm ,
• Uninterrupted low signal line representing the integrity of muscularis propria
• Exophytic tumor with or without stalk and/or thickened inner layer
SC-2
• Lesion >1 cm
• Uninterrupted low signal line representing the integrity of muscularis propria
• Exophytic tumor with or without stalk and/or thickened inner layer
SC-3
• No clear disruption of low signal intensity muscularis propria
• Lack of category 2 findings with associated presence of an exophytic tumor without stalk, or sessile/broad-based tumor without high SI thickened inner layer
SC-4
• İnterruption of low signal intensity line suggesting extension of the tumor tissue to muscularis propria
SC-5
• Extension of tumor to extravesical fat and extravesical tissues

Table-3

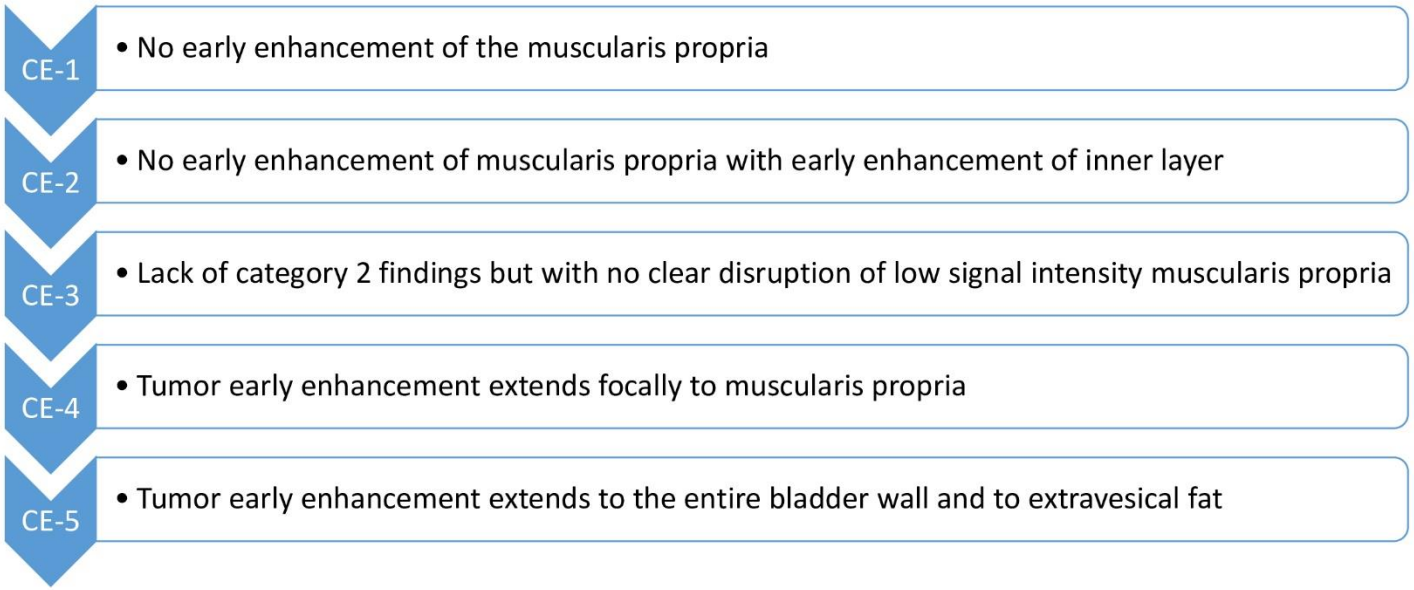
CE-1
• No early enhancement of the muscularis propria
CE-2
• No early enhancement of muscularis propria with early enhancement of inner layer
CE-3
• Lack of category 2 findings but with no clear disruption of low signal intensity muscularis propria
CE-4
• Tumor early enhancement extends focally to muscularis propria
CE-5
• Tumor early enhancement extends to the entire bladder wall and to extravesical fat

Table-4

DW-1	• Muscularis propria with intermediate continuous signal intensity on DWI (Lesion <1 cm , hyperintense on DWI and hypointense on ADC)
DW-2	• Muscularis propria with intermediate continuous signal intensity on DWI (Lesion >1 cm , hyperintense on DWI and hypointense on ADC)
DW-3	• Lack of category 2 findings but with no clear disruption of low signal intensity muscularis propria
DW-4	• High signal intensity tumor on DWI and low signal intensity tumor on ADC extending focally to muscularis propria
DW-5	• High signal intensity tumor on DWI and low signal intensity tumor on ADC extending to the entire bladder wall and extravesical fat

Figure.1

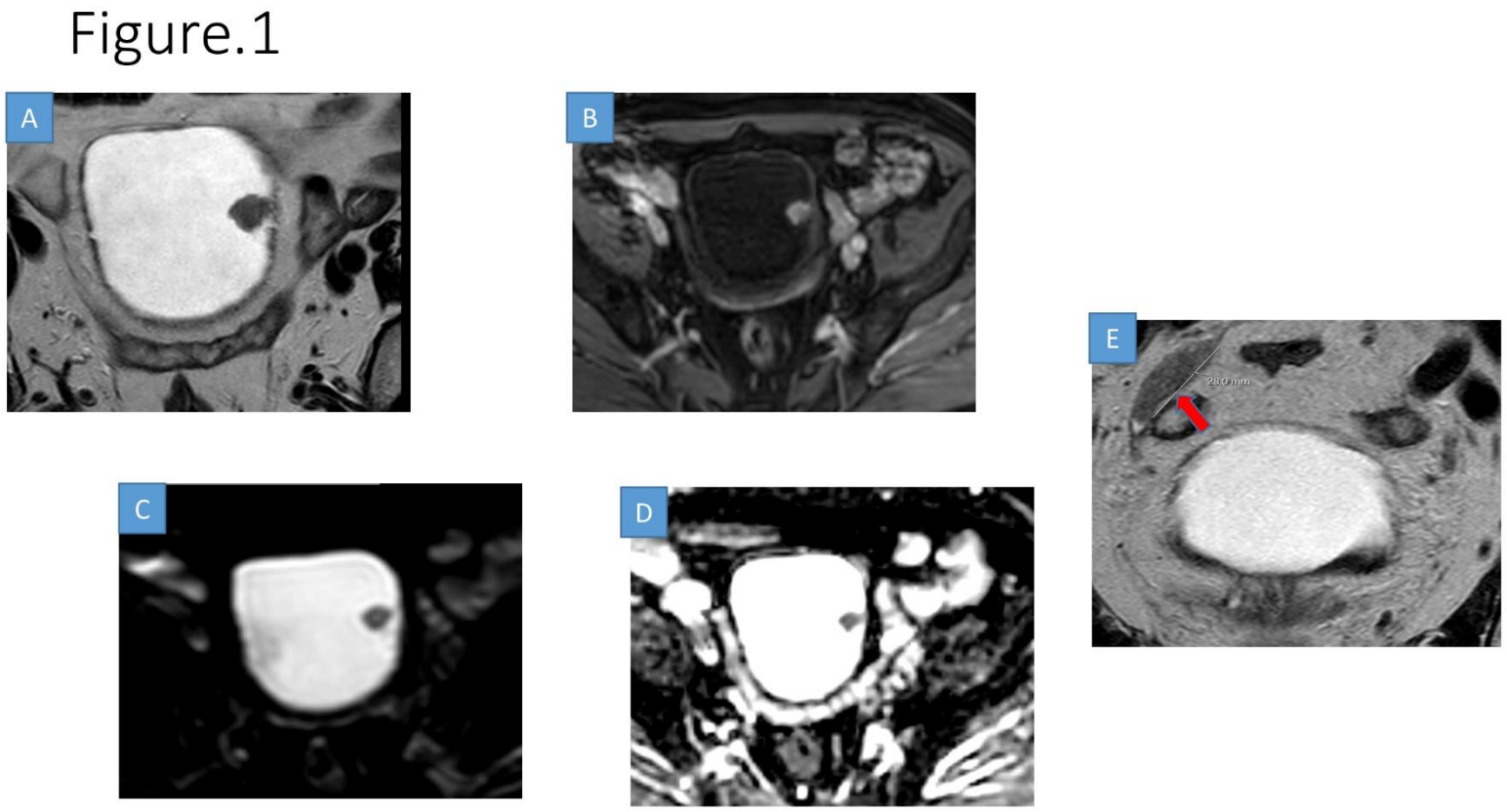

Figure.2

Figure.2

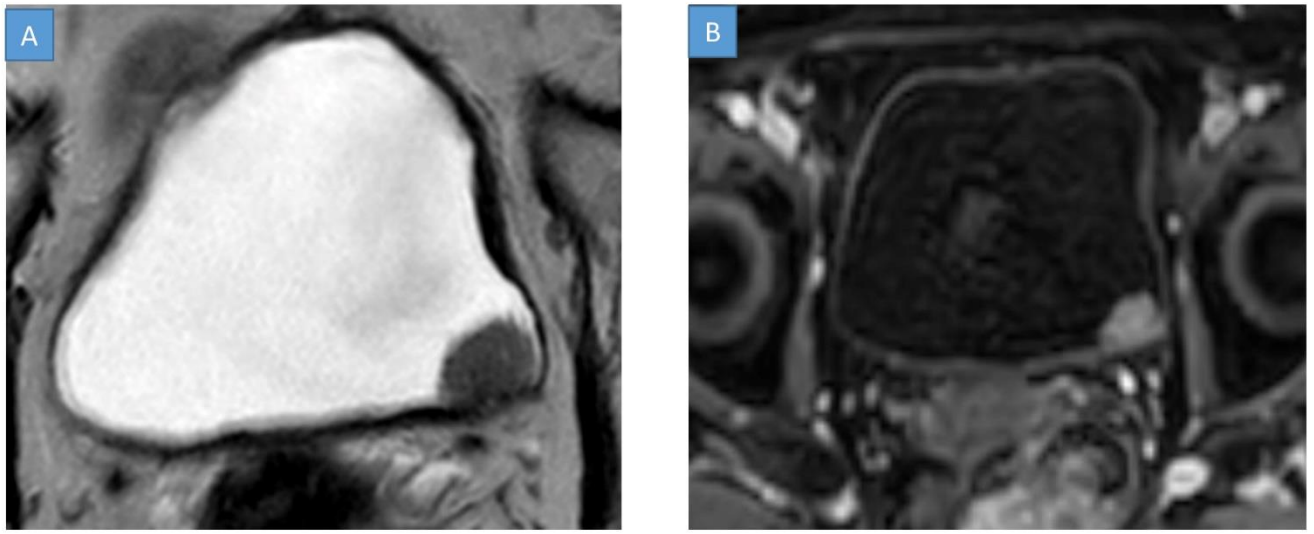

Figure.3

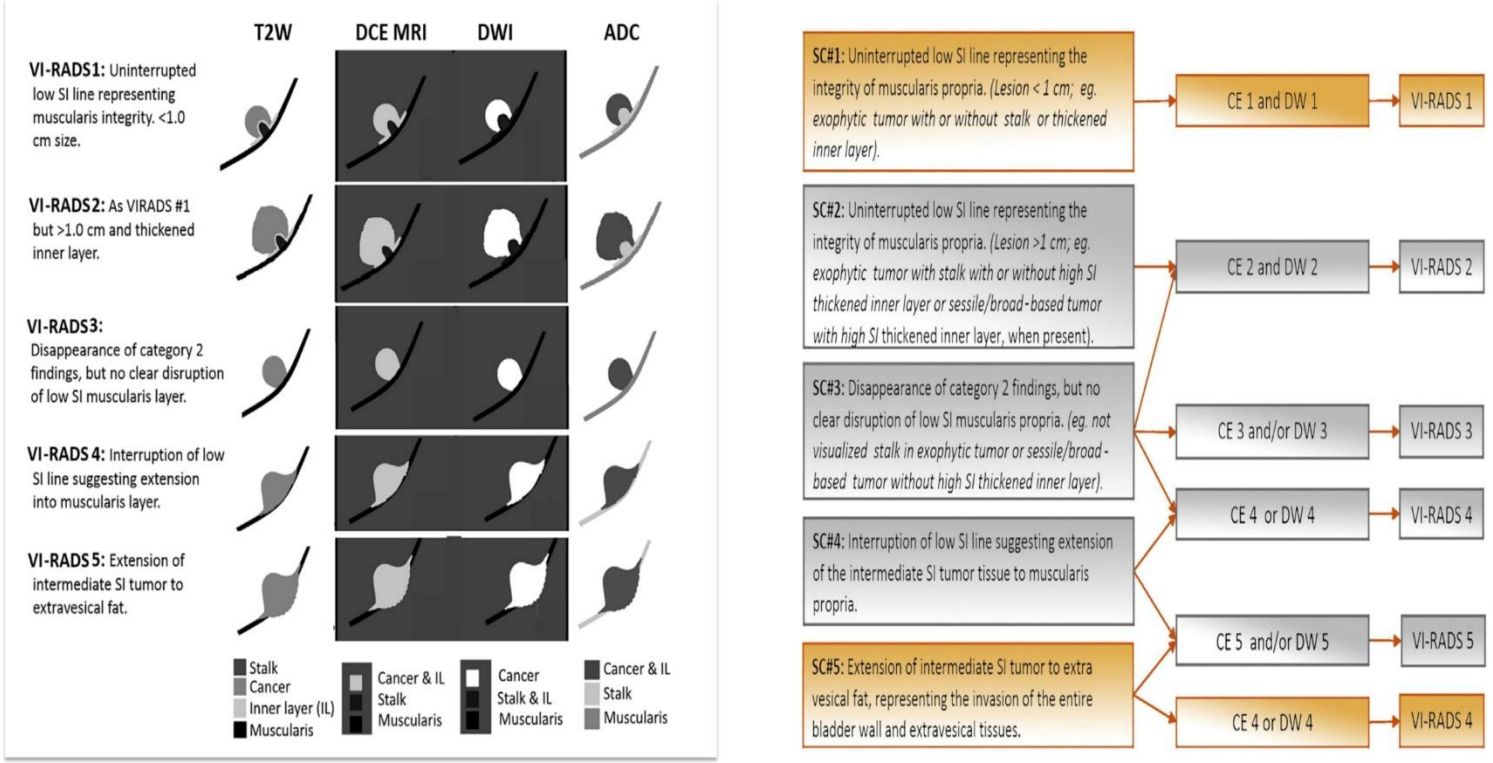

Multiparametric Magnetic Resonance Imaging for Bladder Cancer: Development of VI-RADS (Vesical Imaging-Reporting And Data System). Eur Urol (2018)

Figure.4

Figure-4

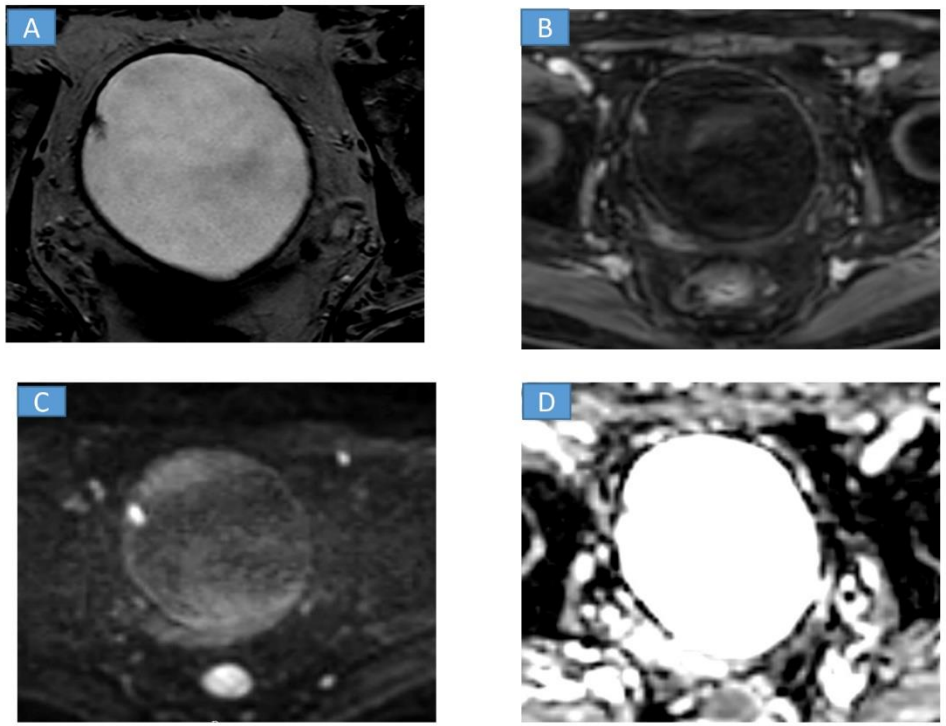

Figure.5

Figure -5

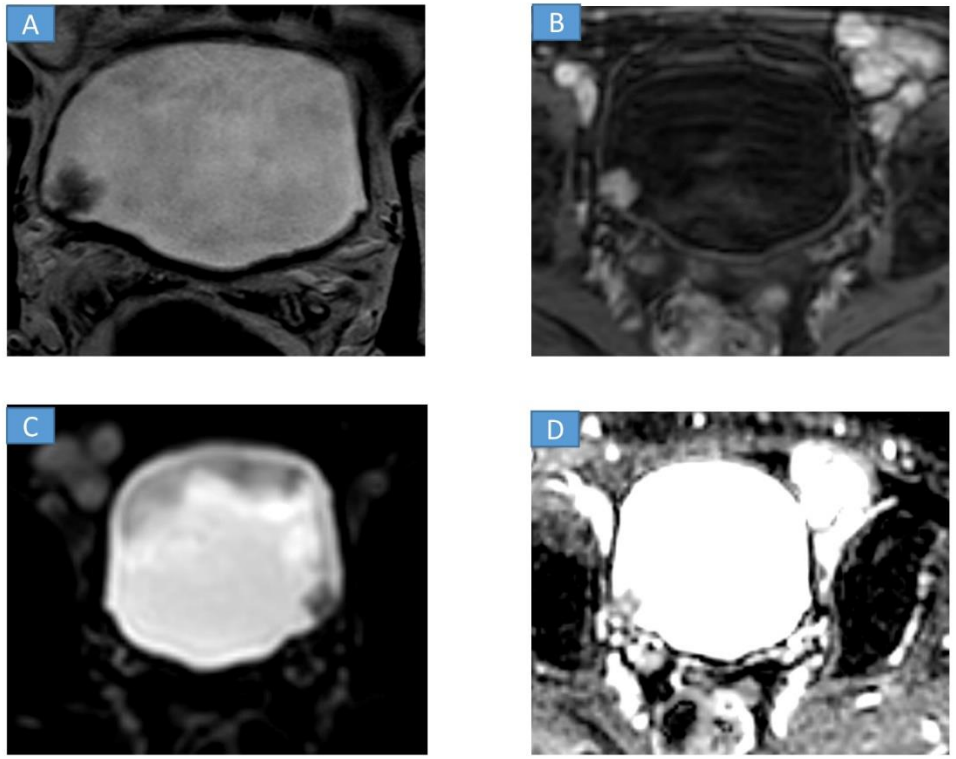

Figure.6

Figure-6

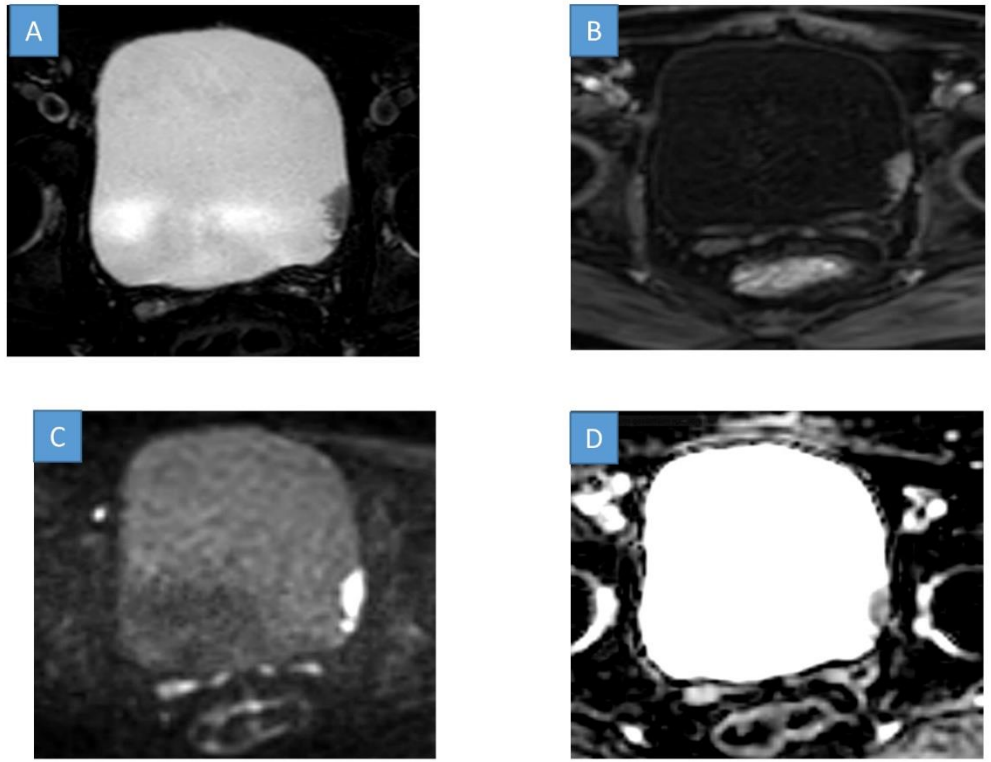

Figure.7

Figure-7

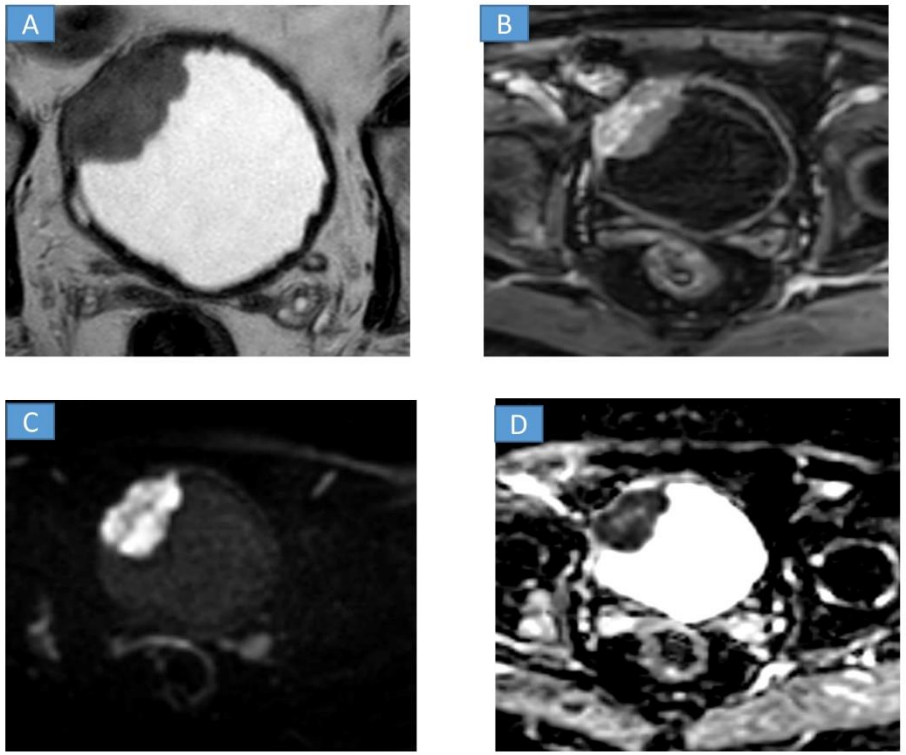

Figure.8

Figure-8

