SAĞLIK BİLİMLERİ ÜNİVERSİTESİ

II. ULUSLARARASI katılımlı Anesteziyoloji ve Reanimasyon Sempozyumu



SAĞLIK BİLİMLERİ ÜNİVERSİTESİ
GÜLHANE EĞİTİM VE ARAŞTIRMA HASTANESİ
KONGRE MERKEZİ

ANKARA

2-3 ARALIK 2022

Güncelin Peşinde

BİLDİRİ ÖZETLERİ KİTABI

www.anestezisempozyumu.org

SAĞLIK BİLİMLERİ ÜNİVERSİTESİ

11. ULUSLARARASI katılımlı Anesteziyoloji ve Reanimasyon Sempozyumu

SAĞLIK BİLİMLERİ ÜNİVERSİTESİ
GÜLHANE EĞİTİM VE ARAŞTIRMA HASTANESİ
KONGRE MERKEZİ

ANKARA
2-3 ARALIK 2022

DÜZENLEME KURULU

DÜZENLEME KURULU



PROF.DR. AHMET COŞAR
SEMPOZYUM BAŞKANI



DOÇ. DR. MEHMET BURAK EŞKİN
GENEL SEKRETER



PROF. DR. NERMİN GÖĞÜŞ
DÜZENLEME KURULU ÜYESİ



PROF. DR. MURAT SAYIN
DÜZENLEME KURULU ÜYESİ



PROF. DR. SÜHEYLA ÜNVER
DÜZENLEME KURULU ÜYESİ



PROF. DR. HÜLYA BAŞAR
DÜZENLEME KURULU ÜYESİ



PROF. DR. HİLAL SAZAK
DÜZENLEME KURULU ÜYESİ

SAĞLIK BİLİMLERİ ÜNİVERSİTESİ

II. ULUSLARARASI katılımlı Anesteziyoloji ve Reanimasyon Sempozyumu

SAĞLIK BİLİMLERİ ÜNİVERSİTESİ
GÜLHANE EĞİTİM VE ARAŞTIRMA HASTANESİ
KONGRE MERKEZİ

ANKARA
2-3 ARALIK 2022

SEMPOZYUM PROGRAMI

SAĞLIK BİLİMLERİ ÜNİVERSİTESİ

II. ULUSLARARASI katılımlı Anesteziyoloji ve Reanimasyon Sempozyumu

02 ARALIK 2022 - CUMA

15:30 - 16:30	**Uluslararası Panel - 1: Sepsis in ICU (ÇEVRİMİÇİ)**	
	Oturum Başkanları: Hülya Türkan - Lale Karabıyık	
	Sepsis and Acute Kidney Injury	**Mustafa Al-Mashat**
	Sepsis and Acute Lung Injury	**Rhodri Hanslip**
	Sepsis Induced Cardiac Disfunction	**Syed Mohammad Shahab Naqvi**
16:30 - 17:00	**Kahve Molası**	
17:00 - 18:00	**Uluslararası Panel - 2: Anesthesia (ÇEVRİMİÇİ)**	
	Oturum Başkanları: Onur Özlü - Murat Sayın	
	Patient Safety	**Jasmina Smajic**
	Perioperative Medicine	**Rudin Domi**
	Anesthesia in Emergency Surgery	**Andrijan Kartalov**

SAĞLIK BİLİMLERİ ÜNİVERSİTESİ

II. ULUSLARARASI katılımlı Anesteziyoloji ve Reanimasyon Sempozyumu

03 ARALIK 2022 - CUMARTESİ

08:30 - 09:00	**Açılış Oturumu**	
09:00 - 09:30	**Sosyal Konferans**	
	Oturum Başkanı: Ülkü Aypar	
	Serbest Konuşma	**Erdal Güzeldemir**
09:00 - 10:00	**SÖZLÜ SUNU OTURUMU - 1 (B Salonu)**	
	Oturum Başkanı: Ender Sir	
S-002	Postoperative Residual Curarization of Geriatric Patients in the Recovery Unit: A Prospective, Observational Study	**Emine Sönmez**
S-003	Effect of Laryngoscopy Technique on Intubation Procedure: Manikin Study	**Sinan Değirmencioğlu**
S-004	The Effect of Patient Positioning on Advanced Cardiac Parameters in Laparoscopic and Open Major Abdominal Cancer Surgery	**Mustafa Kemal Şahin**
S-005	A Rare Complication: Gas Embolism Developed During Operation of Laparoscopic Bilateral Inguinal Herniorrhaphy	**Gülten Sağır**
S-006	Our Experiences In Non-Operating Room Anesthesia In Pediatric Magnetic Resonance Imaging Cases	**Murat Kaykaç**
S-007	Sevoflurane-Associated Diffuse Alveolar Hemorrhage, Case Report	**Funda Atar**

S-008	The Effects of Intraoperative Different Fluid Therapy Protocols on Postoperative Renal Functions	**Nisan Taş**
S-009	Turkish Delight Was Killing; An Interesting Case Report of Negative Pressure Pulmonary Edema	**Onur Küçük**
S-010	Our Nicardipine Experiences in Intracranial Hemorrhages Admitted to the Intensive Care Unit From the Emergency Department	**Ayşe Ayyıldız**
09:30 - 09:45	**Kahve Molası**	
09:45 - 11:15	**Panel - 1: Özellikli İşlemlerde Anestezi**	
	Oturum Başkanları: Nermin Göğüş - Vedat Yıldırım	
	Robotik Cerrahi	**İsmail Aytaç**
	Bariatrik Cerrahi	**Gaye Aydın**
	Minimal İnvaviz Girişimler	**Gökhan Özkan**
	Transplante Hastaların Cerrahisinde Anestezi	**Behiç Girgin**
	Tek Akciğer Ventilasyonu	**Hilal Sazak**

SAĞLIK BİLİMLERİ ÜNİVERSİTESİ

III. ULUSLARARASI katılımlı Anesteziyoloji ve Reanimasyon Sempozyumu

10:15 - 11:15	SÖZLÜ SUNU YARIŞMASI (B Salonu)	
	Jüri Başkanı: Taylan Akkaya **Jüri Üyeleri: Ali Alagöz, Hatice Yağmurdur, Serkan Şenkal, Süheyla Ünver**	
Y-001	The Role of Proadrenomedullin, Interleukin 6, and Neutrophil CD64 in the Diagnosis and Prognosis of Septic Shock	**Yasemin Bozkurt Turan**
Y-002	The Relationship Between Gastric Ultrasound Findings and Endoscopically Aspirated Volume in Infants and Determination of Antral Cut-Off Value for the Diagnosis of Empty Stomach	**Feyza Sever**
Y-003	Effects of Fullerenol C60 on Liver Tissue in Liver Ischemia Reperfusion Injury in Rats Undergoing Sevoflurane Anesthesia	**Çağrı Özdemir**
Y-004	Tocilizumab's Effect In Treating Severe COVID-19	**Sevda Onuk**
Y-005	The Effect of Insulin Requirement on Mortality and Morbidity in Non-Diabetic Covid-19 Patients in the Intensive Care Unit	**Kadir Yeşildal**
Y-006	The Prediction of Hemodynamic Unstability by Increasing Values of Perfusion Index (PI) and Pleth Variable Index (PVI) After Spinal Block in Elective Cesarean Section	**Esma Çalışkan**
Y-007	Comprasiın Of The Analgesic Efficacy Of Retrolaminar Block And Erector Spina Plane Block In Lumbar Disc Surgery	**Veli Ateş**

Y-008	Retrospective Comparison of the Efficacy of Bupivacaine at Two Different Doses in the Erector Spina Plane Block Applied With Ultrasonography for Pain Control in Laparoscopic Cholecystectomy Cases	**Arzu Yıldırım Ar**
Y-009	A Comparison of the Effectiveness of the Pericapsular Nerve Group(PENG) Block and Suprainguinal Fasia Iliaca Compartment Block (SFICB) in Prevention of Spinal Anesthesia Positioning Pain in Orthopedic Hip Surgery Case	**Müslüm Akkılıç**
Y-010	Evaluation of Quality of Life, Sleep Quality, Functional Status, Respiratory Functions in The Post-Covid Period of Patients Followed in The Intensive Care Unit Due To COVID-19	**Gamze Güler**
11:15 - 11:30	**Kahve Molası**	
11:30 - 13:00	**Panel - 2: Perioperatif Yönetim**	
	Oturum Başkanları: Ömer Kurtipek - Mustafa Aksoy	
	Havayolu Yönetimi	**Jülide Ergil**
	Kan Yönetimi	**Hülya Yiğit Özay**
	Sıvı Yönetimi	**Türkay Çakan**
	Kan Basıncı Yönetimi	**Engin Alaygut**
	KPR	**Zeynep Nur Akçaboy**

SAĞLIK BİLİMLERİ ÜNİVERSİTESİ

III. ULUSLARARASI katılımlı Anesteziyoloji ve Reanimasyon Sempozyumu

11:30 - 12:30	SÖZLÜ SUNU OTURUMU - 2 (B Salonu)	
	Oturum Başkanı: Mehtap Tunç	
S-011	Questionnaire on the Impact of COVID-19 Pandemic, Socioeconomic Status and Working Conditions on Emigration of Research Assistants and Specialist Doctors of the Department of Anesthesiology and Reanimation	**Ülkü Ceren Köksoy**
S-012	Anesthesia Management Of Embryonal Posterior Fossa Tumor Excision In An Infant: Case Report	**Mine Akın**
S-013	Anesthesia Management In A Patient With A Difficult Airway Due To A Giant Thyroid Mass	**Sena Sarıcaoğlu Öktem**
S-014	Anesthesia Experience in Infant with Congenital Heart Block	**Kübra Kaya Güney**
S-015	COVID-19 Associated Pulmonary Aspergillosis Cases in Intensive Care Units	**Demet Bölükbaşı**
S-016	Evaluation of The Effect of Two Different Anesthesia Managements on Intracranial Pressure With Ocular Usg in (ERCP) Procedure	**Melike Demir**
S-017	Evaluation of Publications From Turkey on Low Flow Anesthesia	**Emine Aslanlar**
S-018	Our Airway Management in a Patient with an Obstructive Polypoid Lesion in the Vocal Cord	**Burçin Nur Bayındır**
S-019	The Effect of Combined Serratus Anterior Block on Postoperative Analgesia and Morphine Consumption in Three Cases of Mastectomy	**Esra Onhan Tekoğlu**
S-020	Anaesthetic Management Of A Case Of Duchenne Muscle Dystrophy With Williams Syndrome	**Turgut Çelik**

SAĞLIK BİLİMLERİ ÜNİVERSİTESİ

II. ULUSLARARASI katılımlı Anesteziyoloji ve Reanimasyon Sempozyumu

13:00 - 13:45	**Öğle Yemeği**	
13:30 - 14:30	**SÖZLÜ SUNU OTURUMU -3 (B Salonu)**	
	Oturum Başkanı: Ayşe Özcan	
S-021	Determination of COVID-19-Associated Sarcopenia by Measurements Made from Thoracal Tomography	**Nazan Has Selmi**
S-022	Anesthesia Management in Laparoscopic Bariatric Surgery: A Retrospective Analysis	**Nuran Akıncı Ekinci**
S-024	Difficult Airway Management in Patient with Achondroplasia	**Asena İrem Yıldız**
S-025	Our Case of Cerebral Salt Wasting Syndrome(CSWS) in Intensive Care Unit After Epidural Hematoma(EH) Drainage	**Ali Koç**
S-026	Intraoperative Hiccups During Tympanaplasty Surgery	**Alpay Karaçam**
S-027	Modified Radical Mastectomy with PECS Block in a Patient with Advanced Pulmonary Hypertension: Case Report	**Güldeniz Argun**
S-028	Management of a Case Developing Resistant Anaphylactic Shock in Hydatid Cyst Surgery	**Osman Kaya**
S-029	Anesthesia Management With Femoral And Popliteal Block Combination In The Case That Does Not Accept Central Regional Block Application	**Sena Sarıcaoğlu Öktem**
S-030	Anesthesia Management in a Spinal Muscular Atrophy Type 3: A Case Report	**Burak Nalbant**
S-031	Determination of Preoperative Anxiety and Depression Levels of Patients Scheduled to Have Elective Surgery	**Eda Macit Aydın**

SAĞLIK BİLİMLERİ ÜNİVERSİTESİ

III. ULUSLARARASI katılımlı Anesteziyoloji ve Reanimasyon Sempozyumu

13:45 - 15:15	Panel - 3 : Rejyonal Anestezi ve Ağrı	
	Oturum Başkanları: Neslihan Alkış - Mehmet Emin Orhan	
	Plan A Blokları	**Derya Özkan**
	Ekstremite Bloklarında Yenilikler	**Mehmet Burak Eşkin**
	RA ve Antikoagülan Kullanımı	**Ayşın Ersoy**
	Doğum Analjezisi	**Berrin Günaydın**
	Kanser Ağrısı	**Gonca Oğuz**
14:45 - 15:45	**SÖZLÜ SUNU OTURUMU - 4 (B Salonu)**	
	Oturum Başkanı: Emine Arık	
S-032	Anaesthetic Management of a Case of Crisponi Syndrome	**Turgut Çelik**
S-033	The Effects of Different Anesthesia Applications on Emotion, Depression and Anxiety Levels in Burn Patients	**Emine Sönmez**
S-034	Airway Management in an Adult Patient who Operated for Arnold-Chiari Type I: Combined Use of Videolaryngoscopy and Elastic Gum Boogie, and VIDIAC Score	**Umut Cahit Ersoy**
S-035	Our Non-cardiac Surgery Experience in a Patient with LVAD: Multidisciplinary Approach	**Efe Volga Özkan**
S-036	Combined Axillary Brachial Plexus Block and Spinal Anesthesia in Selected Patient	**Esra Onhan Tekoğlu**
S-037	Anesthesia Management of A Newborn With Prolonged QT İnterval And Operated For İntestinal Atresia: A Case Report	**Hülya Kaşıkara**

SAĞLIK BİLİMLERİ ÜNİVERSİTESİ

II. ULUSLARARASI katılımlı Anesteziyoloji ve Reanimasyon Sempozyumu

S-038	Our Pediatric Supraclavicular Brachial Plexus Nerve Block(SBPB) Procedure	**Ali Koç**
S-039	Complicated Pleural Effusion as a Rare Complication in Stevens-Johnson Syndrome: Case Report	**Onur Küçük**
S-040	The Effects of Hypertension in Operating Room on Intraoperative and Postoperative Hemodynamics	**Bengü Kocaman**
S-041	Intraoperative Hiccups During Tympanaplasty Surgery	**Alpay Karaçam**
S-042	Awake Intubation Experience In a Patient With Cervical Fracture Secondary to trauma	**Ahmet Furkan Gürel**
15:15 - 15:30	**Kahve Molası**	
15:30 - 17:00	**Panel - 4 : Yoğun Bakım**	
	Oturum Başkanları: Osman Ekinci - Hülya Başar	
	Sepsiste Hemodinamik Yönetim	**Belgin Akan**
	Covid'den Sonra ARDS'de Neler Öğrendik?	**Güldem Turan**
	Yoğun Bakımda Oksijenizasyon	**Nedim Çekmen**
	Kritik Hastada Nutrisyon Hedefleri	**Çetin Kaymak**
	Yoğun Bakımda Purifikasyon Yöntemleri	**Mustafa Kemal Bayar**
17:00 - 17:30	**Akılcı İlaç Oturumu**	
		Ahmet Coşar
17:30 - 17:45	**Kapanış Oturumu**	

SAĞLIK BİLİMLERİ ÜNİVERSİTESİ
GÜLHANE EĞİTİM VE ARAŞTIRMA HASTANESİ KONGRE MERKEZİ
ANKARA
2-3 ARALIK 2022

SAĞLIK BİLİMLERİ ÜNİVERSİTESİ

II. ULUSLARARASI katılımlı Anesteziyoloji ve Reanimasyon Sempozyumu

SAĞLIK BİLİMLERİ ÜNİVERSİTESİ
GÜLHANE EĞİTİM VE ARAŞTIRMA HASTANESİ
KONGRE MERKEZİ

ANKARA
2-3 ARALIK 2022

SÖZLÜ SUNU YARIŞMASI

Pub No: Y-001

The Role of Proadrenomedullin, Interleukin 6, and Neutrophil CD64 in the Diagnosis and Prognosis of Septic Shock

Yasemin Bozkurt Turan[1]

[1]Marmara University, Faculty of Medicine

INTRODUCTION - PURPOSE: Sepsis and septic shock are disorders of tissue perfusion and microcirculation associated with increased mortality. The role of biomarkers such as proadrenomedullin (PRO-ADM), interleukin 6 (IL-6) and neutrophil CD64 (CD64) in the diagnosis and prognosis of septic shock has been studied.

MATERIALS AND METHODS: GCS, SOFA score, APACHE 2 score, lactate, CRP, procalcitonin, PRO-ADM, IL-6, CD64 level and 28-day mortality were evaluated in patients with septic shock followed-up in the intensive care unit of Marmara University Hospital between June 2021 and June 2022. The study was planned as prospective, non-drug clinical research (Ethics Committee Approval Number: 09.2021.701).

RESULTS: There were no statistically significant differences between patient groups in gender, BMI, and presence of comorbidities ($p > 0.05$). The alive patient group had significantly higher GCS values and lower SOFA, APACHE 2, lactate and CD64 values than the dead patient group ($p < 0.01$) (Table 1).The cut-off values of laboratory parameters were determined using ROC analysis to predict mortality, SOFA and CD64 had high AUC. This is also a good indicator for mortality (Table 2 and Figure 1).The multivariate logistic regression model was estimated using the backward selection method. The mortality of ICU patients was predicted by a SOFA-value ≥12 (OR (95%CI) = 56.13 (5.44 - 578.64)), CD64 value ≥28.54 (OR (95% CI) = 23.78 (2.61 - 216.85)), and ADM-value ≥86.79 (OR (95% CI) = 15.86 (1.02 - 246.49)) ($p < 0.05$) (Table 3).

Figure 1. ROC curves of laboratory parameters to predict mortality

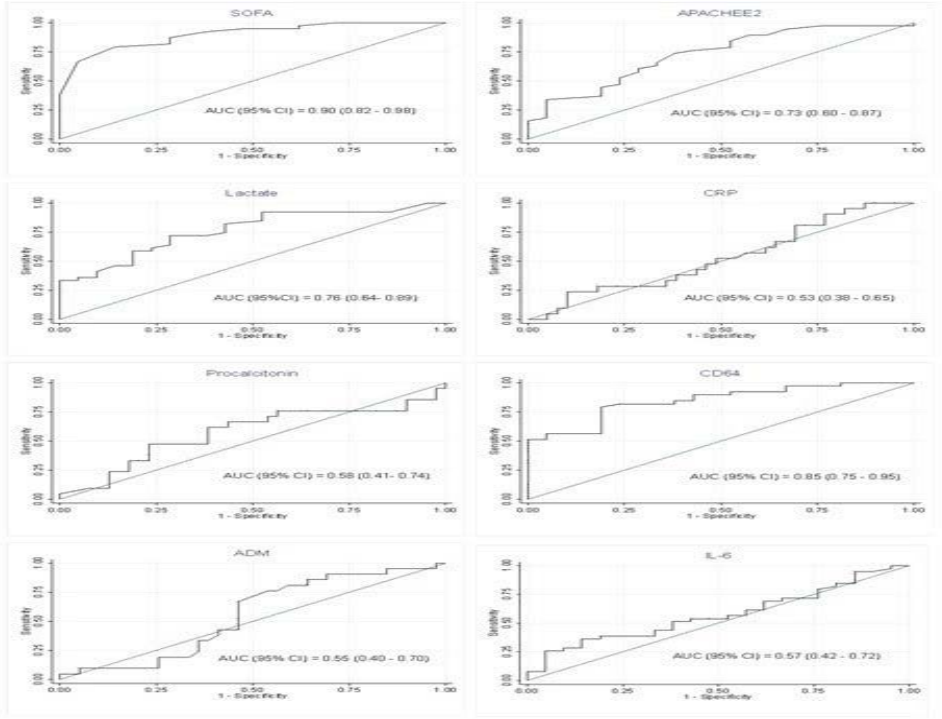

Table 1. Clinical characteristics of ICU patients

Clinical characteristics		Overall (n=60)	Alive (n=21)	Dead (n=39)	p-value; test statistics
Age, years, *median (IQR)*		70 (58 – 77)	60 (56 – 68)	74 (62 – 80)	**0.003;** MU=408.00
Gender, *n (%)*	Male	36 (60.0)	11 (30.6)	25 (69.4)	0.337; Chi-square=0.781
	Female	24 (40.0)-	10 (41.7)	14 (58.3)	
BMI, *median (IQR)*		27 (23 – 29)	28 (24 – 31)	26 (23 – 28)	0.181; MU=408.00
Diagnosis, *n (%)*	Respiratory	28 (46.7)	2 (7.1)	26 (92.9)	**<0.001**; Chi-square=21.381
	Malignity	14 (23.3)	8 (57.1)	6 (42.9)	
	Surgical	4 (6.7)	4 (100.0)	0 (0.0)	
	Other	14 (23.3)	7 (50.0)	7 (50.0)	
Comorbidity, *n (%)*	Yes	48 (80.0)	17 (35.4)	31 (64.6)	0.892; Chi-square=0.018
Malignity, *n (%)*	Yes	8 (13.3)	5 (62.5)	3 (37.5)	0.079; Chi-square=3.079
Hypertension, *n (%)*	Yes	29 (48.3)	9 (31.0)	20 (69.0)	0.433; Chi-square=0.615

Diabetes mellitus, *n (%)*	Yes	16 (26.7)	6 (37.5)	10 (62.5)	0.831; Chi-square=0.046
Cardiovascular disease, *n (%)*	Yes	16 (26.7)	4 (25.0)	12 (75.0)	0.286; Chi-square=1.139
BMI≥30, *n (%)*	Yes	12 (20.0)	7 (58.3)	5 (41.7)	0.058; Chi-square=3.590
Other, *n (%)*	Yes	8 (13.3)	2 (25.0)	6 (75.0)	0.500; Chi-square=0.455
Mortality (28-days, in ICU)		38 (63.3)			
GCS, *median (IQR)*		4 (3 – 10)	10 (3 – 15)	3 (3 – 6)	**0.007;** MU=571.50
SOFA, *mean ± SD*		10.9 ± 4.1	7.3 ± 3.6	12.9 ± 2.9	**<0.001;** t=-6.614
APACHE 2, *mean ± SD*		22.8 ± 9.8*	17.8 ± 8.3	25.5 ± 9.5**	**0.003;** t=-3.130
Lactate, *median (IQR) mmol/L*		3 (2 – 5)	2 (1 – 3)	4 (2 – 9)	**<0.001;** MU=194.00
CRP, *median (IQR) mg/L*		141 (75 – 225)	143 (82 – 257)	140 (69 – 219)	0.704; MU=434.50
Procalcitonin, *median (IQR) µg/L*		4 (1 – 13)	6 (3 – 17)	3 (1 – 9)	0.340; MU=471.50
CD64, *median (IQR) ng/ml*		32 (23 – 50)	22 (13 – 28)	45 (30 – 63)	**<0.001;** MU=124.50
PRO-ADM, *median (IQR) pmol/L*		104 (87 – 139)	110 (101 – 122)	101 (75 – 144)	0.540; MU=449.50
IL-6, *median (IQR) pg/ml*		77 (43 – 853)	76 (44 – 250)	108 (42 – 1137)	0.360; MU=215.50

*n=59, **n=38

Table 2. Cut-off values and AUC values of the laboratory parameters

Parameter	AUC (95% CI)	Cut-off value
SOFA	0.90 (0.82 – 0.98)	12
APACHE 2	0.73 (0.60 – 0.87)	20
Lactate	0.76 (0.64 -0.89)	1.9
CRP	0.53 (0.38 – 0.68)	45.2
Procalcitonin	0.58 (0.41 – 0.74)	2.61
CD64	0.85 (0.75 – 0.95)	28.54
PRO-ADM	0.55 (0.40 – 0.70)	86.79
IL-6	0.57 (0.42 – 0.72)	23.82

Table 3. Multivariate logistic regression model predicting overall mortality in ICU patients

Parameter (reference)	B	S.E.	OR (95% CI)	p
SOFA ≥12 (ref. <12)	4.03	1.19	56.13 (5.44 – 578.64)	**0.001**
CD64 ≥28.54 (ref. <28.54) ng/ml	3.17	1.13	23.78 (2.61 – 216.85)	**0.005**
PRO-ADM ≥86.79 (ref. <86.79) pmol/L	2.76	1.40	15.86 (1.02 – 246.49)	**0.048**
constant	-3.18	1.10	0.041	0.004

DISCUSSION - CONCLUSION: It was determined that PRO-ADM, CD64, and SOFA score can predict mortality. The diagnostic significance of PRO-ADM for mortality (1) and of CD64 (2) and IL-6 (3) for sepsis has been shown previously.While PRO-ADM, CD64, and SOFA score predicted mortality in septic shock, IL-6 did not.

Keywords: Septic shock, PRO-ADM, CD64, IL-6, intensive care

Pub No: Y-002

The relationship between gastric ultrasound findings and endoscopically aspirated volume in infants and determination of antral cut-off value for the diagnosis of empty stomach

Feyza Sever[1], Sengül Özmert[1], Selim Dereci[2]

[1]Ankara City Hospital, Anesthesiology and Reanimation Department
[2]Ankara City Hospital, Pediatric Gastroenterology Department

INTRODUCTION - PURPOSE: Pulmonary aspiration of gastric content is a serious perioperative complication. Bedside gastric ultrasound examination is increasingly used in children. The objective of this prospective study was to assess the relationship between the cross-sectional area (CSA) of the antrum measured by gastric ultrasound and gastric volumes suctioned endoscopically, also to determine the best cut-off value of CSA for empty antrum in the pediatric population less than 24 months of age.

MATERIALS AND METHODS: This study was performed in Pediatric Gastrointestinal (GI) Endoscopy Unit after receiving Institutional Ethics Board approval. Following induction of anaesthesia, antral sonography was performed in supine and right lateral decubitus (RLD) positions in 46 fasted infants prior to upper GI endoscopic evaluation. Antral CSA measurements in both positions and the qualitative evaluation of the antrum (according to the 3-point grading system) were recorded. Gastric contents were endoscopically suctioned and measured.

Figure 1



Sonographic appearance of the antrum with an empty stomach

RESULTS: Forty six patients (under the age of 24 months) were included. There was a significant correlation between aspirated volume and CSA RLD, age, BMI (p= 0.003, p= 0.013 and p= 0.017 respectively). As the CSA RLD, age, and BMI values increased, the aspirated gastric volume also increased. According to tree-point qualitative grading system 76,1% of patients were classified as grade 0 and 23,9 % of infants were grade 1. The best cut-off value of CSA RLD in distinguishing the empty antrum is 2,406 cm2 and at this cut-off value the sensitivity is 100% and the specificity is 68.6%.

Table 1

	Grade 0 (n=35)	Grade 1 (n=11)	P value
Total volume (ml)	0.31 ± 0.47	5.5 ± 5.0	< 0.001
Volume per unit of weight ($ml.kg^{-1}$)	0.03 ± 0.05	0.45 ± 0.27	<0.001
Supine CSA (cm^2)	1.25 ± 0.69	1.71 ± 1.10	0.105
RLD CSA (cm^2)	2.10 ± 1.04	3.58 ± 1.32	<0.001

Suctioned volumes and CSA supine and CSA RLD according to the qualitative grading system

DISCUSSION - CONCLUSION: Qualitative exam of the antrum by gastric ultrasound can be a very valuable non-invasive tool that provides reliable information. The RLD position is the optimal position to diagnose an empty antrum. An antral CSA cut-off value of 2,406 cm2 in the RLD position presents with acceptable performance in the ability to discriminate an empty antrum in infants.

Keywords: Anesthesia, infant, gastric ultrasound, empty stomach

Pub No: Y-003

Effects of fullerenol C60 on liver tissue in liver ischemia reperfusion injury in rats undergoing sevoflurane anesthesia

Aydın Yavuz[1], Ayça Taş Tuna[2], Çağrı Özdemir[3], Tülay Mortaş[4], Ayşegül Küçük[5], Esat Kasapbaşı[3], Mustafa Arslan[6], Mustafa Kavutçu[7], Ömer Kurtipek[3]

[1]Gazi University, Faculty of Medicine, Department of General Surgery, Ankara, Turkey
[2]Sakarya University, Faculty of Medicine, Department of Anesthesiology and Reanimation, Sakarya, Turkey
[3]Gazi University, Faculty of Medicine, Department of Anesthesiology and Reanimation, Ankara, Turkey
[4]Kırıkkale University, Faculty of Medicine, Department of Histology and Embryology, Kırıkkale, Turkey
[5]Kütahya Health Sciences University, Faculty of Medicine, Department of Medical Physiology, Kütahya, Turkey
[6]Institution 1, Gazi University, Faculty of Medicine, Department of Anesthesiology and Reanimation, Ankara, Turkey; Institution 2, Gazi University, Life Sciences Application and Research Center, Ankara, Turkey
[7]Gazi University, Faculty of Medicine, Department of Biochemistry, Ankara, Turkey

INTRODUCTION - PURPOSE: Liver ischemia-reperfusion (IR) injury is a major complication of liver surgery including liver transplantation, liver resection and trauma. Therefore, different types of antioxidants and procedures have been developed to reduce cellular damage secondary to IR. Sevoflurane, an inhalation anesthetic, was demonstrated to have a protective effect against liver IR injury. The aim of this study was to investigate the effects of fullerenol C60 on rat liver tissue in liver IR injury model undergoing sevoflurane anesthesia to evaluate the ability of nanoparticles to prevent hepatic complications.

MATERIALS AND METHODS: After approval of the Ethics Committee, a total of 36 adult female Wistar Albino rats were divided into six groups each containing six as follows: sham group (Group S), the fullerenol C60 group (Group FC60), the ischemia-reperfusion group (Group IR), and the ischemia-reperfusion-sevoflurane group (Group IR-Sevo), ischemia-reperfusion-fullerenol C60 group (Group IR-FC60), ischemia-reperfusion-fullerenol C60-sevoflurane group (Group IR-FC60-Sevo). Fullerenol C60 100 mg/kg was administrated in Group IR-FC60 and IR-FC60-Sevo (1,2). In IR groups 2 hours of ischemia and 2 hours of reperfusion were performed. At the end of the reperfusion, liver tissues were removed for biochemical assays, and histopathological examinations. ANOVA test was used in independent groups. Bonferroni test was used when differences occured.

RESULTS: Hepatocyte degeneration, sinüsoidal dilatation, prenecrotic cell, MN celluler infiltration in the parenchyma were significantly higher in Group IR than all other groups ($p<0.005$) (Table 1, Figure). TBARS level was significantly higher in Group IR than other

groups and the lowest TBARS level was in Group IR-FC60 than other groups except Group S and FC60. CAT and GST activities reduced in Groups IR than all other groups ($p<0.005$) (Table 2).

Figure

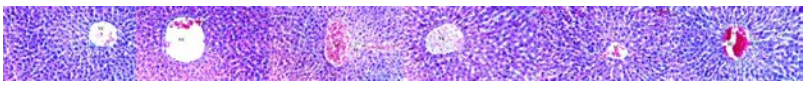

(from left to right) 1: Light microscopic view of liver tissue of Group C; Normal liver tissue (HL: hepatic lobules; VC: vena centralis; k: kupffer cell hyperplasia; *: sinusoid dilatation; ↓↓: infiltration; →: hepatocyte; c: dikaryotic hepatocytes; e: erythrocyte), H&EX100 Figure 2: Light microscopic view of liver tissue of Group FC60; Normal liver tissue (HL: hepatic lobules; VC: vena centralis; e: erythrocyte; con: congestion; *: sinusoid dilatation; →: hepatocyte; c: dikaryotic hepatocytes; ↓↓: infiltration), H&EX100 Figure 3: Light microscopic view of liver tissue of Group IR (HL: hepatic lobules; VC: vena centralis; e: erythrocyte; con: congestion; *: sinusoid dilatation; ↓↓: infiltration; dikaryotic hepatocytes; inf: inflammation; (*): necrotic and apoptotic appearance in hepatocytes; dej: hydrophilic degeneration), H&EX100 Figure 4: Light microscopic view of liver tissue of Group IR-Sevo (HL: hepatic lobules; VC: vena centralis; *: sinusoid dilatation; ↓↓: infiltration; →: hepatocyte; k: kupffer cell hyperplasia; (*): necrotic and apoptotic appearance in hepatocytes), H&EX100 Figure 5: Light microscopic view of liver tissue of Group IR-FC60 (HL: hepatic lobules; VC: vena centralis; con: congestion; *: sinusoid dilatation; ↓↓: infiltration; →: hepatocyte; c: dikaryotic hepatocytes; k: kupffer cell hyperplasia; dej: hydrophilic degeneration; con: congestion), H&EX100 Figure 6: Light microscopic view of liver tissue of Group IR-FC60-Sevo (HL: hepatic lobules; VC: vena centralis; e: erythrocyte; *: sinusoid dilatation; ↓↓: infiltration; →: hepatocyte; k: kupffer cell hyperplasia; (*): necrotic and apoptotic appearance in hepatocytes), H&EX100

Table 1: The comparison of histological changes in rat hepatic tissue [Mean ± SD]

Histological Change	Group S (n=6)	Group FC60 (n=6)	Group IR (n=6)	Group IR-Sevo (n=6)	Group IR-FC60 (n=6)	Group IR-FC60-Sevo (n=6)	P**
Hepatocyte degeneration	0.33±0.21*	0.50±0.22*	2.00±0.37	1.00±0.37*	0.50±0.22*	0.83±0.31*	0.004
Sinusoidal dilatation	0.33±0.21*	0.33±0.21*	1.83±0.31	0.83±0.31*	0.67±0.21*	0.83±0.31*	0.004
Pycnotic nucleus	0.33±0.21	0.50±0.22	1.17±0.31	0.67±0.21	0.33±0.21	0.50±0.22	0.147
Prenecrotic cell	0.17±0.17*	0.33±0.21*	1.50±0.22	1.00±0.26	0.50±0.22*	0.83±0.31	0.004

Mononuclear cellular infiltration in the parenchyma	0.33±0.21*	0.33±0.21*	1.67±0.33	1.00±0.26	0.67±0.33*	0.83±0.31*	0.021

p**: Statistical significance was set at a p value < 0.05 for ANOVA test *p<0.05: When compared with Group IR

Table 2: Oxidative state parameters in rat hepatic tissue [Mean ± SD]

	Group S (n=6)	Group FC60 (n=6)	Group IR (n=6)	Group IR-Sevo (n=6)	Group IR-FC60 (n=6)	Group IR-FC60-Sevo (n=6)	P**
TBARS (nmol/mL)	0.40±0.04*	0.48±0.06*	1.45±0.26	0.76±0.17*	0.53±0.07*	0.62±0.08*	<0.0001
CAT (IU/mg.pro)	2.88±0.50*	2.34±0.41*	0.90±0.15	1.60±0.40	2.40±0.37*	1.88±0.37	0.013
GST (IU/mg.pro)	0.67±0.18*	0.53±0.12*	0.06±0.02	0.32±0.12	0.59±0.15*	0.44±0.11*	0.025

p**: Statistical significance was set at a p value < 0.05 for ANOVA test *p<0.05: When compared with Group IR

DISCUSSION - CONCLUSION: Fullerenol C60 has protective effects against liver IR injury in rats under sevoflurane anesthesia. The use of fullerenol C60 could reduce the adverse effects of IR injury and associated costs in liver transplantation surgery.

Keywords: Fullerenol C60, Nanoparticle, Ischemia reperfusion, Sevoflurane, Liver

Pub No: Y-004

Tocilizumab's Effect In Treating Severe COVID-19

Sevda Onuk[1]

[1]Department of intensive Care, Kayseri Training and Research Hospital, Kayseri, Turkey

INTRODUCTION - PURPOSE: Tocilizumab, an interleukin-6 receptor blocker, has been used in inflammatory phase of COVID-19, but its effect on critically ill patients remains unclear.Study aims is to investigate clinical effect of tocilizumab and its mortality effect in patients receiving IC due to severe COVID-19.

MATERIALS AND METHODS: Study was conducted retrospectively on COVID-19 patients with positive PCR test in pandemic ICU of Kayseri City Hospital on August 1, 2020-October 31, 2021. Pregnant patients and patients under 18 years of age were excluded from study. (Ethics Committee Decision No:714, Date:11.10.2022)Patients were divided as receiving tocilizumab and corticosteroid (8mg Dekort or 40-80mg methylprednisolone) and not receiving tocilizumab but corticosteroids (8mg Dekort or 40-80mg methylprednisolone). Both groups were compared by demographic data, comorbidities, admission characteristics, laboratory values, hospital mortality, length of stay in hospital and ICU.

RESULTS: 60 patients, 29 receiving tocilizumab and 31 not receiving tocilizumab, were included in study. Patients were 44-88 years of age, and ages of patients receiving tocilizumab were statistically lower than not receiving tocilizumab (p=0.034)Groups had a statistically similar distribution in terms of BMI, diabetes, hypertension, coronary artery disease, cerebrovascular disease, chronic renal failure, chronic lung disease, liver disease and malignity. Groups had a statistically similar distribution in terms of acute kidney injury, vasopressor, length of stay in hospital and ICU.Hospitalization values of ferritin, LDH, hemoglobin and GCS of patients receiving tocilizumab were statistically higher than not receiving tocilizumab. PaO2/FiO2, CHARLSON score and SOFA hospitalization values of patients receiving tocilizumab were statistically lower than not receiving tocilizumab.Upon comparing patients receiving and not receiving tocilizumab, there wasn’t significant difference in HM (p=0.672)Tocilizumab did not affect mortality according to age and gender-adjusted and unadjusted values.

Evaluation of Tocilizumab's effect on mortality by binary logistic regression analysis

Regression Coefficients							
						For *OR*95%*CI*	
	β	*Standard error.*	Wald Statistics	*p*	*OR*	Lower Limit	Upper Limit
Constant	-0.194	0.361	0.289	0.591	0.824		
Tocilizumab	0.402	0.519	0.599	0.439	1.495	0.540	4.136
Regression Coefficients*							
						For *OR*95%*CI*	
	β	*Standard error.*	Wald Statistics	*p*	*OR*	Lower Limit	Upper Limit
Constant	-5.011	2.034	6.071	0.014	0.007		
Tocilizumab	0.789	0.627	1.586	0.208	2.202	0.644	7.525

DISCUSSION - CONCLUSION: Upon comparing patients receiving and not receiving tocilizumab, no difference was found regarding ICU and hospital stay and mortality.

Keywords: Severe COVID-19 pneumoni, tocilizumab, steroids, intensive care

Pub No: Y-005

The Effect of Insulin Requirement on Mortality and Morbidity in Non-Diabetic Covid-19 Patients in the Intensive Care Unit

Kadir YEŞİLDAL[1], Fethi GÜLTOP[1], Cansu KILINÇ BERKTAŞ[1], Müslüm AKKILIÇ[1], Namigar TURGUT[1]

[1]Prof. Dr. Cemil Taşçıoğlu Şehir Hastenesi

INTRODUCTION - PURPOSE: In this study, it was aimed to investigate the effect of insulin requirement on mortality and morbidity in non-diabetic COVID-19 patients followed in the intensive care unit and the correlation between insulin requirement and the severity of the disease

MATERIALS AND METHODS: 161 patients without DM diagnosis, who were hospitalized in the intensive care unit (ICU) with COVID-19, were included in the study. The patients were compared as those who requirement insulin for more than 24 hours (Group I;n=88) and those who did not (Group II;n=73).Demographic datas, risk scores, time of initiation and duration and dose of insulin and corticosteroid, mechanical ventilator (MV) need were evaluated, and mortality and DM diagnoses at 1. 3. and 6. months were investigated.

RESULTS: Group I patients had higher SOFA, APACHE-II, and SAPS-II ($p=0.001$,$p<0.001$,$p=0.041$,respectively).Non-invasive MV days ($p<0.001$), the need for invasive mechanical ventilation ($p=0.022$), and invasive MV ventilator days were also statistically longer in Group I patients.No effect of the type of corticosteroid used on insulin requirement was observed, but insulin requirement was found to be higher in patients who were administered >1 mg/kg/day methylprednisolone and equivalent dose dexamethasone ($p=0.002$).6-month mortality was higher in Group I. While the 6-month diagnosis rate of newly diagnosis DM was 4.2% in Group II, it was 31.1% in Group I ($p<0.001$).

DISCUSSION - CONCLUSION: Increased insulin requirement in non-diabetic COVID-19 patients is associated with increased 6-month mortality.Regardless of the type of corticosteroid used, the use of more than 1 mg/kg/day of methylprednisolone or equivalent dose of dexamethasone appears to further impair blood sugar regulation and increase insulin requirement.In COVID-19 patients, insulin requirement occurs as a result of corticosteroid use, pancreatic beta cell damage directly caused by SARS-CoV-2, stress hyperglycemia due to hyperinflammation, and a high rate of newly diagnosed DM is seen after discharge.These patients should be followed closely and evaluated for anti-diabetic therapy.

Keywords: Insulin, hyperglycemia, corticosteroid, COVID-19

Pub No: Y-006

The Prediction of Hemodynamic Unstability by Increasing Values of Perfusion Index (Pi) and Pleth Variable Index (Pvi) After Spinal Block in Elective Cesarean Section

Esma ÇALIŞKAN[1], Öznur ULUDAĞ[1], Mevlüt DOĞUKAN[1], Mehmet DURAN[1], Fadime TOSUN[1], Mehmet TEPE[1]

[1]ADIYAMAN ÜNİVERSİTESİ TIP FAKÜLTESİ

INTRODUCTION - PURPOSE: It is important to predict the negative consequences of hypotension that develops after spinal anesthesia on the mother and newborn, in order to take precautions. Perfusion index and pleth variability index can be measured with pulse oximetry. In our study; We compared the patient groups with and without hypotension in predicting hemodynamic deterioration after spinal anesthesia in patients who will undergo elective cesarean section, and investigated the usability and superiority of PI and PVI values for early intervention.

Perfusion Index Measurement Device



MATERIALS AND METHODS: 113 pregnant women aged between 18-40 years with ASA 1-2 were included in our study. PI, PVI values in the supine and sitting positions, PI and PVI values at the 1st, 2nd, 3rd, and 4th minutes after spinal anesthesia and postpartum PI, PVI values were recorded. Electrocardiography, non-invasive blood pressure measurements and

pulse measurement were performed for hemodynamic monitoring, and changes in systolic pressure, diastolic pressure and heart rate were recorded before and after spinal anesthesia.

RESULTS: In basal values of PI and PVI after spinal anesthesia and the rate of change of these values; There was no significant difference between the groups with and without hypotension. Hemoglobin (p=0.014) and hematocrit (p=0.012) were significantly lower in those who developed hypotension. The 1st minute APGAR (p=0.005= and 5th minute APGAR (p=0.014) scores were significantly lower in the babies of the pregnant women who developed hypotension. There was no significant change in PI and PVI values in patients who failed spinal anesthesia.

DISCUSSION - CONCLUSION: It has been determined that following the PI and PVI values will not provide the expected benefit and these values do not have a diagnostic advantage over each other. However, the increase in PI value after spinal anesthesia application indicates the success of spinal block. In addition, it has been determined that low hemogram and hematocrit values increase the risk of developing hypotension.

Keywords: Hypotension, Perfusion index, Pleth Variability Index, Spinal Anesthesia

Pub No: Y-007

Comprasiın of the Analgesic Efficacy of Retrolaminar Block and Erector Spina Plane Block in Lumbar Disc Surgery

Veli ATES[1], Emine ARIK[1], Derya OZKAN[1], Ö. Taylan AKKAYA[1], Burak NALBANT[2]

[1]University of Health Sciences, Dışkapı Yıldırım Beyazıt Training and Research Hospital, Anaesthesiology and Reanimation Clinic
[2]Ankara Yildirim Beyazit University Ankara City Hospital Anesthesiology and Reanimation Clinic

INTRODUCTION - PURPOSE: The aim of this study was to compare the analgesic efficacy of Erector spina plane (ESP) block and retrolaminar block (RLB) with the control group in lumbar disc surgery.

MATERIALS AND METHODS: ASA I-III, 75 patients were divided into ESP, RLB, and Control groups.Ultrasound guided ESP and RL blocks were performed bilaterally. Intravenous patient-controlled analgesia was used for postoperative analgesia in patients who underwent standard general anesthesia.Postoperative analgesic efficacy was evaluated at 0, 2, 4, 8, 12, and 24 hours using numerical rating scale the at rest (NRS-r) and motion (NRS-m).Tramadol consumption and additional analgesic requirement was recorded. Intraoperative opioid consumption, hemodynamic variables, complications and overall satisfaction of the patients were compared.

RESULTS: In the ESP and RLB groups's tramadol consumption was lower than control group in all measurements time (p=0.002, p=0.001). Postoperative rest pain scores of the groups were similar except at 0, 2, 8, and 24 hours; while 0th, 2nd, and 24th-hour NRS-r values were lower in the ESP Group than RLB and Control Group (p=0.001, p=0.001, p=0.029), 12th-hour NRS-r values were found to be lower in the ESP and RLB Group than the Control Group (p=0.028, p=0.027). NRS-m value at the 0th hour was lower in the ESP and RLB Group than in the Control Group (p=0.001, p=0.007). The 2nd and 12th-hour NRS-m values were lower in the ESP Group than in the RLB and Control Group (p=0.042, p=0.040). In the ESP and RLB Group intraoperative remifentanil consumption was lower than Control Group (p<0.001, p<0.001).

DISCUSSION - CONCLUSION: ESPB and RLB method are superior to the control group in terms of postoperative analgesic efficacy, as they provide less intraoperative remifentanil and postoperative tramadol consumption in lumbar disc surgery. In addition, the analgesic efficacy of the ESP group was shown to be superior to the RLB group.

Keywords: Retrolaminar Block, Erector Spinae Plane Block, Lumbar Vertebra Surgery

Pub No: Y-008

Retrospective Comparison of the Efficacy of Bupivacaine at Two Different Doses in the Erector Spina Plane Block Applied with Ultrasonography for Pain Control in Laparoscopic Cholecystectomy Cases

Dicle KOCAÖZ[1], Arzu YILDIRIM AR[1], Yildiz YİĞİT[1], Mehmet Timuçin AYDIN[2], Süheyla ABİTAĞAOĞLU[1]

[1]University of Health Sciences Fatih Sultan Mehmet Health Application and Research Center,Anesthesiology and Reanimation Department
[2]University of Health Sciences Fatih Sultan Mehmet Health Application and Research Center, General Surgery Department

INTRODUCTION - PURPOSE: Erector spina plane block(ESPB) is used as a part of multimodal analgesia in different surgical procedures(1,2).We aimed to retrospectively compare the effect of two different doses of bupivacaine in bilateral ESPB applied with ultrasonography(USG) in postoperative pain control in patients who underwent laparoscopic cholecystectomy(LC).

MATERIALS AND METHODS: After the approval of the ethics committee(24.03.2022-47), 60 patients of the American Society of Anesthesiologist(ASA)I-III, who had undergone LC between 01/09/2021-01/02/2022 were included in the study.Patients who were followed up with only patient-controlled analgesia without block were defined as Group I, patients who were administered ESPB with 0.25% bupivacaine, Group II,and patients who were administered with0.125% concentration were defined as Group III, and 20 patients were included in each group.Visual Analog Scale(VAS), Verbal Rating Scale(VRS),the amount of opioid consumed peroperatively, morphine consumed postoperatively and additionally consumed analgesics were recorded.

RESULTS: The total amount of morphine consumed postoperatively in Group I was higher than Group II-III(Table1).The 5th,15th,30th and 2nd hour recovery VAS scores of Group I were found to be higher than Group II(Table2).The 5th, 15th, 30th and 2nd, 4th hour recovery VRS scores of Group I were higher than group II(Table3).The amount of intraoperative opioid consumed in Group I was found to be higher than Group II-III(Table4).

Table 1: Evaluation of Morphine Amounts Consumed in the Postoperative Period by Groups

Table 1: Evaluation of Morphine Amounts Consumed in the Postoperative Period by Groups

AnalgesiaMeasurements		Grup I	Grup II	Grup III	p
Compilation 5. min	Mean±Ss	0,50±0,51	0,40±0,50	0,30±0,47	d0,441
	Median	0,5	0	0	
	(Min-Maks)	(0-1)	(0-1)	(0-1)	
Compilation 15. min	Mean±Ss	0,98±0,47	0,33±0,47	0,45±0,51	d0,001**
	Median	1	0	0	
	(Min-Maks)	(0-1,5)	(0-1)	(0-1)	
Compilation 30. min	Ort±Ss	1,48±0,53	0,53±0,50	0,70±0,47	d0,001**
	Medyan	1,5	0,8	1	
	(Min-Maks)	(0-2)	(0-1)	(0-1)	
Postoperative 1. hour	Mean±Ss	2,33±1,16	1,45±1,32	1,80±1,28	d0,134
	Median	2	1,5	2	
	(Min-Maks)	(1-4,5)	(0-4)	(0-5)	
Postoperative 2. hour	Mean±Ss	2,85±1,42	1,35±1,53	1,55±1,28	d0,004**
	Median	3	1	2	
	(Min-Maks)	(1-6)	(0-5)	(0-4)	
Postoperative 4. hour	Mean±Ss	2,65±1,69	1,30±1,42	2,35±1,79	d0,035*
	Median	2	1	2	
	(Min-Maks)	(0-6)	(0-4)	(0-5)	
Postoperative 6. hour	Mean±Ss	2,03±1,49	0,50±1,00	1,30±1,30	d0,001**
	Median	2	0	1,5	
	(Min-Maks)	(0-5)	(0-4)	(0-4)	
Postoperative 12. hour	Mean±Ss	0,95±1,43	0±0	0,30±0,92	d0,004**
	Median	0	0	0	
	(Min-Maks)	(0-4)	(0-0)	(0-4)	
Postoperative 24. hour	Mean±Ss	0±0	0±0	0±0	-
	Median	0	0	0	
	(Min-Maks)	(0-0)	(0-0)	(0-0)	
Total consumed	Mean±Ss	13,08±4,59	5,90±2,38	8,40±3,05	d0,001**
	Median	14	6,5	8	
	(Min-Maks)	(4-23)	(2-10)	(2-15)	

*dKruskal Wallis Test &Dunn-Bonferroni Test*p<0,05**p<0,01*

Table 2: Evaluation of Postoperative Visual Analogue Scales by Groups

Table 2: Evaluation of Postoperative Visual Analogue Scales by Groups

VAS Scores		Grup I	Grup II	Grup III	p
Compilation 5. min	Mean±Ss	3,90±2,15	2,35±0,93	3,45±1,43	d0,009**
	Median	4	2	3	
	(Min-Maks)	(0-8)	(1-5)	(1-6)	
Compilation 15. min	Mean±Ss	3,60±1,67	2,50±0,89	3,25±1,07	d0,013*
	Median	3,5	2	3	
	(Min-Maks)	(0-7)	(1-4)	(1-5)	
Compilation 30. min	Mean±Ss	3,55±0,94	2,60±0,94	3,10±1,07	d0,011*
	Median	3,5	2	3	
	(Min-Maks)	(2-6)	(1-5)	(1-5)	
Postoperative 1. Hour	Mean±Ss	3,20±1,20	2,70±1,34	2,90±1,02	d0,321
	Median	3	2	3	
	(Min-Maks)	(1-6)	(1-6)	(1-5)	
Postoperatifve 2. hour	Mean±Ss	3,35±1,18	2,40±0,88	2,70±1,22	d0,032*
	Median	3,5	2	2,5	
	(Min-Maks)	(1-6)	(1-4)	(1-5)	
Postoperative4. hour	Ort±Ss	3,20±1,01	3,10±1,45	2,80±1,06	d0,438
	Medyan	3	3	3	
	(Min-Maks)	(1-5)	(1-6)	(1-5)	
Postoperative 6. hour	Mean±Ss	2,75±0,97	2,50±1,10	2,25±1,37	d0,200
	Median	3	2,5	2	
	(Min-Maks)	(1-4)	(1-5)	(1-6)	
Postoperative 12. hour	Mean±Ss	1,65±0,81	1,70±0,86	1,55±0,83	d0,870
	Median	2	1,5	1	
	(Min-Maks)	(0-3)	(1-4)	(0-3)	
Postoperative 24. hour	Mean±Ss	0,85±0,37	0,65±0,59	0,85±0,75	d0,400
	Median	1	1	1	
	(Min-Maks)	(0-1)	(0-2)	(0-3)	

*dKruskal Wallis Test &Dunn-Bonferroni Test*p<0,05**p<0,01* VAS:Visual Analog Scale

Table 3: Evaluation of Verbal Rating Scales in the Postoperative Period by Groups

Table 3: Evaluation of Verbal Rating Scales in the Postoperative Period by Groups

VRS Scores		Grup I	Grup II	Grup III	p
Compilation 5.min	Mean±Ss	2,00±1,08	1,30±0,66	1,80±0,70	d0,024*
	Median	2	1	2	
	(MinMaks)	(0-4)	(0-3)	(1-3)	
Compilation 15.min	Mean±Ss	2,05±0,89	1,35±0,59	1,55±0,60	d0,009**
	Median	2	1	2	
	(MinMaks)	(0-3)	(1-3)	(0-2)	
Compilation 30.min	Mean±Ss	1,95±0,76	1,35±0,67	1,50±0,69	d0,018*
	Median	2	1	1,5	
	(MinMaks)	(0-3)	(0-3)	(0-3)	
Postoperative 1.Hour	Mean±Ss	2,05±0,89	1,70±0,80	1,15±0,59	d0,003**
	Median	2	1,5	1	
	(MinMaks)	(0-3)	(1-3)	(0-2)	
Postoperative 2.Hpur	Mean±Ss	2,05±0,51	1,35±0,81	1,45±0,51	d0,017*
	Median	2	1	1	
	(MinMaks)	(0-4)	(0-3)	(1-2)	
Postoperative 4.Hour	Mean±Ss	2,15±0,93	1,35±0,67	2,00±0,86	d0,008**
	Median	2	1	2	
	(MinMaks)	(0-4)	(0-3)	(1-3)	
Postoperative 6.Hour	Mean±Ss	1,50±0,89	1,90±0,72	1,30±0,86	d0,067
	Median	1	2	1	
	(MinMaks)	(0-3)	(1-3)	(0-3)	
Postoperative 12.Hour	Mean±Ss	1,05±0,46	1,00±0,46	0,70±0,66	d0,184
	Median	1	1	1	
	(MinMaks)	(0-3)	(0-2)	(0-2)	
Postoperative 24.Hour	Mean±Ss	0,60±0,60	0,50±0,51	0,35±0,49	d0,376
	Median	1	0,5	0	
	(MinMaks)	(0-2)	(0-1)	(0-1)	

dKruskal Wallis Test &Dunn-Bonferroni Test*p<0,05**p<0,01VRS:VerbalRatingScale

Table 4: Comparison of Intraoperative Opioid Consumption

		Grup I (n=20)	Grup II (n=20)	Grup III (n=20)	p
İntraoperative Opioid Consumption (mcg)	*Mean±Ss*	225,35±54,59	160,25±42,90	182,00±41,71	a0,001**
	Median	215	158	173,5	
	(Min-Maks)	(150-320)	(96-260)	(110-264)	

aOneway ANOVA &Dunn-Bonferroni Test bPearsonChi-SquareTestcFisherFreemanHalton Test dKruskal Wallis Test&Dunn-Bonferroni Test**p<0,01

DISCUSSION - CONCLUSION: VAS and VRS scores were found to be significantly lower in the ESPB group applied with 0.25% concentration in patients who underwent LC operation compared to other groups.The amount of opioid consumed intraoperatively and postoperatively was lower in ESPB administered with 0.25%-0.125% bupivacaine compared to the control group.We observed that the quality of analgesia was better in ESPB applied at a concentration of 0.25%.

Keywords: Nerve block, Multimodal analgesia, Pain management, Laparoscopic cholecystectomy, Postoperative analgesia

Pub No: Y-009

A Comparison of the Effectiveness of the Pericapsular Nerve Group(Peng) Block and Suprainguinal Fasia Iliaca Compartment Block(Sficb) in Prevention of Spinal Anesthesia Positioning Pain in Orthopedic Hip Surgery Case

Müslüm AKKILIÇ[1], Onur OKUR[1], Kadir YEŞİLDAL[1], Cansu KILINÇ BERKTAŞ[1], Namigar TURGUT[1]

[1]İstanbul Prof. Dr. Cemil Taşcıoğlu Şehir Hastanesi

INTRODUCTION - PURPOSE: This study aimed to compare the effectiveness of preoperative ultrasonography-guided suprainguinal fascia iliaca compartment block(SFICB) and pericapsular nerve group block(PENG) block on positioning pain during spinal anesthesia in patients who were scheduled for hip surgery under spinal anesthesia.

MATERIALS AND METHODS: Following the ethics commitiee's approval fifty-two patients who were scheduled for hip surgery under spinal anesthesia and were performed either of the PENG(n=26) or SFICB(n=26), were included in this prospective observational study. Patients' baseline NRS scores were recorded right before the block, 15 minutes after the block, during the spinal anesthesia positioning, and at the postoperative 24th hour. Patients' demographics, sitting angle during spinal anesthesia positioning, and postoperative analgesic requirements were recorded and compared.

RESULTS: The demographics of the patients were similar between groups. There was no difference between NRS scores at any time between the groups(Figure-1). NRS scores were significantly lower in both groups at the 15th minute compared to the baseline NRS scores (Table-1)(P<df.01 for Group PENG; and P<.01 for Group SFICB). There was no difference between groups in NRS scores at the 15th minute and during spinal anesthesia(P=,10 for Group PENG; P=,06 for Group SFICB). The NRS scores were significantly lower at the 24th hour compared to baseline in in the PENG group (P<.01) while similar in the SFICB group(P=.08). There was no significant difference between the two groups in terms of sitting angle during spinal anesthesia in the sitting position(P=.06). There was no significant difference between the groups in terms of postoperative analgesic consumption.

Figure-1: Comparison of pain scores between groups

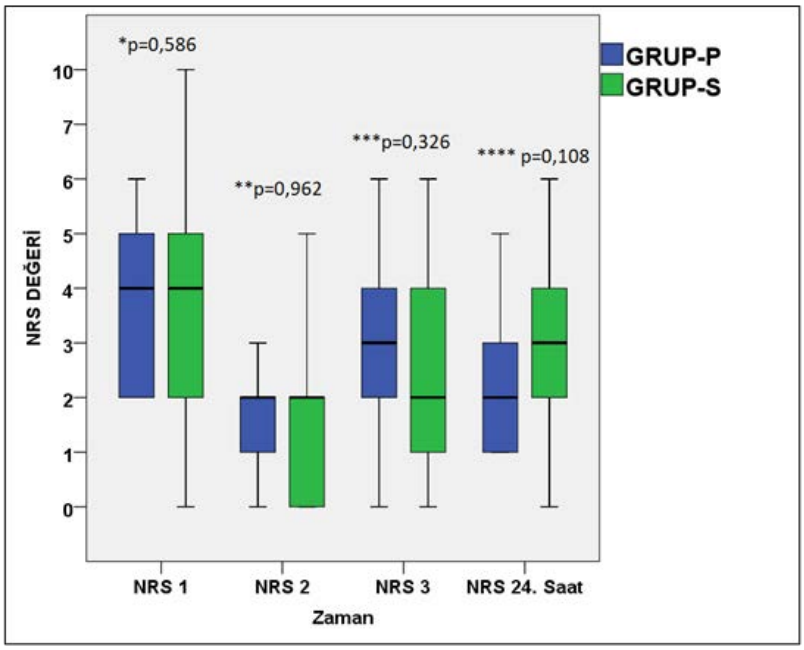

Table-1: Comparison of pain scores by time

	NRS1	NRS2	*P	NRS3	**P	NRS4	***P
Group-PENG	3,5(2-6)	1,5(0-3)	<0,001	3(0-6)	0,101	2(1-5)	0,002
Group-SFICB	3,5(0-10)	1,5(0-5)	<0,001	2(0-6)	0,063	3(1-6)	0,076

NRS1: baseline pain score, NRS2: Pain at the 15th min after the block, NRS3: pain at the sitting position, NRS4: pain at th postoperative 24th hour * NRS1-NRS2 difference ** NRS2-NRS3 difference ***NRS3-NRS4 difference

DISCUSSION - CONCLUSION: As a result, we found that PENG block and SFICB were similar in terms of analgesic effectiveness for positioning pain in patients undergoing hip fracture surgery under spinal anesthesia. We observed that both blocks provided effective preoperative analgesia in patients and prevented the increase in pain scores of patients during spinal anesthesia positioning.

Keywords: Spinal Anesthesia, Hip Fracture, Nerve Block, Sitting Position, Analgesia

Pub No: Y-010

Evaluation of Quality of Life, Sleep Quality, Functional Status, Respiratory Functions in The Post-Covid Period of Patients Followed in the Intensive Care Unit Due to Covid-19

Gamze Güler[1], Mesut Erbaş[1]

[1]Çanakkale Onsekiz Mart Üniversitesi Tıp Fakültesi Anesteziyoloji ve Reanimasyon Anabilim Dalı

INTRODUCTION - PURPOSE: This study aims to evaluate the persistent and new-onset symptoms in the Post-COVID period and the effects of the disease on respiratory functions, functionality and independence level, quality of life and sleep quality, and to investigate the risk factors of the patients we treated in our intensive care unit with a definite diagnosis of COVID-19 and discharged.

MATERIALS AND METHODS: Our study included 60 patients between the ages of 18-75 who were diagnosed with COVID-19 and were treated and discharged from the Anesthesiology and Reanimation COVID-19 Intensive Care Unit.Our study is a cross-sectional epidemiological study, and patients who met the inclusion criteria were contacted and surveyed, six months after their discharge. The Modified Borg Scale was used to evaluate the respiratory functions of the patients in the post-COVID period six months after discharge, the SF-36 quality of life scale to evaluate their quality of life,the Pittsburgh Sleep Quality Index to evaluate their sleep quality, and the Post-COVID-19 Functional Status Scale to evaluate their functionality and independence.

RESULTS: The most common symptom experienced by the discharged patients in the 6th month of Post- COVID was shortness of breath with a frequency of 71.7% (43). Post-COVID hair loss was present in 40% (8) of female patients and 7.5% (3) of male patients, and a statistically significant difference was found between the two groups according to gender ($p<0.05$). It was found that quality of life, functional status, respiratory function and sleep quality were statistically significantly worse in female patients, patients aged 65 and over, number of additional diseases ≥3, number of COVID symptoms ≥5, and patients who were intubated.

The distribution of the symptoms experienced by the examinees in the post-covid process

Tablo 1. İncelenenlerin post COVID dönemde yaşadıkları semptomların dağılımı, Çanakkale, 2022

Nefes darlığı	**Sayı**	**%**
Var	43	71,7
Yok	17	28,3
Halsizlik- Yorgunluk		
Var	33	55,0
Yok	27	45,0
Uyku bozukluğu		
Var	31	51,6
Yok	29	48,4
Öksürük		
Var	19	31,7
Yok	41	68,3
Unutkanlık		
Var	18	30,0
Yok	42	70,0
Eklem ağrısı		
Var	17	28,3
Yok	43	71,7
Saç dökülmesi		
Var	11	18,3
Yok	49	81,7
Nöropatik şikayetler		
Var	9	15
Yok	51	85
Toplam	**60**	**100**

Comparison of the complaints that persisted after discharge by gender in the subjects examined

Tablo 2. İncelenenlerde cinsiyete göre taburculuk sonrası devam eden şikayetlerin karşılaştırması, Çanakkale, 2022

	Cinsiyet		
	Kadın	Erkek	P
	n (%)	n (%)	
Nefes Darlığı			
Var	15 (%75)	28 (%70)	0,685
Yok	5 (%25)	12 (%30)	
Halsizlik-yorgunluk			
Var	15 (%75)	18 (%45)	***0,028***
Yok	5 (%25)	22 (%55)	
Uyku bozukluğu			
Var	11 (%55)	20 (%50)	0,360
Yok	9 (%45)	20 (%50)	
Öksürük			
Var	10 (%50)	9 (%22,5)	***0,031***
Yok	10 (%50)	31 (%77,5)	
Eklem ağrısı			
Var	8 (%40)	9 (%22,5)	0,156
Yok	12 (%60)	31 (%77,5)	
Unutkanlık			
Var	5 (%25)	13 (%32,5)	0,550
Yok	15 (%75)	27 (%67,5)	
Saç dökülmesi			
Var	8 (%40)	3 (%7,5)	***0,004***
Yok	12 (%60)	37 (%92,5)	
TOPLAM	**20**	**40**	

p: Ki-Kare testi

DISCUSSION - CONCLUSION: In this study, we found that patients who had the most severe clinical illness with COVID-19 experienced many persistent symptoms in the post-COVID period, and their quality of life, functionality, sleep quality and respiratory functions were seriously affected.

Keywords: COVID-19, SF-36, functional status, respiratory function

SAĞLIK BİLİMLERİ ÜNİVERSİTESİ

11. ULUSLARARASI katılımlı Anesteziyoloji ve Reanimasyon Sempozyumu

SAĞLIK BİLİMLERİ ÜNİVERSİTESİ
GÜLHANE EĞİTİM VE ARAŞTIRMA HASTANESİ
KONGRE MERKEZİ

ANKARA
2-3 ARALIK 2022

SÖZLÜ BİLDİRİLER

Pub No: S-001

The Incidence of Acute Renal Failure and Its Relationship with the Severity of COVID-19 Disease in COVID-19 Patients in Intensive Care

Yusuf Yılmaz[1], Betül Güven Aytaç[2], Kübra Kaya Güney[3]

[1]Develi Dr. Ekrem Karakaya Devlet Hastanesi, Anesteziyoloji ve Reanimasyon Kliniği
[2]Ankara Şehir Hastanesi, Anesteziyoloji ve Reanimasyon Kliniği
[3]Çankırı Devlet Hastanesi, Anesteziyoloji ve Reanimasyon Kliniği

INTRODUCTION - PURPOSE: COVID-19 is a disease that causes severe respiratory failure(1). There is evidence that acute renal failure(AKI) is common in COVID-19 patients(2,3). In this study, we aimed to investigate the incidence of AKI, the causes of acute kidney failure, and its correlation with the respiratory severity of COVID-19 in COVID-19 patients followed in the intensive care unit.

MATERIALS AND METHODS: After obtaining the ethics committee approval, 220 patients were screened who were followed up in the COVID-19 intensive care units, 168 patients were included in the study. Brescia-COVID-Respiratory-Severity-Scale(BCRSS) scores were calculated according to the daily follow-ups of the patients. Demographic data of the patients, Neutrophil/Lymphocyte(N/L) ratio, CRP values, and discharge results were recorded. AKI status was recorded according to KDIGO-AKI criteria.

RESULTS: The incidence of AKI in patients was determined as %58.9. In patients with AKI, BCRSS scores on admission to intensive care, discharge/ex day, mean duration of hospitalization and the highest BCRSS scores they reached were found to be higher($p<0.05$). Age, basal creatinine values, APACHE scores, CRP values and N/L rates at admission to intensive care and discharge/ex day, vasopressor support and nephrotoxic drug use, sepsis, multiorgan dysfunction syndrome percentages, mortality rates were found to be higher in patients who developed AKI($p< 0.05$). Various models were created to calculate the risk of developing AKI and the risk of mortality in patients.

Comparisons by AKI Development Status

		Non-AKI Group (n=69)	AKI Group (n=99)	P
Sex	Female	29 (%42,0)	48 (%48,5)	0,409 [a]
	Male	40 (%58,0)	51 (%51,5)	
Age (year)		68,0 ± 14,0	75,0 ± 12,7	**0,001** [b]
Basal Creatinine Value		0,78 ± 0,17	0,90 ± 0,19	**0,000**
APACHE Score		13,1 ± 8,5	24,5 ± 11,1	**0,000**
CRP Value	Admission	0,09 ± 0,07	0,13 ± 0,08	**0,002**
	First AKI Day	--	0,13 ± 0,08	--
	Discharge/EX Day	0,04 ± 0,05	0,11 ± 0,08	**0,000**
N/L Ratio	Admission	13,3 ± 12,1	19,6 ± 17,2	**0,010**
	First AKI Day	--	23,1 ± 21,0	--
	Discharge/EX Day	12,7 ± 16,3	26,8 ± 26,4	**0,000**
Vasopressor Support	No	59 (%85,5)	26 (%26,3)	**0,000**
	Yes	10 (%14,5)	73 (%73,7)	
Nephrotoxic Medication	No	69 (%100,0)	84 (%84,8)	**0,002**
	Yes	0 (%0,0)	15 (%15,2)	
Colistin	No	69 (%100,0)	85 (%85,9)	**0,003**
	Yes	0 (%0,0)	14 (%14,1)	
Gentamicin	No	69 (%100,0)	98 (%99,0)	1,000
	Yes	0 (%0,0)	1 (%1,0)	
Acyclovir	No	69 (%100,0)	98 (%99,0)	1,000
	Yes	0 (%0,0)	1 (%1,0)	

Comparisons by discharge status

Discharge status		Alive (n=84)	Died (n=84)	P
Sex	Female	39 (%46,4)	38 (%45,2)	0,877 [a]
	Male	45 (%53,6)	46 (%54,8)	
Age (year)		68,6 ± 13,8	75,7 ± 12,6	**0,001** [b]
Basal Creatinine Value		0,80 ± 0,17	0,90 ± 0,20	**0,001**
APACHE Score		11,3 ± 6,6	28,3 ± 9,0	**0,000**
AKI Duration		3,04 ± 3,03	5,27 ± 4,17	**0,018**
CRP Value	Admission	0,10 ± 0,08	0,13 ± 0,07	**0,021**
	First AKI Day	0,13 ± 0,09	0,13 ± 0,08	0,753
	Discharge/EX Day	0,04 ± 0,04	0,12 ± 0,08	**0,000**
N/L Ratio	Admission	13,5 ± 11,3	20,5 ± 18,3	**0,003**
	First AKI Day	11,7 ± 8,3	26,7 ± 22,5	**0,000**
	Discharge/EX Day	9,4 ± 10,1	32,6 ± 27,6	**0,000**
Vasopressor Support	No	76 (%90,5)	9 (%10,7)	**0,000**
	Yes	8 (%9,5)	75 (%89,3)	
Nephrotoxic Medication	No	83 (%98,8)	70 (%83,3)	**0,001**
	Yes	1 (%1,2)	14 (%16,7)	
Colistin	No	83 (%98,8)	71 (%84,5)	**0,002**
	Yes	1 (%1,2)	13 (%15,5)	
Gentamicin	No	84 (%100,0)	83 (%98,8)	1,000
	Yes	0 (%0,0)	1 (%1,2)	
Acyclovir	No	84 (%100,0)	83 (%98,8)	1,000
	Yes	0 (%0,0)	1 (%1,2)	

Comparison of BCRSS Score Between and Within Groups

		Non-AKI Group (n=69)	AKI Group (n=99)	P
BCRSS Score	Admission	2,7 ± 0,4	3,2 ± 0,7	**0,000**
	First AKI Day	--	4,1 ± 1,4	--
	Discharge/EX Day	2,4 ± 0,9	4,2 ± 1,3	**0,000**
	Mean	2,7 ± 0,4	3,9 ± 0,9	**0,000**
	Highest	3,0 ± 0,7	4,5 ± 0,9	**0,000**
Highest BCRSS Score	2	12 (%92,3)	1 (%7,7)	
	3	48 (%71,6)	19 (%28,4)	
	4	4 (%18,2)	18 (%81,8)	**0,000**
	5	5 (%8,5)	54 (%91,5)	
	6	0 (%0,0)	7 (%100,0)	

DISCUSSION - CONCLUSION: When the respiratory severity of the COVID-19 increases, an increase is observed in the rate of development of acute kidney injury in patients and, accordingly, in the mortality rates of the disease. With the prediction models we have created, patients with a high risk of developing AKI can be identified and renal protective treatments can be performed. AKI is an important complication that increases the mortality of COVID-19 and should have an important place in treatment goals to reduce mortality in these patients.

Keywords: Acute Kidney Injury, Brescia-COVID Respiratory Severity Scale, COVID-19 Disease, Mortality, SARS-COV-2

Pub No: S-002

Postoperative Residual Curarization of Geriatric Patients in the Recovery Unit: A Prospective, Observational Study

Emine SÖNMEZ[1], Betül Güven AYTAÇ[1], Nadide Aysun POSTACI[1]

[1]Ankara City Hospital, SBÜ, Anesthesiology and Reanimation Clinic

INTRODUCTION - PURPOSE: Postoperative residual curarization (PORC) causes complications and adverse outcomes in patients after general anesthesia. The aim of our study is to investigate the incidence of PORC and the factors affecting it of the patients over 65 years of age in the Postoperative Recovery Unit (PORU).

MATERIALS AND METHODS: This prospective, observational study included 185 patients who agreed to participate in the study after the approval of the Ethics Committee dated 07.07.2021 and numbered E1-21-1912. Patients who underwent elective surgery under general anesthesia using neuromuscular blocking agent (NMBA) were evaluated for PORC (Train of Four Ratio<90) by monitoring the depth of block with TOF WatchSX in PORU. Demographic characteristics, intraoperative and postoperative data of the patients, and complications were recorded.

RESULTS: The incidence of PORC was 3,4%. The incidence of PORC increased in patients with higher ASA status, CCI(Charlson Comorbidity Index) and ARISCAT scores, with a greater amount of intraoperative bleeding and greater total NMBA dose, and a shorter time from administration of the last dose of NMBA to the time it was antagonized. It was observed that the incidence of respiratory complications in PORU was 50% higher in patients with PORC. The time to discharge from PORU was 1,57 times higher in patients who developed PORC.

Comparison of demographic characteristics in terms of TOF value

		TOF %		P
		<90 (n=6)	≥90 (n=168)	
Gender	Female	3 (50,0%)	85 (50,6%)	1,000 [a]
	Male	3 (50,0%)	83 (49,4%)	
Age(years)		73,5 ± 4,9	70,2 ± 4,7	0,095 [b]
Weight(kg)		82,8 ± 20,1	75,5 ± 13,5	0,196 [b]
BMI (kg/m^2)		30,6 ± 6,6	27,3 ± 4,5	0,090 [b]
ASA	II III	1 (16,7%) 5 (83,3%)	96 (57,1%) 72 (42,9%)	**0,044** [a]
CCI		5,3 ± 1,0	4,1 ± 1,4	**0,028 b**

a: Chi-Square Test (n (%)), b: Independent Samples t Test (Mean ± SD)
ASA: American Society of Anesthesiologists fiziksel durum skoru,
CCI: Charlson Komorbidite İndeksi

Comparison of Antagonist Drugs in Terms of TOF Values

		TOF %		P
		<90 (n=6)	≥90 (n=168)	
Drug	Sugammadex	5 (83,3%)	166 (98,8%)	0,100 [a]
	Neostigmin	1 (16,7%)	2 (1,2%)	
Sugammadex (mg)	(n_1=5 / n_2=166)	180,0 ± 44,7	203,6 ± 28,9	**0,011** [b]
Neostigmin (mg)	(n_1=1 / n_2=2)	2,0 (2,0 – 2,0)	2,0 (2,0 – 2,0)	1,000 [c]

a: Chi-Square Test (n (%)), b: Independent Samples t Test (Mean±SD), c: Mann-Whitney U Test (Median/IQR)

FLOW DIAGRAM

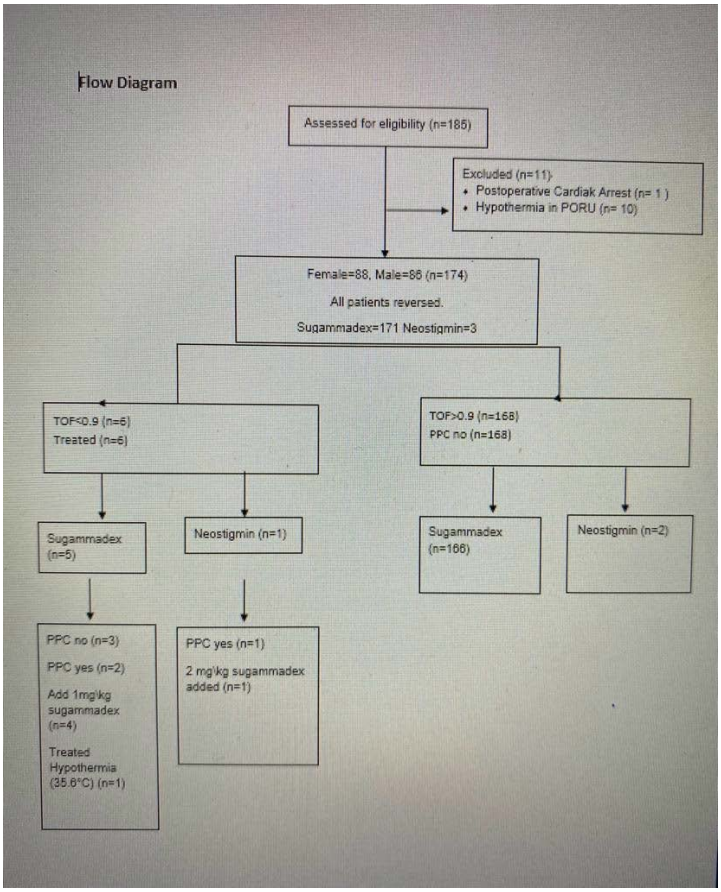

Comparison of TOF Value Between Variables with Clinically Significant Differences

	TOF % **<90** **(n=6)**	**TOF%** **≥90** **(n=168)**	**P**
Amount of bleeding (ml)	450,0 (95,0 – 1.025,0)	100,0 (0,0 – 300,0)	**0,041** [a]
i.v. fluid (ml)	2.916,7 ± 1.985,4	1.869,6 ± 1.240,7	**0,049** [b]
Total rocuronium dose (mg)	130,0 (97,5 – 145,0)	60,0 (50,0 – 90,0)	**0,002**
Last NMBA-Antagonist time (min)	60,0 (35,0 – 95,0)	90,0 (75,0 – 123,8)	**0,024**
A-Ext-T (min)	4,5 (4,0 – 5,0)	2,0 (1,0 – 3,0)	**0,000**
PORU discharge time (min)	55,0 (48,8 – 60,0)	45,0 (45,0 – 45,0)	**0,001** [a]

PORU Complication no yes	3 (50,0%) 3 (50,0%)	168 (100,0%) ------	**0,000** [b]
5-second head lift recovered failed	2 (33,3%) 4 (66,7%)	168 (100,0%) -------	**0,000**
ARISCAT Risk Score	43,7 ± 6,1	32,5 ± 15,2	**0,004**
Respiratory complication no yes	3 (50,0%) 3 (50,0%)	167 (99,4%) 1 (0,6)	**0,000**

a: Mann-Whitney U Test (Median / IQR), b: Independent Samples t Test (Mean ± SD), n: number, %: percentage, p: PORC Incidence, Last NMBA-Antagonist Time (Min): The time from the last dose of neuromuscular blocker to the administration of the antagonist drug, A-Ext-T: The time in minutes until the patient is extubated after the administration of the antagonist drug..

DISCUSSION - CONCLUSION: In our clinic, sugammadex was administered in 98,3% of the geriatric patients for the antagonism of MNBA and the incidence of PORC was found to be 3,4%. The risk of PORC was found to be higher in geriatric patients with high ASA physical risk score, CCI values, and ARISCAT risk score. PORC increased the time to discharge from PORU. As a result, the elderly are at high risk for PORC-related adverse outcomes. Quantitative monitoring of neuromuscular function and logical use of NMBA antagonist agents will improve patient safety by reducing the risk of PORC and postoperative pulmonary complications.

Keywords: Postoperative residual curarization (PORC), Train-of-four (TOF), Neuromuscular monitoring (NMM), Neuromuscular blocking agents (NMBA)

Pub No: S-003

Effect of Laryngoscopy Technique on Intubation Procedure: Manikin Study

Emine ASLANLAR[1], İnci KARA[1], Sinan DEĞİRMENCİOĞLU[1], Durmuş Ali ASLANLAR[2]

[1]Selcuk University Faculty of Medicine, Department of Anesthesiology and Reanimation , Konya
[2]Meram State Hospital, Konya

INTRODUCTION - PURPOSE: Laryngoscopy is a frequently used procedure during tracheal intubation. Right-hand scissor, left-hand scissor and head extension techniques are used to ensure adequate mouth opening during laryngoscopy .We aimed to evaluate the effect of those three different techniques over intubation time and success.

MATERIALS AND METHODS: Research assistants in our clinic were included in the study. Intubation was performed with a Macintosh laryngoscope and number 3 blade on an airway dummy. Participants performed intubation 3 times, using all three techniques in order. The time that took from holding the laryngoscope until visualization of the vocal cords, intubation time and success, dominant hand and clinical experience of the participant were recorded. Participants were divided into three groups according to the techniques and the data were compared.

Sağ makaslama tekniği



Sol makaslama tekniği



RESULTS: Demographic data of research assistants were given in Table 1. There was no difference in terms of intubation time and success in all three techniques(p>0.05)(Table 2). While the numerical rating scale score was lower in the head extension technique (p=0.04), there was no difference between the other two techniques(Table 3).

Table 1. Demographic Data

		Mean±Sd	**n-%**
Age		29.67±3.94	
Experience		26.8±19.73	
Gender	Female Male		20-62.5 12-37.5
Dominant Hand	Right Left		30-93.75 2-6.25

Table 2. Comparison of Mouth Opening Techniques

	Right Hand Shear	Left Hand Shear	Head Extension	p*
Vocal cord visuatization time (sec)	12.66±5.79	14.25 ±14.01	13.97 ±7.63	0.85
Intubation time (sec)	15.5 ±5.74	18.59 ±14.08	17.91 ± 7.81	0.21
Number of attempts	1.09 ±0.3	1.16 ±0.37	1.19 ±0.47	0.71
Technical ease	7.72 ±1.57	7.84 ±2.06	6.44 ±1.98	0.005**

Mean±Sd

*Friedman test applied

**Difference was significant at $p \leq 0.05$ level (2-tailed)

Table 3. Comparison of Mouth Opening Techniques in terms of Technical Ease

Technical ease	Z	p*
Right hand scissoring-Left hand scissoring	-0.125	0.3

Right hand scissoring-Head extension	-2,676	0.002**
Left hand scissoring - Head extension	-3,057	<0.001**

* Wilcoxon signed rank test for paired data

**Difference was significant at $p \leq 0.005$ level (2-tailed) after Bonferroni adjustment applied

DISCUSSION - CONCLUSION: All three techniques are used to ensure adequate mouth opening during laryngoscopy, but right-hand scissoring technique is generally recommended. In left-hand scissoring, the laryngoscope is first held with the right hand, and after mouth opening is achieved, the laryngoscope will be switched to the left hand. We conducted our study with the hypothesis that this situation may lead to loss of time. Although the duration of visualization of the vocal cords and intubation time were longer in the left-hand scissoring technique, there was no statistical difference. That's why new studies involving larger numbers of participants may be required. CONCLUSION All three techniques are used to ensure adequate mouth opening during intubation. The Intubation time and success are similar in all three techniques.

Keywords: Laryngoscopy, Right-hand scissor, intubation time

Pub No: S-004

The Effect of Patient Positioning on Advanced Cardiac Parameters in Laparoscopic and Open Major Abdominal Cancer Surgery

Mustafa Kemal SAHIN[1], Guldeniz Argun[1]

[1]UHS Dr. Abdurrahman Yurtaslan Oncology Training and Research Hospital, Ankara

INTRODUCTION - PURPOSE: Esophageal Doppler Monitoring (Deltex CardioQ Esophageal Doppler Monitor, ODM) is a fluid management strategy that measures cardiac output non-invasively by an esophageal probe (1). The aim of this study is to evaluate the effect of patient positioning on cardiac indexes and vital signs in patients who have undergone laparoscopic or open major abdominal cancer surgery.

MATERIALS AND METHODS: ODM-used patients who underwent major abdominal cancer surgery from November 2021 to November 2022 were screened from the anesthesiology clinic records. The demographic data and surgery type (open or laparoscopic) were documented. The vital signs, the amount of blood loss, the type and volume of the fluid administered, and the results of cardiac index measurements measured with an ODM device in the supine and Trendelenburg positions were recorded. The cardiac parameters recorded with the ODM device were cardiac output (CO), flow time corrected (FTc), peak velocity (PV), and stroke distance (SD). All data were analyzed by appropriate statistical methods.

RESULTS: Forty patients who underwent major abdominal cancer surgery and were monitored with ODM were divided into two groups in terms of surgical technique (open or laparoscopic) and screened retrospectively. The groups were similar in terms of patient characteristics, the amount of blood loss, and fluid therapy. No significant difference was found in cardiac indices between the supine and trendelenburg positions ($p>0.05$). However, the Trendelenburg position caused an increase in the mean arterial pressures in both groups regardless of the type of surgery ($p<0.05$).

DISCUSSION - CONCLUSION: We found that patient positioning (supine or Trendelenburg) did not change cardiac indices in major abdominal cancer surgery (2,3). However, Trendelenburg position increases the mean arterial pressure as expected. As a result, cardiac indices are not affected by position in major abdominal cancer surgery if blood loss were minimal and fluid therapy were adequate.

Keywords: Major abdominal surgery, Trendelenburg position, Cardiac indices, Continuous esophageal doppler

Pub No: S-005

A Rare Complication: Gas Embolism Developed During Operation Of Laparoscopic Bilateral Inguinal Herniorrhaphy

Gülten Sağır[1], İlayda Pektaş[1], Ahmet Furkan Gürel[1], Hülya Başar[1]

[1]Ankara Eğitim ve Araştırma Hastanesi

INTRODUCTION - PURPOSE: Many operations have been performed laparoscopically for the last 30 years.During laparoscopic surgery,a large amount of gas,usually CO2,is given intraperitoneally.Gas embolism is a rare but most feared and deadly complication of laparoscopic surgery.In this case report, gas embolism developing during LBIH operation,and its treatment are discussed.

CASE: Laparoscopic surgery was planned for a 58-year-old male patient with a diagnosis of bilateral inguinal hernia.After routine monitoring,the patient was intubated using propofol(2mg/kg),fentanyl(2µgr/kg) and rocuronium(0.6mg/kg).Sevoflurane-O2-air was used for maintenance.EtCO2 was monitored as 30-35 mmHg.Intraabdominal pressure was adjusted as 12cmH2O by the surgical team.At the 47th minute of the operation,EtCO2 decreased to 12mmHg,BP to 60/27mmHg,HR from 85/min to 44/min and SpO2:100% to 82%.The surgical team was warned,and the operation was stopped,abdominal insufflation was stopped and 100%O2 was started,30mg of ephedrine was administered by titration.Durant maneuver was applied,and when the patients HR fell to 30/min,1mg of atropine was administered.Considering that gas embolism had developed,right internal jugular vein and left radial artery catheterization were quickly placed,and 5-6ml of air was aspirated from the CVC.BP and HR began to rise.PCO2 was 54 in the arterial blood gas.The surgical team completed the operation unilaterally.The patient,who was hemodynamically stabilized,was extubated without any problem.The patient was sent to the service after being monitored in the intensive care unit for 24hours.

DISCUSSION - CONCLUSION: In the normal course of laparoscopic surgeries,subcutaneous emphysema is frequently seen due to the CO2 given by insufflation,and serious hemodynamic-respiratory complications may occur if the gas entering the circulation is large.(1)The patient's clinical course in our case deteriorated rapidlyand was reversed with rapid intervention.However, when the development of gas embolism is massive,the patient may develop shock-cardiac arrest.At this point, it should be kept in mind that gas embolism is a rare but fatal complication in laparoscopic operations and the necessity of strict EtCO2 and hemodynamic monitoring should be kept in mind.

Keywords: Laparoscopic Hernia, Gas Embolism, General Anesthesia

Pub No: S-006

Our Experiences In Non-Operating Room Anesthesia In Pediatric Magnetic Resonance Imaging Cases

Yunus Emre TUNÇDEMİR[1], Ahmet Furkan GÜREL[2], Meltem BEKTAŞ[2], Ayşe Ceren DOĞANÖZÜ[2], Murat KAYKAÇ[2], Hülya BAŞAR[2]

[1]Department of Algology, Başakşehir Cam and Sakura City Hospital, İstanbul, Turkey
[2]Department of Anesthesiology and Reanimation, The Ministry of Health, Ankara Training and Research Hospital, Ankara/Turkey

INTRODUCTION - PURPOSE: MRI (Magnetic resonance imaging) unit is one of the most difficult units in terms of anesthesia application conditions. Provision of necessary equipment such as peripheral pulse oximeter, electrocardiography device, end-tidal Co2 monitor, aspirator, defibrillator and anesthesia machine(1) is required for safe MRI scanning under anesthesia in pediatric patients; Collaborating with pediatric patients is difficult. In addition, the need for anesthesia increases in medical conditions such as underlying neuromotor or neurocognitive diseases, vascular malformations, oncological tumors(2).We aimed to achieve maximum patient safety and superior image quality by retrospectively scanning the frequency of complications during anesthesia in MRI cases and our non-operating room anesthesia applications.

MATERIALS AND METHODS: After the approval of the ethics committee, the data of 455 patients that were ranked ASA 1-3 and aged 0-18 years old, who underwent MRI under anesthesia between the years 2020-2022, were retrospectively analyzed.Demographic data of the patients, ASA scores, Mallampati score, comorbidities, mean arterial pressure during the procedure, HR, spo2, etco2, duration of anesthesia, recovery time, anesthetic drugs used, and complication development status were examined.

RESULTS: When the general anesthesia group was compared with the Sedo-analgesia group; The mean age of the patients ($p < 0.05$) was lower, the ASA score ($p < 0.05$) was higher, the recovery period was longer ($p < 0.05$) and the rate of desaturation development ($p < 0.05$) was lower. In both groups; Bradycardia, tachycardia, allergic reaction, vomiting, cardiac arrest, laryngospasm development rate, anesthesia and recovery times were found to be similar ($p > 0.05$). The most common complication in our study was desaturation.

Table 1

		Anesthesia Preference				p	
		Sedation		General Anesthesia			
		Average	Median	Average	Median		
Age		9.1 ± 2.3	9.0	4.8 ± 2.9	5.0	***0.000***	m
Sex	Female	59 52.7%		146 42.6%		0.062	X²
	Male	53 47.3%		197 57.4%			
ASA Score	I	30 26.8%		51 14.9%		***0.000***	X²
	II	57 50.9%		148 43.1%			
	III	25 22.3%		144 42.0%			
Anesthesia Duration		17.9 ± 7.9	15.0	18.7 ± 9.8	15.0	0.760	m
Recovery Time							
< 5 Minutes		52 46.4%		112 32.7%		***0.004***	X²
5-15 Minutes		57 50.9%		191 55.7%			
15-30 Minutes		1 0.9%		32 9.3%			
> 30 Minutes		2 1.8%		8 2.3%			
Desaturation		14 12.5%		3 0.9%		***0.000***	X²
Bradycardia		4 3.6%		11 3.2%		0.851	X²
Tachycardia		3 2.7%		5 1.5%		0.413	X²
Allergic Reaction		2 1.8%		0 0.0%		0.060	X²
Vomiting		4 3.6%		9 2.6%		0.610	X²
Cardiac Arrest		0 0.0%		0 0.0%		1.000	X²
Laryngospasm		2 1.8%		5 1.5%		0.683	X²

[m] Mann-Whitney U Test / [X²] Chi-squared test (Fisher test)

Table 2

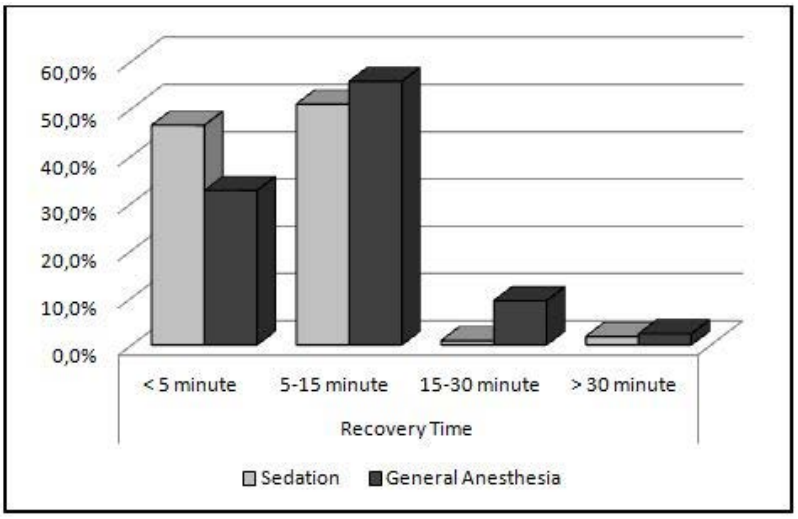

Table 3

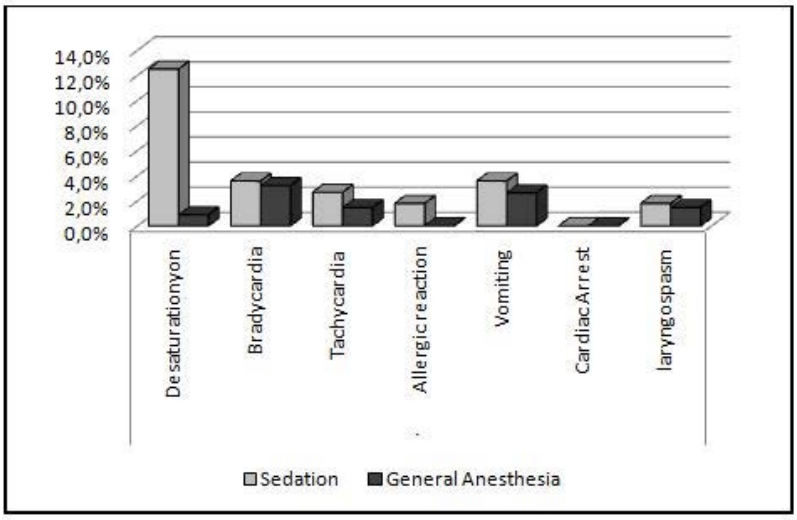

DISCUSSION - CONCLUSION: Unsuitable environment for anesthesia, limited intervention area and lack of equipment pave the way for various complications. As in our study, respiratory complications are most commonly encountered during anesthesia(3). We believe that general anesthesia can be safer if the necessary equipment is available.

Keywords: Pediatric anesthesia, Magnetic resonance imaging, Non-operating room anesthesia

Pub No: S-007

Sevoflurane-Associated Diffuse Alveolar Hemorrhage, Case Report

Fatma Ozkan Sipahioglu[1], Funda Atar[1]

[1]University of Medical Sciences Turkey, Diskapi Yildirim Beyazit Training and Research Hospital, Department of Anesthesiology and Reanimation, Ankara, Turkey

INTRODUCTION - PURPOSE: Diffuse alveolar hemorrhage (DAH) is bleeding into the alveolus due to alveolar-capillary damage. Acute respiratory distress, hemoptysis, anemia, and diffuse alveolar opacity on radiological imaging are typical for DAH. Airway obstruction, pulmonary injury associated with inhalation of anesthetic agents, and thermal damage due to exothermic reaction are reported causes of perioperative DAH(1-4). In our case report, we aimed to discuss the reasons for postoperative DAH, which we associate with sevoflurane, and to contribute to the literature.

CASE: A 20-year-old male patient was operated on for acute appendicitis. His preoperative history, physical examination, and laboratory values were unremarkable. A routine general anesthesia protocol was applied. Anesthesia was maintained with 2-2.5% sevoflurane in an oxygen-air (50-50%) mixture. The patient, whose surgery was completed successfully, was reverted with sugammadex and extubated. However, one hour later, the patient developed hemoptysis and tachypnea, and his saturation decreased. Postoperative radiological imaging revealed bilateral alveolar infiltrates (Figure-1). Postoperative hemoglobin decreased by 3.2 g/dl. The patient diagnosed with DAH was taken to the intensive care unit and followed up and treated. The patient chest X-ray returned to normal on the second postoperative day, and he was discharged on the fifth postoperative day.

Figure-1



Development of bilateral patchy infiltrates and ground glass opacities between preoperative chest X-ray(a) and postoperative chest X-ray(b) and computed tomography sagittal section(c)

DISCUSSION - CONCLUSION: The most common causes of perioperative DAH are bronchospasm and negative pressure pulmonary edema. In the literature, DAH after the use of sevoflurane has been reported in 9 case reports. It is noteworthy that most of the cases consisted of young male patients. As in our case, no other cause or predisposing factor could be found in 5 of them, and DAH was directly associated with sevoflurane(3,5-8). The rapid recovery of the patients also supports this view. In conclusion, sevoflurane was the most likely cause of DAH in this case report. This rare complication should be considered in the differential diagnosis of postoperative hemoptysis of unknown etiology.

Keywords: sevoflurane, diffuse alveolar hemorrhage, hemoptysis

Pub No: S-008

The Effects of Intraoperative Different Fluid Therapy Protocols on Postoperative Renal Functions

Ayca Tuba DUMANLI OZCAN[1], Nisan TAS[1], Umut Cahit ERSOY[1], Kevser YAMEN[1], Yusuf YILMAZ[1], Erdal OZCAN[1], Handan GULEC[1]

[1]Ankara City Hospital

INTRODUCTION - PURPOSE: Planning of intraoperative fluid therapy is important in major abdominal surgeries. Targeted fluid therapy planned with individual hemodynamic assessment has been associated with better outcomes, including survival. Renal functions are sensitive to volume changes and hypovolemia may increase risk of postoperative kidney damage (1). In our study, we aimed to evaluate relationship between different intraoperative fluid therapy protocols and postoperative renal damage and mortality.

MATERIALS AND METHODS: Sixty patients who 18-65 age and underwent pancreatic surgery in our hospital were included in the study. They were divided into two groups as liberal fluid therapy (Group 1, n=30) and targeted fluid therapy (Group 2, n=30). Systolic and diastolic blood pressures of all patients were recorded before and after intubation, before and after extubation. The creatinine, BUN, and potassium values of all patients were recorded at postoperative 0, 1, 24, 48 and 72 hours. Patients were staged according to KDIGO Criteria. The amount of bleeding during operation was recorded for both groups.

RESULTS: There was no difference in terms of demographic data measured blood pressures (p>0.05); however, a significant difference was observed in the amount of intraoperative bleeding. Bleeding was statistically significantly higher in liberal fluid therapy group (Group 1). No significant difference was observed in postoperative renal function tests. KDIGO subgroups. BUN and creatinine values between groups (p>0.05).

Table 1: The amount of bleeding and the distribution of the amount of fluid administered according to the groups

	Group		
	Group 1 Median(min-max)	Group 2 Median(min-max)	p
Amount of bleeding (cc)	500-(0-2500)	325(0-2300)	0,038
Amount of Crystalloid (cc)	3500(1000-8000)	2800(1500-4500)	**0,003**
Amount of Colloid (cc)	500(0-1500)	500(0-1200)	0,637

Total Fluid (cc)	4600(1000-10100)	3525(1500-5700) **0,008**

Mann-Whitney U test results were considered significant at $p<0.05$

Table 2: Staging of patients according to KDIGO criteria

		Group				
		Group 1		Group 2		
		Count	Column N %	Count	Column N %	p
KDİGO Staging	0	17	70,80%	21	80,80%	0,26
	1	2	8,30%	0	0,00%	
	2	4	16,70%	2	7,70%	
	3	1	4,20%	3	11,50%	

Fisher's exact test was considered significant at $p< 0.05$

DISCUSSION - CONCLUSION: In a study by Gottin et al., the use of targeted and restrictive fluid protocols was associated with a lower incidence of complications compared to the liberal fluid protocol (2). No difference was observed in the occurrence of postoperative kidney disease with targeted fluid therapy in a study by Forget et al. (3). In conclusion, we think that targeted fluid therapy does not have a negative effect on renal functions. We believe that optimizing tissue perfusion in high-risk surgical patients should be based on an individualized approach.

Keywords: fluid, kidney, surgery, liberal, targeted

Pub No: S-009

Turkish Delight Was Killing; An Interesting Case Report of Negative Pressure Pulmonary Edema

Onur KÜÇÜK[1], Hasan ERTAŞ[1], Nur Sena ÇAKAR[1], Necla DERELİ[1]

[1]Ankara Atatürk Sanatoryum Education and Research Hospital, Ankara, Turkey

INTRODUCTION - PURPOSE: Negative pressure pulmonary edema(NPPE) or post-obstructive pulmonary edema(POPE) are classified into two groups(1,2). Type-I occurs immediately after the onset of acute airway obstruction and Type-II occurs after resolution of chronic upper airway obstruction(3). In this case report; we presented a case of NPPE due to upper airway obstruction during eating Turkish delight in a young male patient.

CASE: 40 years old male; he applied to the emergency department with dyspnea, GCD and loss of consciousness. In the emergency service; the patient was intubated(foreign body and pink foamy in tube aspiration) with GCS:4,5,1, satO2:50%. The patient was admitted to the intensive care unit(ICU). From the patient's anamnesis; it was learned that while eating Turkish delight at home, he couldn't breathe suddenly, couldn't speak, his consciousness deteriorated and he was taken to the emergency department. ICU evaluation of the patient; BP:166/95mm-Hg, HR:99/min, satO2:100%(fiO2:50%), intubated-sedated, bilateral ral+, paac:effusion+(Img-1), Thorax-CT:diffuse(centrally prominent) patchy ground-glass views and pleural effusion-atelectasis(Img-2), COVID-PCR:negative, creatinine:2.95mg/dl, CRP:16.94mg/L, procalcitonin:9.79microg/L, Troponin:291ng/L, ECO:EF:%50, hypertrophic cardiomyopathy. Blood gas; pH:7.29 pO2:78 pCO2:49.5 satO2:92.2% HCO3:21.2 lac:3.8 were detected. When the clinical history, physical examination and radiological findings were evaluated, the diagnosis of NPPE was made. The patient was sedated and followed up in SIMV(PEEP:8mm-Hg) mode. Furosemide infusion was administered. Antibiotherapy; Tazocin, Klacid was started. On the first day of the treatment, there was a decrease in PAAC(Img-3) effusion. The patient was extubated on the 4th day of ICU admission. He was discharged on the 20th day of his hospitalization.

Img-1: PAAC in ICU admission

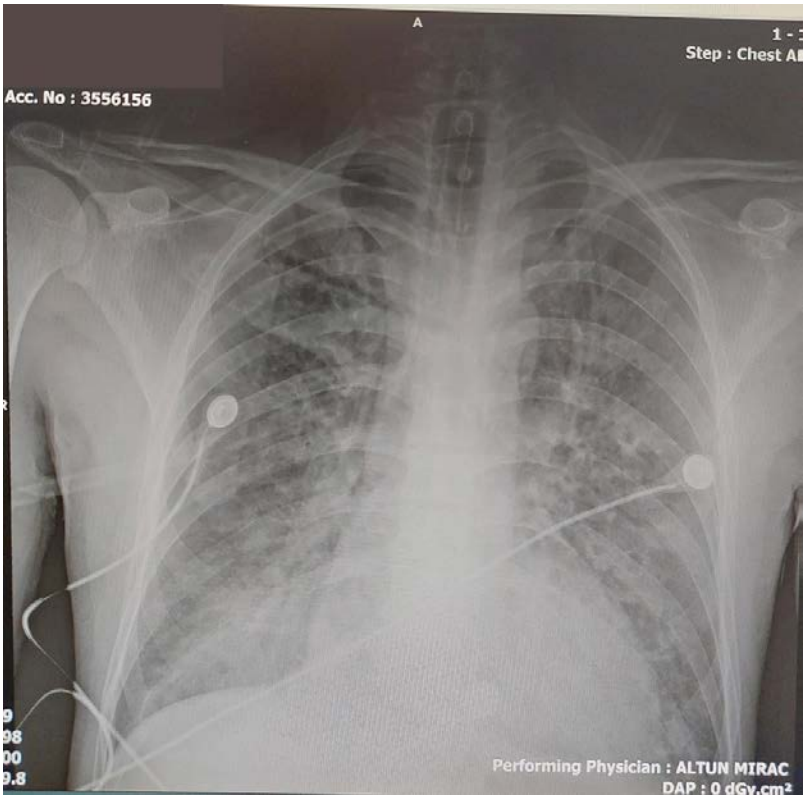

Diffuse infiltration and bilateral pleural effusion were observed in the PAAC examination performed at the admission of the patient to the ICU.

Img-2: Thorax-CT in ICU admission

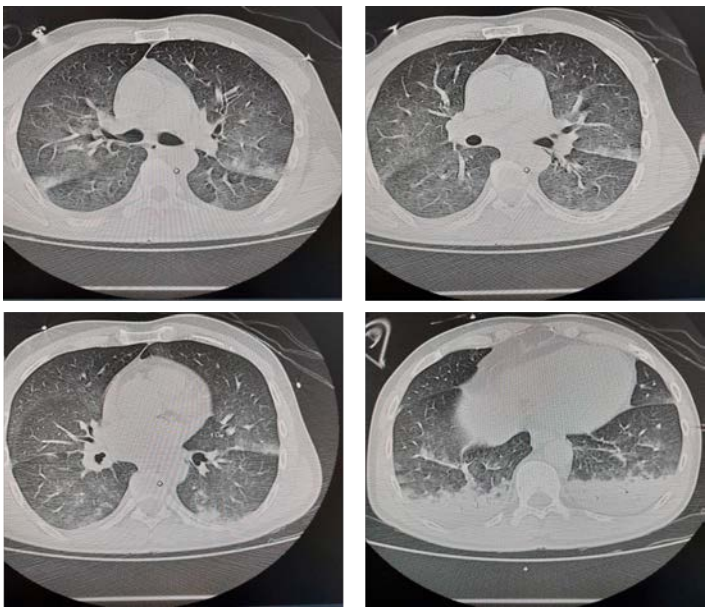

On thorax CT of the patient, diffuse patchy ground-glass views/infiltration image was observed in both lungs (central prominent). Bilateral pleural effusion was observed. Compression atelectasis secondary to effusion was observed in both lung lower lobe segments.

Img-3: PAAC on day 1 of treatment

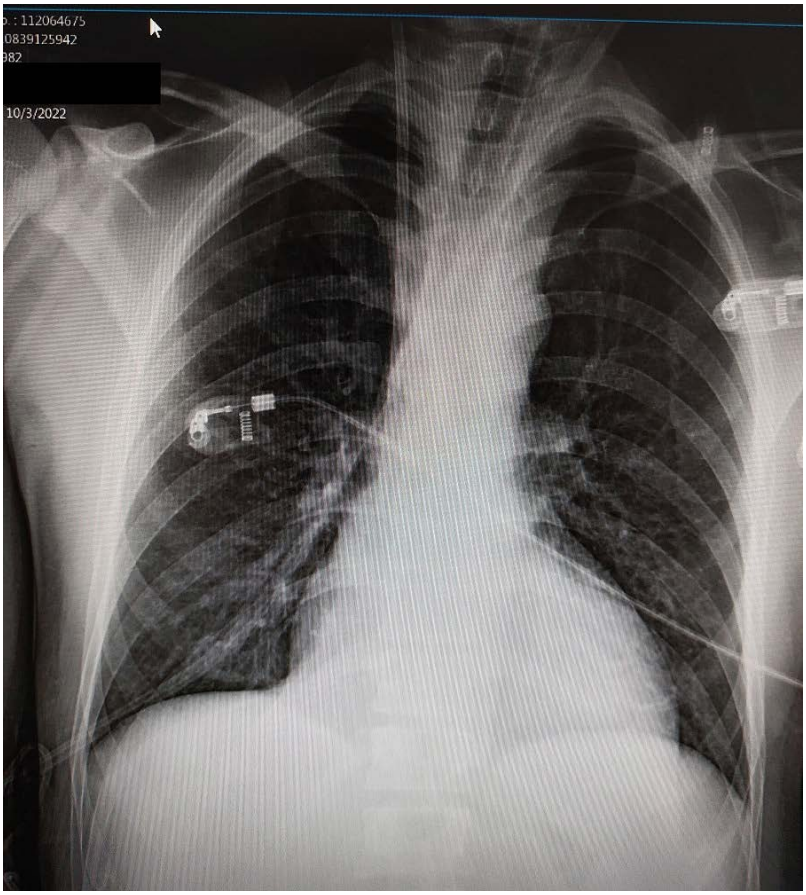

In the PAAC examination on the 1st day of the patient's treatment, it was observed that infiltration and pleural effusions decreased significantly.

DISCUSSION - CONCLUSION: NPPE has a characteristic appearance with central and independent ground-glass attenuation(edema/hemorrhage) on CT-scans(4). It has been reported in the literature that 50% of patients with NPPE have cardiac disease(5). NPPE is a life-threatening emergency with a high incidence in acute upper airway obstruction that requires active intervention. Timely monitoring, diagnosis and treatment are essential to prevent mortality and morbidity.

Keywords: Negative Pressure Pulmonary Edema, Post-obstructive Pulmonary Edema, Turkish Delight, Intensive Care Unit

Pub No: S-010

Our Nicardipine Experiences ,n Intracranial Hemorrhages Admitted to the Intensive Care Unit From the Emergency Department

Ayşe AYYILDIZ[1], Fatih Alper AYYILDIZ[1]

[1]ESKİŞEHİR CITY HOSPITAL

INTRODUCTION - PURPOSE: Nicardipine is a water-soluble calcium channel antagonist with predominantly vasodilatory effects (1). Intravenous nicardipine, which exhibits a relatively rapid onset of action, is more preferred when rapid control of blood pressure is required. In our study, we aimed to examine the patients who used nicardipine for hypertension regulation in patients hospitalized from the emergency department to the intensive care unit due to intracranial hemorrhage in the three-month period.

MATERIALS AND METHODS: Demographic data, comorbidities, hospitalization diagnoses, additional antihypertensive needs, and mortality rates of intracranial hemorrhage patients hospitalized in the intensive care unit in a 3-month period were recorded. Categorical variables were expressed in terms of numbers and percentage.

RESULTS: The number of patients with intracranial hemorrhage who used nicardipine was 21 and 42.8% of the patients were female (n=9). The mean age was 72.9±9.6 years. The comorbidities of the patients were hypertension 57.1% (n=12), chronic renal failure 23.8% (n=5), coronary artery disease 14.2% (n=3), diabetes mellitus 14.2% (n=3), bipolar disorder 9.5% (n). =2), ALS 4.7% (n=1), cerebrovascular event 4.7% (n=1). When we look at the indications for use, it was seen that subarachnoid hemorrhage 42.8% (n=9), intraparenchymal hemorrhage 28.5% (n=6), subdural hemorrhage 23.8% (n=5), cerebellar hemorrhage 4.7% (n=1), respectively. The need for additional antihypertensive medication developed in 42.8% of the patients. The mortality rate was found to be 38.0% (n=5).

DISCUSSION - CONCLUSION: Intracerebral hemorrhage treatment; It is a highly strategic process that requires a combination of hemostatic, antihypertensive, surgical and neuroprotective treatment managements. It is known that nicardipine reduces cerebral vascular resistance and protects patients from cerebral vasospasm in subarachnoid hemorrhages (2). Compton et al. showed in a study that nicardipine did not increase intracranial pressure compared to placebo in patients with severe head injury (3). We think that nicardipine is an antihypertensive drug that can be used safely for blood pressure regulation in intracranial hemorrhages.

Keywords: intracranial hemorrhage, subarachnoid hemorrhage, nicardipine, cerebral vasospasm, antihypertensive drug

Pub No: S-011

Questionnaire on the Impact of COVID-19 Pandemic, Socioeconomic Status and Working Conditions on Emigration of Research Assistants and Specialist Doctors of the Department of Anesthesiology and Reanimation

Ülkü Ceren KÖKSOY[1], Hakan YILMAZ[1], Baturay Kansu KAZBEK[1], Doğancan YAVUZ[1], Şeyma ORÇAN AKBUZ[1], Filiz TÜZÜNER[1]

[1]UFUK UNIVERSITY FACULTY OF MEDICINE

INTRODUCTION - PURPOSE: Since 2020, >6500 Turkish Anesthesiology&Reanimation Specialists struggle with difficulties brought by COVID-19 pandemic and deteriorating socioeconomic conditions. This survey study aims to evaluate the impact of COVID-19 pandemic and economic conditions on the migration of Anesthesiologists.

MATERIALS AND METHODS: The questionnaire, approved by the ethics committee, consists of 4 sections, 41 (3 open-ended, 38 multiple-choice) questions about demographic information, pandemic, foreign language and about living abroad.

RESULTS: 210 (male/female: 41.4%,/58.6%) research-assistants (37.1%) and experts (62.9%) aged 25-60 years participated. 74.1% are accredited-university graduate. 32.9% work in training-research hospital, 30% in state-university, 29.5% in public-hospital; 41.9% experts for >10 years; 75.7% receive salary of >15000 TL; 70.4% married,45.7% own a house and car; 33.3% cannot save. While 99% were vaccinated, 43.3% didn't have Covid-19. 66% have English, 6.7% other foreign language certificates (55.4%-German, 13.5%-Spanish, 6.8%-French). 26.3% haven't been, 15.5% lived, 4.8% worked abroad. 63.9% plan working abroad; 36% started preparing. 60.6% want to migrate due to socioeconomic conditions and 34.7% for working conditions. Pandemic isn't a reason for emigration. 71.3% had no preparation to emigrate, 7.7% received Turkish Medical Association certificate. 91.9% want Europe, 24.3%-Australia,23.7%-North America, (65.9%-Germany, 61.7%-England, 35.9%-Canada). Concerning domestic conditions, 84.7% are affected by income, 82.5% violence, 79.9% workplace security, 78.8% work environment. The participants want to work in safer conditions(92.3%) with lower weekly working-hours (76.5%) and high-salary (72.7%); greater economic purchasing power (91%). 57.5% of research-assistants and 46.8% of experts aim completing compulsory service and emigrate. 40% want to leave in 4 years,25.7% in 2-4 years, 25.2% in 1-2 years, 9% in a year. 41.9% don't consider returning even if conditions improve.

DISCUSSION - CONCLUSION: 1402 doctors left Türkiye in 2022 according to the Lancet, and anesthetists were among the majority. In our opinion, this loss of workforce can be prevented by improving income levels, working conditions, and increasing measures against violence.

Keywords: Anesthesiology and Reanimation Specialists, Survey, COVID-19 Pandemic, Doctor Migration, Socioeconomic Status

Pub No: S-012

Anesthesia Management of Embryonal Posterior Fossa Tumor Excision in an Infant: Case Report

Mine AKIN[1]

[1]Ankara Sehir Hastanesi

INTRODUCTION - PURPOSE: Anesthesia management in embryonal posterior fossa tumor surgery encountered's more challenging than other age groups. Often accompanied by hydrocephalus, macrocephaly. With this case report, we aimed to share the anesthetic approach applied due to position, hemodynamic instability, bleeding and special monitoring.

CASE: Hydrocephalus, posterior fossa tumor were detected in a 3-month-old, 7240 g male patient who was followed up with the diagnosis of prenatal hydrocephalus, mass excision was planned after ventriculoperitoneal shunt surgery performed under emergency conditions. The operating room temperature was adjusted to 23 °C, blanket was placed under him. After monitoring with electrocardiography, non-invasive blood pressure, SpO2, he was intubated with spiral cuffed tube after induction with propofol, fentanyl, rocuronium. A 4 French 5 cm central venous catheter was placed in the right internal jugular vein under ultrasound guidance. Invasive arterial blood pressure monitoring was achieved. BIS, bilateral cerebral NIRS sensors were placed. Electrodes for neuromonitoring were placed on the extremities, lip margin, tongue, shoulder, head. The patient's 4 extremities were wrapped with cotton to reduce heat loss. Urine catheter was inserted, esophageal temperature probe was placed, prone position was given. The patient was placed in a pediatric head stabilizer. Throughout the case, cerebral blood flow was followed by bilateral NIRS, depth of anesthesia by BIS, cranial nerves MEP monitoring, 4 extremities EMG and intermittent blood gas monitoring were performed for neuromonitoring. Intraoperative 120 cc ES transfusion was performed. The patient, whose surgery time was 225, anesthesia time 315 minutes, was extubated without any complication, was delivered to the pediatric intensive care unit,

DISCUSSION - CONCLUSION: With the developments in diagnosis, treatment methods, embryonal posterior fossa tumors in infancy have started to be encountered more frequently by anesthesiologists. It's necessary to be prepared starting from the pre-operative period for this group of patients who are sometimes taken to surgery urgently.

Keywords: Anesthesia, infant, posterior fossa tumor, neuromonitoring

Pub No: S-013

Anesthesia Management in a Patient with a Difficult Airway Due to a Giant Thyroid Mass

Canan ÜN[2], Sena SARICAOĞLU ÖKTEM[1], Oya Kılcı[2], Burak MEMDUHOĞLU[2]

[1]Ankara Yıldırım Beyazıt Üniversitesi
[2]Ankara Şehir Hastanesi

INTRODUCTION - PURPOSE: Large thyroid masses may cause airway deviation or tracheal compression depending on the location and size of the mass. Difficult airway precautions should be taken in these patients(1).

CASE: A 55-year-old, 111 kg, 182 cm male patient who admitted to general surgery with swelling in the neck, hoarseness, and dyspnea was scheculed for total thyroidectomy. He was obese and had normal laboratory tests. Tomography revealed a 13x8x7 cm mass in the left lobe, pressing on epiglottis and other laryngeal structures, pushing and narrowing the trachea to the right. There was also left vocal cord paralysis. Videolaringoscope (Storz), laryngoscope types, supraglottic airways were available for predicted difficult airway. After standart and BIS monitorizations, induction was performed with 100 mg lidocaine, 0.1 mcg/kg/min infusion of remifentayl for 5 minutes, and 8% sevoflurane. Athough spontaneous breathing was preserved, ventilation was difficult with oral airway. When BIS was 45, patient was examined with a videolaryngoscope but epiglottis and vocal cords could not be seen. Intubation was successful with Mc Coy (number 4) laryngoscope and Eschmann introducer and was evaluated as Cormack-Lehane III. Propofol (50 mg) and rocuronium (70 mg) were added after a number 7 NIM tube was inserted. Operation was completed under balanced anesthesia with remifentanil and sevoflurane. Following 200 mg sugammadex injection the patient was extubated when he was awake and could breath spontaneously. After full recovery, he was transferred to the intensive care unit.

Large thyroid mass



Tracheal deviation



Tracheal compression

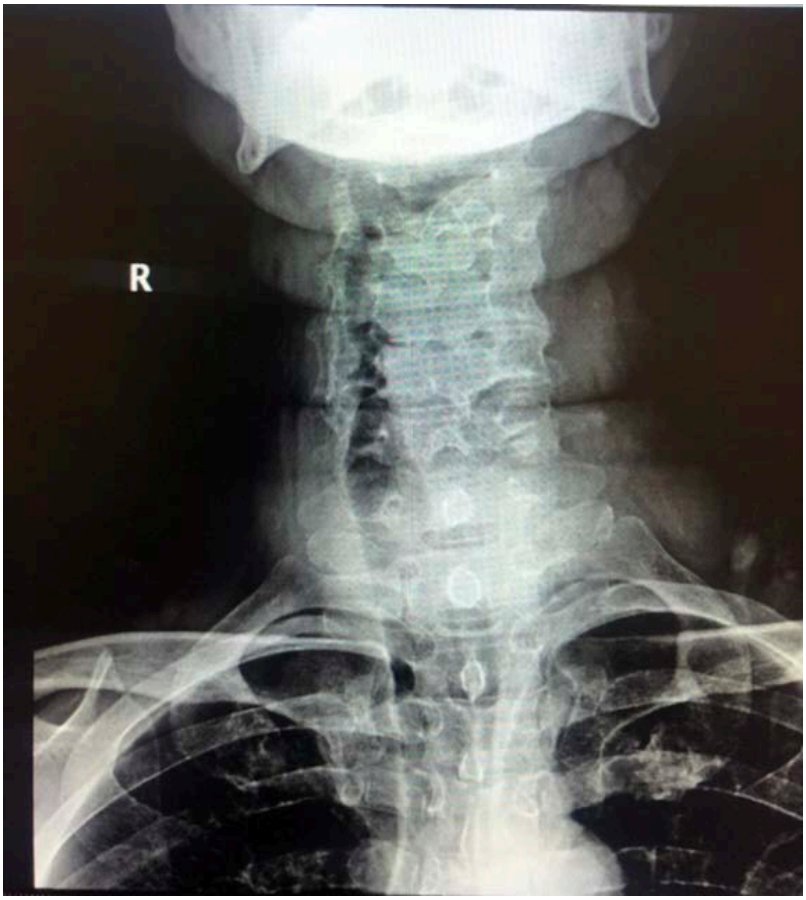

DISCUSSION - CONCLUSION: Masses in the neck carry the risk of difficult airway and tracheomalacia due to their pressure on the larynx and trachea. Depending on the size and location of the mass, intraoperative injuries can be seen in the laryngotracheal structures and esophagus.Anesthesiologist play a key role in airway management both in preoperative and postoperative periods and always be prepared with better skills and up-dated knowledge(2).

Keywords: Difficult airway, Thyroid mass

Pub No: S-014

Anesthesia Experience in Infant with Congenital Heart Block

Kübra Kaya Güney[1], Sengül Özmert[1]

[1]Ankara Bilkent City Hospital

INTRODUCTION - PURPOSE: Congenital heart block(CHB) has a mortality and morbidity of ~18%.Pacemaker implantation is required in 2/3 of cases that develop CHB.We report a case of the anesthesia management of infant with CHB, who was planned pacemaker implantation.

CASE: A 1740-g female neonate at 33-weeks of gestation was evaluated preoperatively for pacemaker implantation due to CHB.Intubated neonate who was taken over under 0.2mcg/kg/min adrenaline and 10mcg/kg/min dopamine infusion was taken to the catheter laboratory.Echocardiography showed normal cardiac anatomy.After standard monitoring, hemodynamic parameters were recorded as heart rate(HR) was 50beats/min, SpO2:100, blood pressure was 47/27mmHg.Ventilation settings were adjusted as Fi02.%100, PEEP:7, Pins:17cmH20.For the induction of anesthesia, 2mg/kg ketamine, 0.6mg/kg rocuronium and 1mg/kg lidocaine were administered to the patient who was hemodynamically unstable.Anesthesia was maintained with 1mg/kg ketamine every 25-30minutes.Pacemaker implantation was performed with angiography via the right femoral venous route. HR was recorded as 135beats/minute with the pacemaker placed at the 60th minute of the procedure.A sudden drop in HR and desaturation was observed at the 10th minute after the procedure.Any pulsation could not be obtained.In the patient for whom resuscitation was started, echocardiography was performed simultaneously. Pericardiocentesis was performed from the substernal region with the preliminary diagnosis of tamponade.5cc of blood was drained, intravenous 15cc of 0.9% isotonic NaCl was replaced.The patient's HR and SpO2 were detected as 80beats/min and 90% after pericardiocentesis.When cardiac arrest occurred again in the 10th minute, resuscitation was started.The procedure was repeated when pericardial fluid was seen in echocardiography.The patient who could not get any resuscitation response in 60 min was considered dead.

DISCUSSION - CONCLUSION: There is no optimal anesthetic method for newborns with CHB who require anesthesia for pacemaker implantation.The purpose of choosing an anesthetic agent; decrease cardiovascular depression and preventing anesthesia-related bradycardia-hypotension in newborns with hemodynamic instability.Anesthetic agent that can be preferred for this purpose may be ketamine.

Keywords: congenital heart block, anesthesia management, infant

Pub No: S-015

COVID-19 Associated Pulmonary Aspergillosis Cases in Intensive Care Units

DEMET BÖLÜKBAŞI[1], ŞERİFE GÖKBULUT BEKTAŞ[1], ÇAĞLAYAN MERVE AYAZ[2], SEVAL İZDEŞ[3]

[1]Ankara City Hospital, Department of Intensive Care, Ankara, Turkey
[2]Ankara City Hospital, Department of Infectious Disease and Clinical Microbiology, Ankara, Turkey
[3]Ankara Yildirim Beyazit University School of Medicine, Department of Intensive Care, Ankara, Turke

INTRODUCTION - PURPOSE: Patients with acute respiratory distress syndrome (ARDS) due to viral infection are at risk for secondary complications like invasive pulmonary aspergillosis. Our study evaluated coronavirus disease 2019 (COVID-19) associated invasive pulmonary aspergillosis (CAPA) at a single centre in Ankara, Turkey.

CASE: CAPA was found in nine critically ill patients with moderate to severe ARDS between April 2020 and December 2020. The median age of the patients was 63 (IQR:13), the median length of stay in intensive care unit was 54 (IQR:71.5) days, and six (66.7%) of the patients were female. The underlying disease was present in six (66.7%) patients, and all patients were treated with favipravir and steroids. Additionally, anakinra treatment was applied to six (66.7%) of the patients. All patients were followed-up under invasive mechanical ventilation and received vasopressor drug therapy. While serum galactomannan positivity was detected in all patients, four out of nine (44.4%) showed Aspergillus spp. growth in deep tracheal aspirate (DTA) or bronchoalveolar lavage (BAL) cultures, and also galactomannan positivity was observed in four out of nine (44.4%) patients' DTA or BAL samples. In the clinical follow-up of all patients, there was an increase in oxygen demand and an increased infiltration was observed in the chest radiographs. The chest computed tomography of two (22.2%) patients showed an appearance compatible with fungal infection (cavite and fungus ball). Although anti-fungal treatment was given to all patients, all of them died.

DISCUSSION - CONCLUSION: Clinicians caring for patients with ARDS due to COVID-19 should consider invasive pulmonary aspergillosis and subject respiratory samples to comprehensive analysis to detect co-infection.

Keywords: Acute respiratory distress syndrome, COVID-19, Invasive aspergillosis

Pub No: S-016

Evaluation of the Effect of Two Different Anesthesia Managements on Intracranial Pressure with Ocular Usg in Endoscopic Retrograd Colangiopancreatography (Ercp) Procedure

Melike DEMIR[1], Özlem Balkız SOYAL[2], İsmail AYTAÇ[2], Betül GÜVEN AYTAÇ[2]

[1]Kağızman State Hospital
[2]Ankara City Hospital

INTRODUCTION - PURPOSE: The aim of study is to investigate whether the ERCP procedure and anesthetic managements consisting of a combination of propofol and ketofol have an effect on the change in ICP by measuring the optic nerve sheath diameter(ONSD).

MATERIALS AND METHODS: It was conducted with 109 patients as randomized controlled, double-blind study. ONSD was measured byUSG and recorded. (T0:before induction of anesthesia, T1:after induction of anesthesia, T2:during sphincterotomy, T3:at end of procedure, T4:after patient awakening) Group K ;Ketofol mixture was prepared by adding 13cc serum saline on the drug at the rate of 100mg ketamine-300mg propofol into 50cc syringe.After the induction dose was administered at dose of 1mg/kg with perfuser, based on propofol in the mixture, 0.5cc/kg/hour ketofol infusion was started. Group P; A mixture of 300mg propofol and 15cc serum saline and propofol was prepared in 50cc syringe, and induction dose of 1mg/kg was administered with perfuser , 0.5cc/kg/hour propofol infusion was started. Changes in vital parameters, BIS,FPS and ONSD were compared between the two groups and in other time periods according to T0 within the group.

RESULTS: There was no significant difference between the two groups in the change of the mean ONSD measurement of the eyes according to T0, but an increase was found within the group during the procedure, especially in T2. There was no difference between the groups in terms of HR,SAP,DAB,MAP. SPO2 and BIS were found to be lower in group P. The amount of additional propofol, FPS, apnea score were found to be higher in groupP.

Change of mean ONSD measurement of right and left eyes according to T0

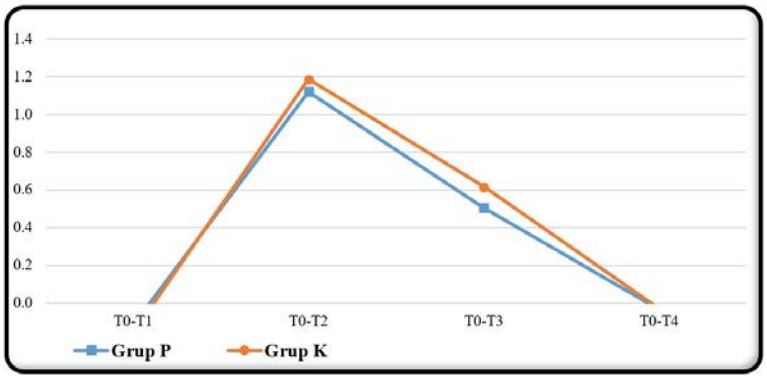

Between Groups Comparison of SpO2 Measuring Below 92%

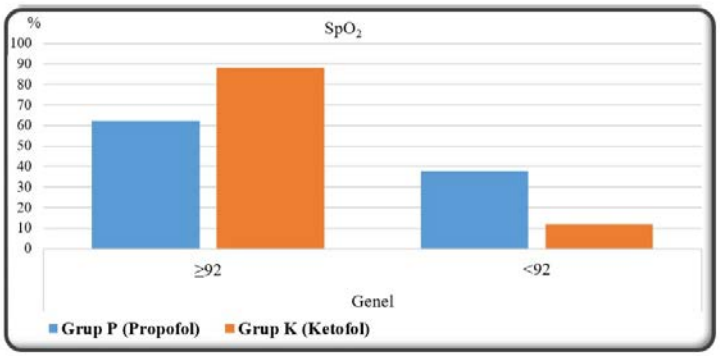

Apnea score

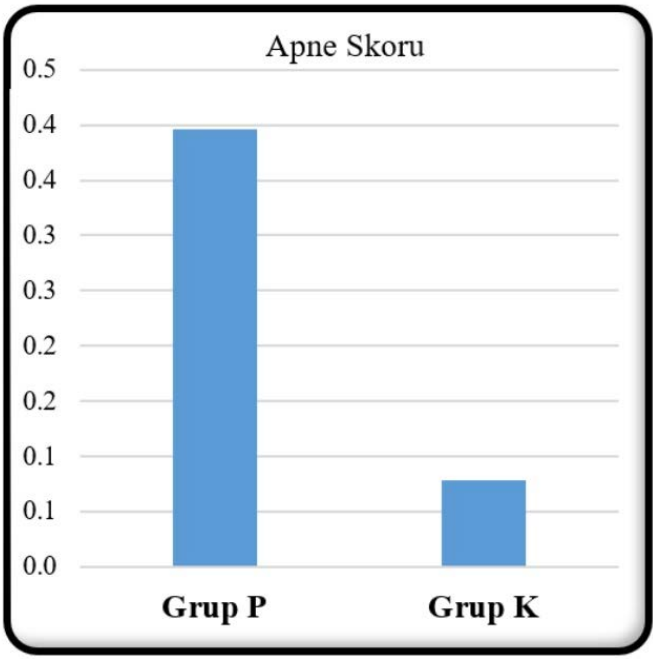

Demographic characteristics of patients in Group P and Group K

	Grup P		Grup K		Test istatistiği	p
	Ort±SS		Ort±SS			
Yaş (yıl)	54.78±14.77		59.86±12.98		t=-1.898	0.060
Kilo (kg)	75.95±15.32		74.12±12.36		t=0.680	0.498
Boy (m)	166.26±8.80		170.08±10.23		t=-2.095	0.038
BMI	27.64±6.08		25.73±4.45		t=-1.852	0.062
	n	**%**	**n**	**%**		
Cinsiyet						
Kadın	31	53.4	24	47.1	χ^2 =0.443	0.506
Erkek	27	46.6	27	52.9		
ASA						
1	10	17.2	4	7.8	χ^2 =2.159	0.340
2	30	51.7	30	58.8		
3	18	31	17	33.4		
Ek hastalık						
Yok	22	37.9	17	33.3	χ^2 =0.250	0.617
Var	36	62.1	34	66.7		

Additional amount of propofol

	Grup P	Grup K	Test istatistiği	P
	Mean±SD Ortanca (Min-Maks)	Mean±SD Ortanca (Min-Maks)		
ilave profopol miktarı	40.78±38.81 40 (0-140)	3.92±6.02 0 (0-20)	U=555.5	<0.001

Face Pain Score

DISCUSSION - CONCLUSION: In ERCP procedures with propofol and ketofol, intracranial pressure increases, mostly during sphincterotomy. Ketofol is recommended to be used as an appropriate agent in the management of ERCP anesthesia, both with the sympathomimetic and analgesic effect of ketamine, and because it does not change the intracranial pressure in the direction of increase.

Keywords: ERCP, Optic Nerve Sheath Diameter, Ketofol

Pub No: S-017

Evaluation of Publications from Turkey on Low Flow Anesthesia

Emine ASLANLAR[1]

[1]Selçuk University Medicine Faculty, Department of Anesthesiology and Reanimation, Konya, TURKEY

INTRODUCTION - PURPOSE: Low-flow anesthesia (LFA) is a technique in which at least 50% of the exhaled gas is returned into the system by rebreathing. LFA was first defined by Foldes in 1952 as an anesthesia technique in which the fresh gas flow (FGF) is reduced to 1 L/min. Virtue, described another technique in 1974, in which FGF was reduced to 0.5 L/min and named as 'Minimal Flow Anesthesia'. Baker defined FGF used in anesthetic application as moderate (1-2 L/min), low (0.5-1 L/min), minimal (0.25-0.5 L/min), metabolic flow (0.25 L/min).Although its history goes back 70 years, safety concerns have limited the use of LFA. Concerns and unknowns on this subject have led to the birth of many academic studies. The aim of this study is to evaluate the publications in the literature related to LFA from Turkey.

MATERIALS AND METHODS: The keywords "Low Flow Anesthesia, TURKEY" were searched in Google Academic, Pubmed, Web Of Science databases. The publications found were evaluated in terms of the year they were published and the journal, the language used, the preferred inhalation agent and amount of flow, the patient population, the subject of the article.

RESULTS: A total of 55 articles were found in the literature search. In our country, the first article was published in 2004, and the highest number of articles was published in 2022 (Figure 1). 22 articles have been published in journals within the scope of SCI/SCIE (Table 1). Early publications often focused on hemodynamics, cost, recovery and safety (Figure 2). The most commonly preferred agent is desflurane (Figure 3). Flow was used at 1 lt/min in 43 studies and 0.5 lt/min in 4 studies (Table 2). The patient group of only 4 studies consisted of children.

Figure 1. Publication year



Figure 2. Subjects of article

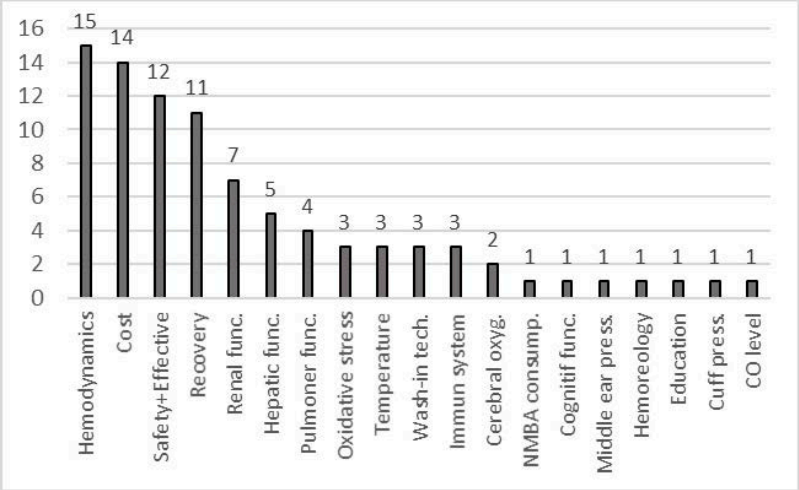

Figure 3. Inhalation agents

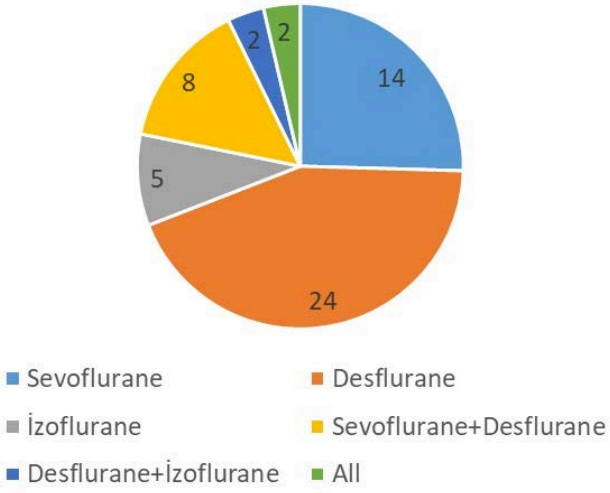

Table 1. Publication language of studies and journal indexes

index	n	%
SCI/SCIE ESCI ULAKBİM TR Index	27 17 11	49,1 30,9 20,0
Language		
Turkish English	21 34	38,2 61,8

Table 2. Classification according to fresh gas flow

Flow	**n**	%
2 lt/min	1	1,8
1 lt/ min	43	78
0,5 lt/ min	4	7,2
0,5lt/min+1lt/min	6	10,9
<0,5 lt/ min	1	1,8

DISCUSSION - CONCLUSION: Desflurane is mostly used in studies on LFA in our country, and the flow is often preferred as 1 lt/min.

Keywords: low-flow anesthesia, Turkey, anesthesia

Pub No: S-018

Our Airway Management in a Patient with an Obstructive Polypoid Lesion in the Vocal Cord

Burcin NUR BAYINDIR[1], Ela ERTEN[1], Mehmet Burak ESKIN[1], Ahmet COSAR[1]

[1]GULHANE TRAINING AND RESEARCH HOSPITAL

INTRODUCTION - PURPOSE: Ensuring patient safety in surgical procedures involving the airway is a very challenging process. Problems that may occur in both ventilation and intubation in these patients should be predicted by the anesthesiologist and necessary preoperative preparations should be completed.

CASE: A direct laryngoscopy/biopsy procedure was planned for a pedicled polypoid lesion in the right vocal cord of a 38-year-old, ASA II male patient by the Ear, Nose&Throat Clinic. In the preoperative evaluation, we evaluated the movement of the polypoid lesion associated with inspiration and expiration by following the patient's endoscopic imaging. We thought that the patient with a short thick neck, macroglossia, mallampati score of 4 would have difficult ventilation and difficult intubation. After tracheostomy preparation, video laryngoscopy and various numbers of endotracheal tubes were ready in the operating room, we started anesthesia induction. In the first attempt for intubation under video laryngoscopy, the polypoid lesion obstructed the vocal cord and we could not insert the endotracheal tube. When we switched to mask ventilation again, we could not adequately ventilate the patient. Thereupon, quickly we asked the surgical team to position the polypoid lesion in the second intubation attempt with video laryngoscopy. We used an aspirator because we thought that the polypoid lesion might rupture or bleed with forceps. We successfully completed the procedure by placing a 5.5 numbered endotracheal tube under the polypoid lesion, which was brought to the anterior position with an aspirator.

1



ENDOSCOPIC IMAGE OF VOCAL CORD POLYP

2

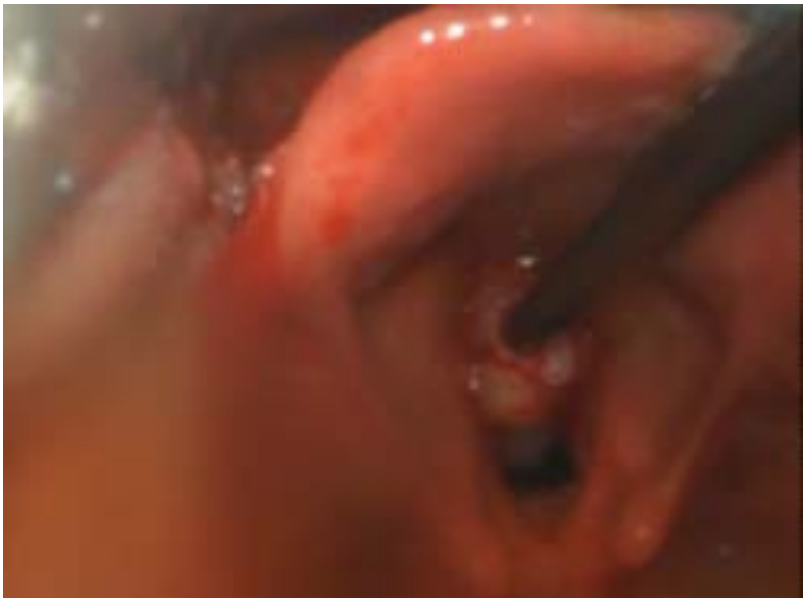

THE POLYP WAS POSITIONED WITH AN ASPIRATOR

3

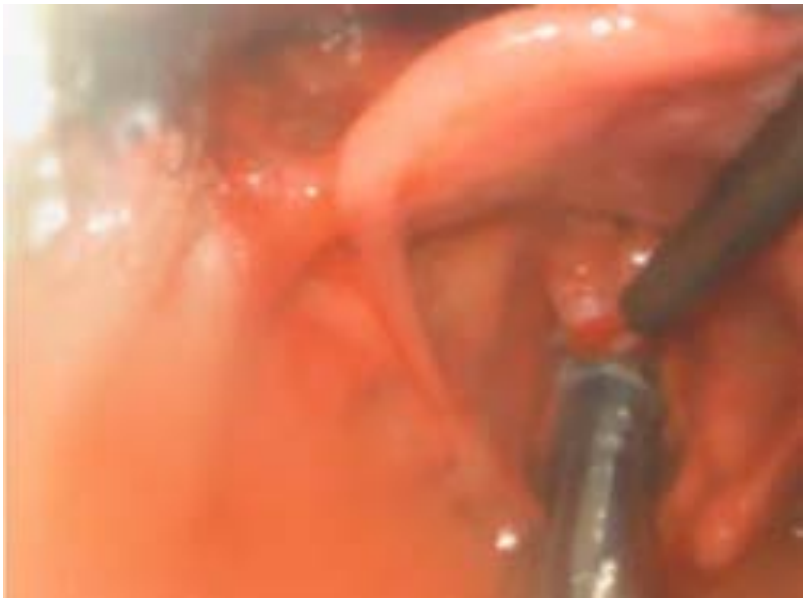

ENDOTRACHEAL TUBE WAS SUCCESSFULLY PLACED

DISCUSSION - CONCLUSION: Advanced airway precautions should be taken in advance in order to ensure the success of the procedure and prevent the development of complications in patients who have an airway-related surgical plan and are predicted to have difficult ventilation and difficult intubation. In this process, it is vital to evaluate the patient with the surgical team, to use video laryngoscopy, and to prepare for an emergency tracheostomy.

Keywords: DIFFICULT AIRWAY, VOCAL CORD POLYP, ANESTHESIA

Pub No: S-019

The Effect of Combined Serratus Anterior Block on Postoperative Analgesia and Morphine Consumption in Three Cases of Mastectomy

Esra Onhan Tekoğlu[1], Musa Zengin[1], Berrin Koşar[1], Ali Alagöz[1], Hilal Sazak[1]

[1]Ankara Ataturk Sanatorium Traning and Reseach Hospital Univercity of Health Sciences

INTRODUCTION - PURPOSE: Acute postoperative and persistent pain are widespread despite minimally invasive breast surgery. Serratus anterior block (SAB), which can be applied deep or superficially to prevent pain after breast surgery is a known analgesic method(1). In this case report, we aimed to evaluate the postoperative pain parameters of 3 patients who underwent combined SAB for postoperative analgesia in breast surgery.

CASE: Data of three patients who underwent modified radical mastectomy and combined SAB were analyzed with their informed consent. Patients were administered 10 ml 0.25% bupivacaine for superficial SAB, and 10 ml for deep SAB, before surgery. The patients monitored according to ASA standards were operated under general anesthesia. Patients were administered intravenous patient-controlled analgesia using morphine solution (0.5 mg/cc) for postoperative analgesia. Patient demographic information, 24-hour morphine consumption, analgesia-related side effects, additional analgesia needs, and postoperative 1st, 2nd, 4th, 8th, 16th, and 24th-hour visual analog scale (VAS) scores were recorded. The mean age of the patients was 55.6 years and body mass index was 30.6 kg/m2. Duration of anesthesia was 135 min. Mean block application time was 180 seconds. Postoperative VAS scores were below 4 in follow-up. No patient needed additional analgesia. Morphine consumption was 9.3 mg on average. Nausea and itching were observed in one patient with higher morphine consumption compared to the others.

DISCUSSION - CONCLUSION: We thought that effective postoperative analgesia could be provided with the combination of deep and superficial SAB in breast surgery. The fact that there is no need for additional analgesics in the postoperative period suggests that this method is effective. It is also one of the advantages of SAB that it is easier and more reliable than chest wall blocks. Prospective randomized controlled trials can guide the evaluation of the efficacy of this block method.

Keywords: Acute pain, Breast surgery, Serratus anterior block, Combined serratus anterior block, Postoperative analgesia

Pub No: S-020

Anaesthetic management of a case of Duchenne muscle dystrophy with Williams syndrome

Rahimegul Yekebas[1], Sule Arican[1], Turgut Celik[1], Turgay Atay[1], Halime Suslu Celik[1], Resul Yilmaz[1]

[1]Department of Anaesthesiology, University of Necmettin Erbakan, Medical Faculty, Konya, Turkey

INTRODUCTION - PURPOSE: Patients with Williams syndrome have increased morbidity and mortality under sedation and anesthesia. Generally,difficult airway is expected in patients with Williams syndrome by characteristic face.Patients with Duchenne muscular dystrophy are at an increased risk of developing extreme hyperthermia,rhabdomyolysis and hyperkalemic cardiac arrest when exposed to halogenated inhalational anaesthetics and depolarizing muscle relaxants.We aimed to present the successful anaesthetic management of a case of Williams Syndrome withDuchene muscular dystrophy who underwent dental procedure under general anaesthesia.

CASE: A 6-year-old male was scheduled for dental surgery under general anesthesia. Prior to induction of anaesthesia, all the vaporizers were dismounted from the anaesthesia machine, fresh soda lime was filled into the soda lime canisters and the breathing circuits were changed. Difficult mask ventilation and tracheal intubation were anticipated because of micrognathia,dental anomalies,long upper lip,and a Mallanpati class III airway. Before induction of anesthesia the patient breathed 100% oxygen for 3 minutes. Anesthesia was induced and maintained with propofol, remifentanil and rocuronium bromide. Mask ventilation was easily performed. The video laryngoscopic view was Cormack grade I and there was no difficulty in the tracheal intubation. Anaesthesia was maintained with 60% nitrous oxide-oxygen-propofol-remifentanyl and rocuronium. The child was kept in the intensive care unit for 48 h. He was discharged from the hospital on the 3th postoperative day.

Figure



DISCUSSION - CONCLUSION: According to the most previous clinical reports in patients with Williams syndrome in Japan,mask ventilation and tracheal intubation were performed easily contrary to preoperative airway assessment. The anaesthetic concerns in a child with Duchenne muscular dystrophy are the possibilities of difficult intubation,prolonged duration of neuromuscular block,possible need for postoperative ventilation and occurrence of rhabdomyolysis and cardiac arrhythmias when exposed to halogenated volatile anaesthetic agents and depolarizing muscle relaxants. We should select the optimal strategy for airway and anesthesia management in patient of Duchenne muscle dystrophy with Williams syndrome.

Keywords: Anaesthesia, Duchenne muscle dystrophy, Williams syndrome

Pub No: S-021

Determination of COVID-19-Associated Sarcopenia by measurements made from thoracal tomography

Nazan Has Selmi[1], Erdem Özkan[1], Duygu Kayar Çalılı[1], Behiye Deniz Kosovalı[1], Belgin Akan[1]

[1]Health Sciences University Ankara City Hospital

INTRODUCTION - PURPOSE: For the diagnosis of sarcopenia, the quality and mass of the skeletal muscle should be known.Abdominal computed tomography(CT) is considered the gold standard method.The inability to use abdominalCT in every disease group is a major disadvantage.Evaluation of thoracic skeletal muscles is important in various disease groups.It has been reported that acute muscle weakness and sarcopenia develop as a result of widespread systemic inflammation and hypercatabolic state observed in COVIDpatients followed in the ICU(1).We aimed to present the sarcopenia, which we determined by measurements made from thoraxCT at different times of the patient we followed up in the ICU for COVIDpneumonia.

CASE: A 69-year-old male patient with no known comorbidity developed fever while being followed up in the geriatric clinic.The PCR test was positive.He was admitted to the ICU because of infiltrates in the thoraxCT taken due to hypoxemia.He was intubated due to increased respiratory distress.He was followed up for 10 days in MV.Percutaneous tracheotomy was performed on the 17th day of intubation due to weaning difficulty.He was lost on the 37th day of his admission.Thoracic CT, which was taken first in the emergency room and then in the intensive care unit one month later, was examined.Measurements were made at the level of the T8 vertebral body,where the pectoral muscles were best seen.The skeletal muscle area (SMA) at this level was measured as 16.09cm² and 15.87cm², respectively.

Figure 1

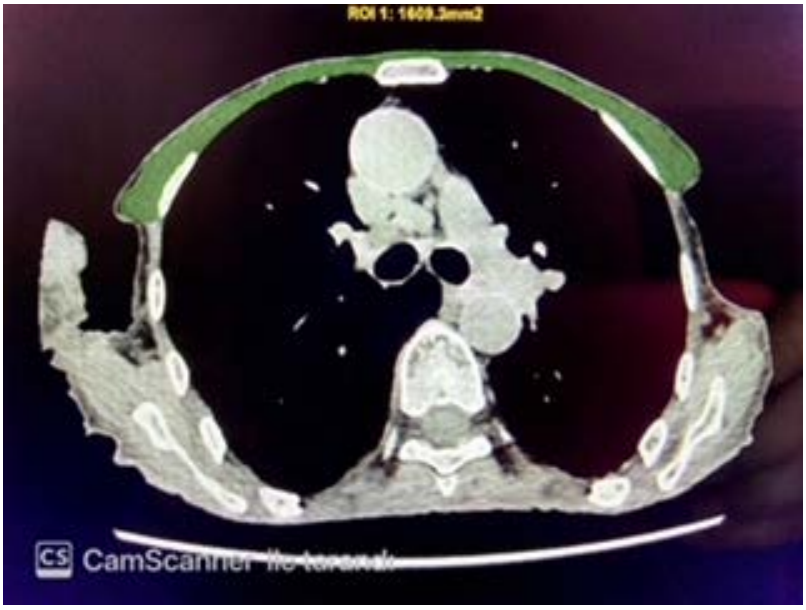

Pre-COVID period

Figure 2

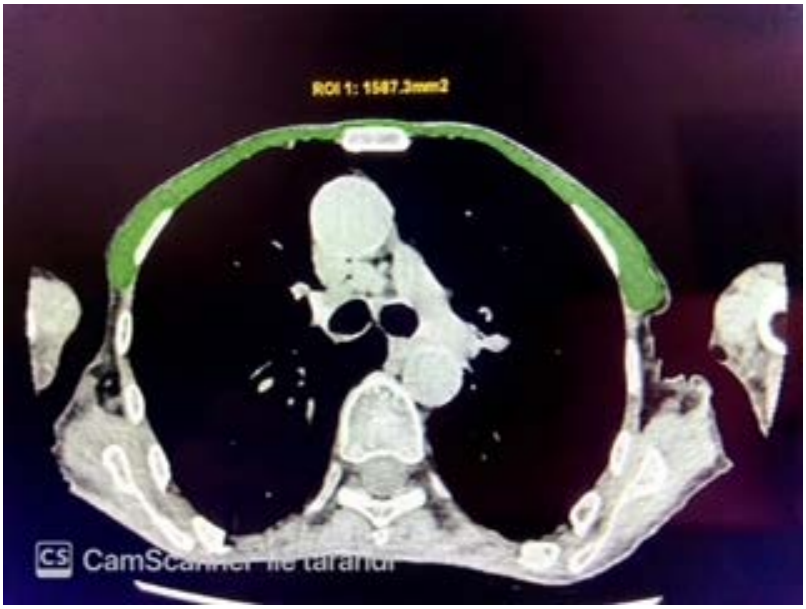

Post COVID

DISCUSSION - CONCLUSION: As seen radiologically in our case, there was a decrease in the measurement of pectoralis major and minor muscle areas at the T8 level within a month.Weaning difficulty during follow-up due to COVID pneumonia, prolonged hospitalization in the ICU, decrease in SMA in thoracic CT suggested sarcopenia.It was concluded that it would be useful to carry out studies in order to diagnose sarcopenia with measurements to be made at the level of the thoracic vertebrae.

Keywords: Sarcopenia, Thoracic computed tomography, COVID-19, Intensive care unit

Pub No: S-022

Anesthesia Management in Laparoscopic Bariatric Surgery: A Retrospective Analysis

Nuran Akıncı Ekinci[1]

[1]Konya City Hospital

INTRODUCTION - PURPOSE: In obese patients, perioperative anesthesia management differs among patients because of the changing anatomy and physiology of obese patients. This study aimed to evaluate the anesthesia management and perioperative results in patients who underwent laparoscopic sleeve gastrectomy (LSG) in our hospital.

MATERIALS AND METHODS: In this retrospective study, the data of 87 patients who underwent LSG were analyzed. Demographic characteristics, mallampati scores, ASA classification, smoking, monitorization, duration of surgery, analgesics consumption, perioperative complications, and length of stay (LOS) were recorded.

RESULTS: Twenty of the patients (23%) were male, and 67 (77%) were female. The mean age was 35 (min.20-max. 60). Fifteen patients(17,2%) were ASA II, and 72 (82,8%)were ASA III. The mean BMI was 46.94±9.45, and 41 (47,1%) patients were smokers. Twenty-nine patients (33,3%) had previous abdominal surgery. While 64 (73,6%) patients were mallampati II, 22 (25%) were mallampati III. The mean duration of surgery was 126±41.53 minutes. All patients were admitted to the intensive care unit (ICU) in the postoperative period. The average LOS in the ICU and hospital was 27±3 hours and 4.46±1.88 days, respectively. For postoperative analgesia, narcotic analgesic was applied to 57 patients, and multimodal analgesia was applied to 28 patients. Cardiac arrest developed in one patient in the postoperative care unit. The patient was admitted to the ICU after cardiopulmonary resuscitation. Respiratory distress was observed in 16 (18,4%) patients, and hypertensive attack was observed in 2 (2,3%) patients.

DISCUSSION - CONCLUSION: The incidence of difficult intubation, pulmonary aspiration, respiratory and cardiac complications has increased in obese patients. While making an anesthesia plan, these issues should be considered, and it should be prepared for possible complications. A good preoperative patient preparation, ideal anesthetic agent selection, appropriate ventilation strategies, and postoperative care can reduce the risk of expected complications.

Keywords: Obesity, Bariatric Surgery, Bariatric Anesthesia

Pub No: S-023

585 Gram Prematüre Hastada Torakoskopik Töf Onarımı Sırasında Anestezi Yönetimi: Olgu Sunumu

Yusuf Yılmaz[1], Sengül Özmert[2]

[1]Kayseri Develi Dr. Ekrem Karakaya Devlet Hastanesi
[2]SBÜ Ankara Şehir SUAM

INTRODUCTION - PURPOSE: Esophageal atresia(EA) and tracheoesophageal fistula(TEF) are the most common congenital anomalies of the esophagus. In these cases, increased mortality and morbidity rates are associated with extremely low birth weight (ELBW) infants(<1000gr). In this case report, we aimed to share our anesthesia management in an extremely low birth weight premature newborn patient who was operated for OA/TEF.

CASE: 585gr female baby with a gestational age of 28 weeks, diagnosed with OA/TEF and intubated, was examined preoperatively and taken to the operating room with plans for thoracoscopic TEF repair and gastrostomy on the postnatal 7th day. There was a patent foramen ovale on echocardiography, and the patient was receiving dopamine infusion at a dose of 5µg/kg/min. Patient was monitored, connected to the anesthesia device and manually ventilated. The operating room was heated and a heat probe was placed on the patient. The extremities were wrapped with cotton. The patient received 0.6ml/h dopamine and 3.5ml/h %5dextrose infusion, and an additional 5ml/h saline infusion was started. A total of 3mg of ketamine and 0.2mg of rocuronium bromide were administered to the patient intermittently. Throughout the case, SpO2 was %97-98, EtCO2 was 25-30mmHg, and heart rate was around 120-130bpm. Patients blood sugar was measured as 125mg/dL, body temperature was 36.7C. During the case, a total of 18ml of fluid was given to the patient, including drugs. TEF clip procedure was applied over the right hemithorax thoracoscopically in the prone position, then, gastrostomy was opened with a median incision above the umbilicus in the supine position. Total surgery time was 70 minutes and anesthesia time was 90 minutes. The patient was transferred to the neonatal intensive care unit as intubated.

Patient



Patient on the operating table



DISCUSSION - CONCLUSION: Fluid management of ELBW infants should be aimed at maintaining intravascular volume, renal and cardiovascular functions. Hypothermia precautions should be taken and hypoglycemia should be avoided.

Keywords: Premature Infant, Anesthesia, Esophageal atresia, Tracheoesophageal fistula, Extremely Low Birth Weight

Pub No: S-024

Difficult Airway Management in Patient with Achondroplasia

Nevriye SALMAN[1], Aslıhan AYKUt[1], Asena Irem YILDIZ[1]

[1]Ankara City Hospital SUAM, Department of Anesthesiology and Reanimation

INTRODUCTION - PURPOSE: Achondroplasia is the most common form of osteochondroplasia, which is characterized by skeletal dysplasia, abnormal cartilage and skeleton as a result of impaired enchondral bone formation(1,2). Patients are characterized by macrocephaly, shortness of extremity long bones, airway and spinal anomalies(3). These patients may also have sleep apnea, obesity, and neurological dysfunction due to spinal stenosis and scoliosis(49. In this case, we tried to explain our difficult intubation approach to an achondroplastic patient with scoliosis and tracheal deviation.

CASE: CABG operation was planned for a 59-year-old, 160cm, 65kg male patient with achondroplasia, whose consent was obtained. In the physical examination of the patient who did not have any additional comorbidities, head and neck movements were limited and mallampatiIII was evaluated as difficult intubation.Chest radiography revealed that the trachea was deviated to the right and scoliosis was present.Video laryngoscope, guide, bougie etc were available for the patient who was thought to have difficult intubation.Anesthesia induction was performed with propofol, rocuronium and fentanyl in the patient who was monitored and preoxygenated.Although the vocal cord and trachea were deviated to the right, the patient was easily intubated with video laryngoscope. The patient, who was extubated eight hours later, was discharged 5 days later without complications.

Figure 1.



Mallampati assessment of the patient.

Figure 2.

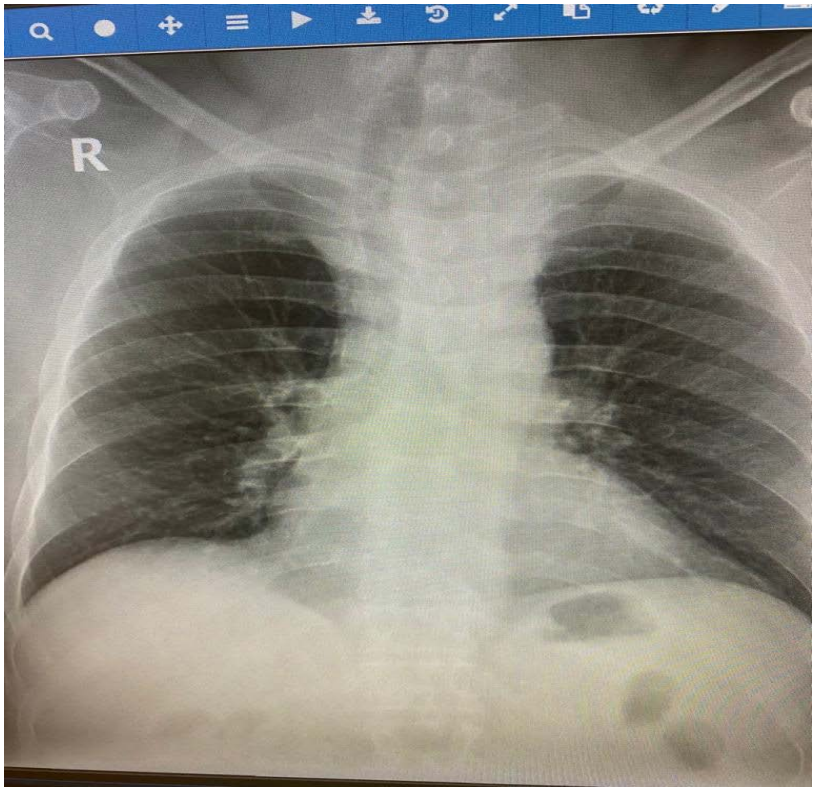

Posteroanterior chest X-ray

Figure 3



Videolaryngoscopy image

DISCUSSION - CONCLUSION: Difficult intubation is a common problem in achondroplasia. In this patient, the presence of mallampatiIII and limited neck extension as well as tracheal deviation suggested difficult intubation. Therefore, we used direct video laryngoscopy with difficult intubation preparation and performed endotracheal intubation in one go without causing trauma.It should be kept in mind that there may be tracheal deviation as well as difficult intubation in patients with achondroplasia, and preparation for difficult intubation should be made. In addition, we believe that these patients should be evaluated thoroughly preoperatively and complete preparation of the difficult airway can prevent complications that may develop.

Keywords: Achondroplasia, difficult intubation, anesthesia

Pub No: S-025

Our Case of Cerebral Salt Wasting Syndrome(CSWS) in Intensive Care Unit After Epidural Hematoma(EH) Drainage

Ali KOC[1], Hasan ERTAS[1], Erbil TURKSAL[1]

[1]ANKARA ATATURK SANATORYUM TRAINING AND RESEARCH HOSPITAL

INTRODUCTION - PURPOSE: Electrolyte imbalance is frequently seen in traumatic brain injury (TBI) patients, and CSWS, which is seen with hyponatremia and hypovolemia, is one of these entities. It is characterized by low plasma osmolality; high serum osmolality, high urinary sodium, high urine output, and high BNP levels. Its differential diagnosis should be made well with the syndrome of inappropriate secretion of anti-diuretic hormone(SIADH) , since their clinical presentations are similar but the treatment is the opposite.

CASE: A 42-year-old male patient with no known disease was operated under emergency conditions by the neurosurgery department due to acute epidural hematoma in the occipital region. The patient was presented to the emergency room due to ear bleeding and clouding of consciousness. The hematoma was drained by lifting the occipital bone after that the area was irrigated with normal saline. The patient was taken to the intensive care unit as intubated. On the 14th postoperative day, due to the decrease in serum sodium to around 120 mEq/L and the patient's increased urine output, CSWS was considered as preliminary diagnosis. BNP was requested to support the diagnosis, but it was found to be normal, yet urinary sodium and osmolality were increased. A 3% hypertonic NaCl infusion was started at a rate of 40 cc/h to the patient who had also a hypotensive course.

DISCUSSION - CONCLUSION: CSWS is a rare condition that can be seen in TBI patients, and EH has been reported in the literature as an uncommon cause of CSWS. Pathophysiology of this syndrome is still unclear yet this diagnosis should not be forgotten in intensive care unit. The differential diagnosis with SIADH is vital for the initiation of the right treatment. It also should be kept in mind that the desired BNP will not always be high to support the diagnosis.

Keywords: Cerebral Salt Wasting Syndrome, Hyponatremia, SIADH, Epidural Hematoma, Traumatic Brain Injury

Pub No: S-027

Modified Radical Mastectomy with PECS Block in a Patient with Advanced Pulmonary Hypertension: Case Report

Güldeniz ARGUN[1], Aylin KONDILOĞLU[1], Süheyla ÜNVER[1]

[1]UHS Dr Abdurrahman Yurtaslan Ankara Oncology Training and Research Hospital

INTRODUCTION - PURPOSE: Anesthesia management in patients with pulmonary hypertension (PH) is particularly critical since it may cause fatal complications. Intraoperative sympathetic system activation, hypoxemia, hypercapnia, mechanical ventilation (especially higher PEEP levels) can originate acute right ventricular (RV) decompensation. Moreover, postoperative pain, abdominal distention, and fluid overload may worsen the limited RV functions (1, 2). In this case, we performed the pectoral nerve blocks (PECs) for mastectomy surgery (3).

CASE: 72-year-old female patient with systemic scleroderma, solitary kidney, and PH (pulmonary artery pressure, PAP>100mmHg) was admitted. Her oxygen saturation (SpO2) was 63% before surgery while using an O2 concentrator 24/7. PECs block was considered as the optimal approach to avoid the complications of general anesthesia. Midazolam 0,25 mg IV and ketamine 25 mg IV was administered preoperatively. USG-guided PECs 1 and 2 blocks were applied. 100% oxygen therapy was given. The patient was breathing spontaneouslySpO2 was between 60-70%, respiratory rate was 20±5, tidal volume was 150±10, and heart rate was between 70-80 during the surgery. Her blood pressure was between 132/84 and 110/70 mmHg. Modified radical mastectomy (MRM) was performed in 150 minutes in sitting position. 500 ml of crystalloid was administered. The patient was stable 30 minutes after surgery and sent to her room with oxygen therapy. Oral feeding was allowed in the second postoperative hour. There were no postoperative complications related to anesthesia or surgery.

DISCUSSION - CONCLUSION: In patients with PH, the perioperative risk must be evaluated for each individual patient. Severe PH (PAP >25 mmHg), RV dysfunction, dyspnea, and the urgency, duration, and type of surgery increase the risk of perioperative complications. Peripheral nerve blocks provide effective analgesia while maintaining cardiovascular stability.In conclusion, we think that PECs blocks provide adequate anesthesia for MRM surgery and can be an effective option in patients with advanced PH to avoid hemodynamic instability and prevent cardiovascular complications.

Keywords: Pulmonary hypertension, pectoral nerve blocks, modified radical mastectomy

Pub No: S-028

Management of a Case Developing Resistant Anaphylactic Shock in Hydatid Cyst Surgery

Osman KAYA[1], Gülay ERDOĞAN KAYHAN[1], Meryem ONAY[1], Yeliz KILIÇ[1]

[1]Eskisehir Osmangazi University Anaesthesiology and Reanimation

INTRODUCTION - PURPOSE: One of the common complications of a hydatid cyst is rupture of the cyst during surgery or after trauma. Rupture can cause allergic reactions, anaphylactic shock, or even death. We aimed to share the management of resistant anaphylactic shock in a patient with pacemaker.

CASE: The patient with pacemaker due to a complete atrioventricular block underwent laparoscopic surgery due to a hydatid cyst in the liver. Sudden hypotension developed at the 55th minute of surgery. The surgical team reported that they only injected hypertonic saline and there was no leakage in the surgical area. Lung sounds were normal and airway pressures were within normal limits. Considering that there may be a problem with the pacemaker, the magnet was removed but the hypotension did not improve. The surgical procedure was stopped, the patient was placed in a head-down position, and ephedrine was administered. Five minutes later, rashes developed on the trunk; diffuse lung wheezing, elevated airway pressure, and desaturation were observed. Repeated intravenous adrenaline was administered (10, 20, and 50µg, respectively) and rapid fluid infusion was started. Methylprednisolone, pheniramine, salbutamol, and aminophylline were given due to continued widespread wheezing. Blood pressure increased to 110/70mmHg in 25minutes after all interventions. Laparotomy was performed and cystectomy was completed.

DISCUSSION - CONCLUSION: Intraoperative sudden hypotension can be caused by many different pathologies such as hemorrhagic shock, acute myocardial infarction, anaphylactic shock, pulmonary embolism, and complications of laparoscopic surgeries. In this case, the initial presentation with sudden hypotension and the late appearance of skin rashes and respiratory symptoms made the differential diagnosis difficult. The presence of pacemaker prevented to evaluate ST segment analysis and tachy-bradycardia. In conclusion, it should be considered that an anaphylactic reaction may develop without significant macroscopic rupture, and diagnosis and treatment may be difficult in complex patients.

Keywords: Anaphylaxis, Anaphylactic Shock, Hydatid Cyst, Resuscitation

Pub No: S-029

Anesthesia Management With Femoral And Popliteal Block Combination In The Case That Does Not Accept Central Regional Block Application

Sena SARICAOĞLU ÖKTEM[1], Mehmet ŞAHAP[1], Umut ÖKTEM[2]

[1]Ankara Yıldırım Beyazıt Üniversitesi
[2]Ankara Şehir Hastanesi

INTRODUCTION - PURPOSE: Although central regional blocks are widely used in lower extremity surgeries, peripheral nerve blocks may be preferred when contraindicated(1).

CASE: A 25-year-old ASA II male patient, who was a smoker, had bullet entry hole in the medial of the right foot calcaneal region as a result of gunshot wound, and a full-thickness skin defect on the lateral at the tarsometatarsal joint level, and widespread defects in the muscles and tendons were present. There were comminuted fractures of the talus and calcaneus. The patient had been operated many times under spinal anesthesia, but he did not accept spinal anesthesia for the debridement and VAC replacement surgery, which was planned for the last time, because he felt pain in the intraoperative operation area and postoperative low back pain, but smoked 1 hour before the operation. For this reason, general anesthesia was not preferred by us, and right femoral and popliteal block application was planned. Under ultrasound (US) guidance, the femoral nerve was seen next to the right femoral artery in the supine position. Femoral block was performed using 10 ml of 0.5% bupivacaine and 10 ml of 2% prilocaine with a 50 mm block needle. After the patient was placed in the left lateral decubitus position and the sciatic nerve was visualized, 10 ml of 0.5% bupivacaine and 5 ml of 2% prilocaine were applied in plane with a 50 mm block needle.After waiting for thirty minutes, motor and sensory block was evaluated, and the surgical procedure was started. The surgical procedure was completed without the patient's need for additional intraoperative analgesia and sedation.

Suturized bullet entry hole,



Widespread defects in the muscles and tendons



DISCUSSION - CONCLUSION: Peripheral nerve block combinations are advantageous in lower extremity surgery as they provide postoperative analgesia and short recovery time(2).In our case, the patient's anxiety was relieved by successful blockade, and intraoperative and postoperative patient comfort was provided.

Keywords: femoral block, peripheral nerve blocks, popliteal block

Pub No: S-030

Anesthesia Management in a Spinal Muscular Atrophy Type 3: A Case Report

Burak NALBANT[1]

[1]Ankara City Hospital

INTRODUCTION - PURPOSE: Spinal muscular atrophy (SMA) is a neuromuscular disease characterized by degeneration of motor neurons of the spinal cord. We aimed to share our anesthetic approach to a type 3 SMA patient who will undergo scoliosis surgery.

CASE: A 19-year-old female patient was diagnosed with SMA at the age of 2.5 was evaluated preoperatively to undergo scoliosis surgery. On physical examination and history, it was seen that upper and lower extremities had 4/5 motor power, significant scoliosis, walking with support, decreased cervical lordosis, limited neck movements, mallampati score of 2, and other findings were normal. Before the operation, the anesthesia circuit was renewed and dantrolene was kept ready. Anesthesia induction was performed with lidocaine, propofol, fentanyl, and rocuronium. She was intubated with the video-laryngoscope. TIVA were used for the maintenance of anesthesia. BIS, temperature probe, invasive blood pressure measurement and urine monitoring were performed during the operation. 650 ml of blood was lost, 2600 ml of crystalloid was given and no blood transfusion required. End of the operation, neuromuscular blockade was reversed with sugammadex the patient was extubated and sent to the ICU.

Preoperative chest X-ray

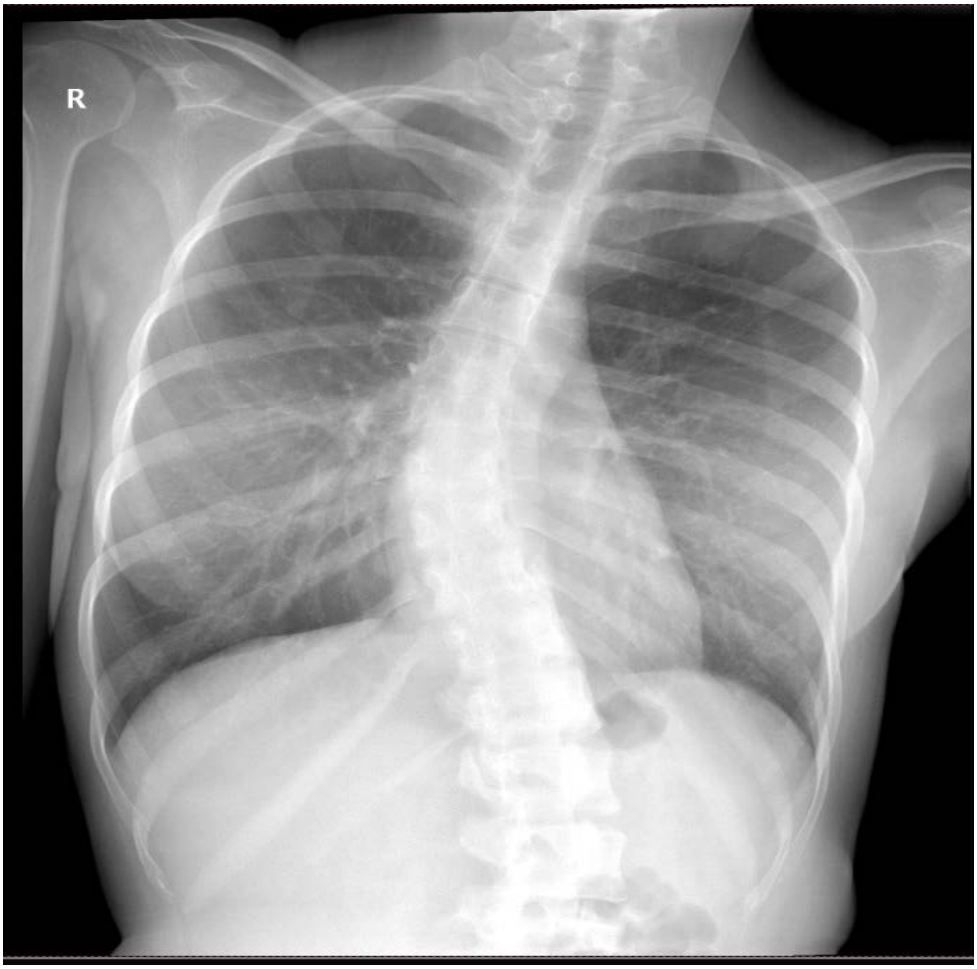

DISCUSSION - CONCLUSION: SMA is an autosomal recessive inherited disease a higher prevalence in our country due to consanguineous marriages. These patients may require anesthesia for different surgical operations. There are various risks associated with anesthesia. Some of these risks are; difficulties in airway management, respiratory failure, gastroesophageal reflux, and restrictions in the use of muscle relaxants. Decreased mouth opening, limitation of motion in the cervical vertebrae increase the possibility of intubation difficulties. Restrictive lung disease can be seen in patients with SMA due to inspiratory muscle weakness and spinal deformities. In conclusion, it should be kept in mind that SMA disease can cause different complications. We should be alert for complications and necessary planning should be done in the perioperative period.

Keywords: scoliosis, spinal muscular atrophy, type 3 sma

Pub No: S-031

Determination of Preoperative Anxiety and Depression Levels of Patients Scheduled to Have Elective Surgery

Eda MACIT AYDIN[1], Oya SAYGILI KILCI[2], Duygu KAYAR ÇALILI[3], Nezihe Ferah DÖNMEZ[4], Canan ÜN[2]

[1]Etlik City Hospital, Department of Intensive Care, Ankara, Türkiye
[2]Ankara City Hospital, Department of Anesthesiology and Reanimation, Ankara, Türkiye
[3]Ankara City Hospital, Department of Intensive Care, Ankara, Türkiye
[4]Polatlı Duatepe Hospital, Department of Anesthesiology and Reanimation, Ankara, Türkiye

INTRODUCTION - PURPOSE: Preoperative anxiety incidence of 10–90% in patients undergoing surgical procedures. In the literature, different scales are used to evaluate preoperative anxiety. The aim of this study is to determine the possible association between preoperative anxiety levels and HAD scale in patients scheduled for elective surgery.

MATERIALS AND METHODS: This study is a prospective cross-sectional survey performed at Numune Training and Research Hospital between May 2012 and December 2012. After excluding the patients who did not meet the criteria for inclusion(n:67), 731 patients were included in the study. Data were collected for each patient using a personal information form and HAD.

RESULTS: The mean age of the patients included was 37.1±13.6 years, and 51.3%(n:375) were female. Anxiety was detected in 22.6%(n:165) of the patients, and depression was detected in 34.6%(n:253). The mean age of patients with anxiety (38.9±12.80) was significantly higher (p=0.002). There was a significantly higher level of anxiety in females than in males (p<0.001). It was determined that the patients who did not work had a higher level of anxiety (p=0.001). It was founded that as the education level increased, the rates of anxiety and depression decreased (p<0.001). The presence of comorbidity and higher ASA score were associated with high anxiety rates (p=0.001). In this study, we found that increased procedure risk (grade 4 according to Johns Hopkins Surgical Risk Classification System) was associated with a high anxiety rate. However, anxiety was lower in patients scheduled for bariatric surgery (p<0.001) (Table 1-2).

DISCUSSION - CONCLUSION: Preoperative anxiety is still common and associated with poorer postoperative outcomes. Therefore, patients should be evaluated routinely. We consider that approaches to reduce anxiety and anxiolytic premedication to be applied if necessary are as important as medical interventions. HAD can be beneficial in assessing anxiety and thus optimizing perioperative care. Less anxiety will bring better success (1,2).

Table-1: Factors affecting anxiety and depression

	Anxiety (n:165)	**p-value**	**Depression (n:253)**	**p-value**
Gender (n,%)				
Female	109 (%29.1)	**<0.001**	138 (%36.8)	0.201
Male	56 (%15.7)		115 (%32.3)	
Age (year, mean±SD)	38.9±12.8	**0.002**	35.2±13.4	0.302
ASA score (n,%)				
ASA-I	41 (%18.5)	**0.001**	52 (%23.4)	**<0.001**
ASA-II	110 (%22.8)		185 (%38.3)	
ASA-III	10 (%50)		11 (%55)	
ASA-IV	4 (%66.7)		5 (%83.3)	
Presence of comorbidity(n,%)				
Exist	69 (%30.1)	**0.001**	101 (%44.1)	**0.001**
None	96 (%19.1)		152 (%33.1)	
Comorbidity(n,%)				
Malignancy	50 (%67.6)	**<0.001**	39 (%52.7)	**0.001**
Hypertension	14 (%30.4)	0.188	16 (%34.8)	0.980
COPD	10 (%50)	**0.003**	9 (%45)	0.322
CAD	10 (%38.5)	**0.04**	16 (%61.5)	**0.003**
DM	9 (%32.1)	0.217	12 (%42.9)	0.350

CVD	3 (%20)	0.551	7 (%46.7)	0.321
Working status(n,%) Employed Unemployed	58 (%17.2) 107 (%27.2)	**0.001**	105 (%31.2) 148 (%37.6)	0.070
Educational status (n,%) Literate Illiterate	160 (%22.3) 5 (%41.7)	**0.015**	246 (%34.2) 7 (%58.3)	0.080
Habitation (n,%) Urban Rural	143 (%21.8) 22 (%29.3)	0.139	215 (%32.8) 38 (%50.7)	**0.002**
Health insurance (n,%) Insured Uninsured	156 (%22.2) 9 (%34.6)	0.208	242 (%34.3) 11 (%43.3)	0.400

SD: standart deviasyon, ASA: American Society of Anesthesiology, COPD: Chronic obstructive pulmonary disease, CAD: Coronary artery disease, DM: Diabetes mellitus, CVD: Cerebrovasculer disease.

Table-2: The effect of the surgery on anxiety and depression according to the Johns Hopkins surgical risk classification

	Anxiety (n:165)	**p-value**	**Depression (n:253)**	**p-value**
Surgery grade(n,%)				
Grade 1	11 (%9.2)		39 (%32.5)	
Grade 2	64 (%15.4)	**<0.001**	132 (%31.7)	0.156
Grade 3	59 (%40.1)		61 (%41.5)	
Grade 4	29 (%63)		20 (%43.5)	
Grade 5	2 (%100)		1 (%50)	
Morbid obesity surgery (n,%)	1 (%10)	**<0.001**	4 (%40)	0.802
The other grade 4 surgeries (n,%)	28 (%77.8)		16 (%44.4)	

Keywords: Preoperative anxiety, Hospital anxiety-depression scale, Anesthesia, Surgical procedures

Pub No: S-032

Anaesthetic management of a case of Crisponi syndrome

Turgut CELIK[1], Sule ARICAN[1], Gokhan KOCADAG[1], Halime SUSLU CELIK[1], Gulcin BUYUKBEZIRCI[1], Resul YILMAZ[1]

[1]Department of Anaesthesiology, University of Necmettin Erbakan, Medical Faculty, Konya, Turkey

INTRODUCTION - PURPOSE: Crisponi syndrome is a rare and severe inherited disorder characterized by unexplained elevations of high fever with muscle spasms, trismus, apnea, feeding problems, and multiple organ Failure. Diagnostic criteria include micrognathia, torticollis, facial and skeletal abnormalities. They show muscle contractions, including respiratory muscle contractions with trismus and opistotonus, in response to mild stimulation, painful stimuli, or during cryingWe aimed to present the successful anaesthetic management of a case of a 5-year-old patient with Crisponi syndrome during tooth extraction under general anesthesia.

CASE: A 5-year-old boy with Crisponi syndrome.was planned for Tooth extraction and root canal treatment under general anesthesia The patient had a typical facial appearance, hand contractures and scoliosis. The patient's temperature measured from the skin in the premedication room was 36.8.Anesthesia was induced with intravenous anesthetics. Anesthesia was maintained with 2-2.5 % sevoflurane and IV 5 ml/h of remifetanil. Peroperative intranasal body temperature was monitored, increase in body temperature wasn't observed in the follow-ups. The temperature in the operating room was strictly monitored and maintained at 19ºC. Surgical and perioperative periods passed uneventfully.

Figure 1



Figure 2



DISCUSSION - CONCLUSION: Thirteen years ago, Bonthuis and colleagues listed the possible anesthetic complications of Crisponi Syndrome and related inherited syndromes, highlighting the lack of evidence, particularly regarding the risk of anesthesia. We also found that there are very few studies on this syndrome in preoperative research. Fever attacks in Crisponi syndrome result from the CRLF1 mutation, which differs from the physiological pathway underlying malignant hyperthermia.In our case, the inhalation agent was administered safely without causing an increase in temperature.

Keywords: Anaesthesia, Crisponi syndrome, Temperature

Pub No: S-033

The Effects Of Different Anesthesia Applications On Emotion, Depression And Anxiety Levels In Burn Patients

Ayça Tuba DUMANLI ÖZCAN[1], Betül AKAYCAN[2], Serdar Süleyman CAN[2], Özlem KARAKAYA[2], Emine SÖNMEZ[1], Ahmet Çınar YASTI[2], Orhan KANBAK[1]

[1]Ankara City Hospital, SBÜ, Anesthesiology and Reanimation Clinic
[2]Ankara City Hospital, SBÜ, Psychiatry Clinic

INTRODUCTION - PURPOSE: It was aimed to investigate the effects of ketamine-provided sedation burn patients terms of mood, depression, anxiety, and suicidality during postoperative intensive care follow-ups.

MATERIALS AND METHODS: 67 patients aged between 18-65 years, ASAI-II, with basic communication skills, who had not been diagnosed with psychiatric disease before, who didn't have a history of neuropsychiatric or cognitive disease or related treatment were included. After preoxygenation, anesthesia was induced general anesthesia group with 2mg/kg IV propofol and 1mcg/kg IV fentanyl. Anesthesia was maintained with 0.3-0.5mcg/kg/min remifentanil, 2%sevoflurane, 50%-50% air-oxygen. Sedation group, 1mcg/kg IV fentanyl and 1mg/kg IV ketamine were administered in induction, and anesthesia was maintained by adding 30-50mg IV propofol if necessary. Montgomery-Asberg Depression Rating Scale(MADRS), Hamilton Anxiety Rating Scale(HAM-A), Beck Suicidal Ideation Scale, applied preoperatively and 1st postoperative day.

RESULTS: In group evaluations; It was determined that MADRS values for the patient group who underwent sedo anesthesia were statistically significantly decreased postoperative period compared to the preoperative period, however, MADRS values in the general anesthesia group didn't reveal a statistically significant difference postoperative period compared to the preoperative period.It was determined that HAM scores were statistically significantly decreased in both anesthesia groups compared to the pre-anesthesia period.Evaluations of the Beck suicidal ideation scale, it was obtained that there was no patient with suicidal ideation.

Table 1

	General anesthesia (n=35)	Sedo anesthesia (n=32)	p^1
	Location±Ss	Location±Ss	
MADRS (pre-anesthesia)	13,06±5,35	14,44±7,22	0.375*
MADRS (after anesthesia)	12,00±7,15	11,63±5,49	0.813*
	p^2=0.189**	p^2<0.001**	
HAM (pre-anaesthesia)	7 (3-25)	9,5 (2-17)	0.811***
HAM (after anesthesia)	6 (1-29)	6 (2-14)	0.949***
	p^2=0.015****	p^2<0.001****	
BECK (pre-anaesthesia)	0 (0-1)	0 (0-5)	0.578***
BECK (after anesthesia)	0 (0-1)	0 (0-1)	0.594***
	p^2=0. 317****	p^2=0.102****	

* T Texts
** T Test in dependent groups
*** Mann Whitney U Testi
Wilcoxon Sequential Signs Test

Comparison of MADRS, HAM score and BECK score values between and within groups before and after anesthesia

Table 2

	General anesthesia (n=35)	Sedo anesthesia (n=32)	p^1
	Location±Ss	Location±Ss	
Blood pressure (before anesthesia)	130,86±10,46	127,81±8,22	0.193*
Blood pressure (during anesthesia)	140,86±14,57**[a]	143,91±13,48**[a]	0.379*
Blood pressure (after anesthesia)	132,14±16,68	133,75±14,19**[a]	0.674*
	p^2<0.001**	p^2<0.001**	
Pulse rate (pre-anesthesia)	83,86±10,00	82,97±12,23	0.745*
Pulse rate (during anesthesia)	91,14±11,70**[a]	93,13±12,36**[a]	0.503*
Pulse rate (after anesthesia)	82,29±11,96	84,53±11,38	0.435*
	p^2<0.001**	p^2<0.001**	
* T Texts ** In repetitive measurements ANOVA ([a]Post hoc: Bonferroni)			

Comparison of blood pressure and pulse rate values between and within groups before and after anesthesia

Table 3

		Group		Sum	p
		General (n, %)	Sedo (n, %)		
Additional dose	No	26 (%74,3)	25 (%78,1)	51 (%76,1)	0.713*
	Where	9 (%25,7)	7 (%21,9)	16 (%23,9)	
Sum		35 (%100,0)	32 (%100,0)	67 (%100,0)	
* Chi-square Test					

Comparison of need for additional doses by groups

DISCUSSION - CONCLUSION: In literature, safe and effective reduction depressive symptoms has been achieved with subanesthetic ketamine infusions in patients with treatment-resistant depression. MADRS, decrease of 64% was found with ketamine monotherapy and 28% for midazolam(1). Compared with midazolam, single subanesthetic infusion of ketamine resulted safe and significant reduction in depressive symptoms(2).Depending on the trauma experienced by burn patients, potential for depression, anxiety disorder and suicidal tendencies may be high. We think that sedo anesthesia provided with ketamine in these patients may reduce mood, depression, anxiety and suicidal tendencies at the postoperative period.

Keywords: Depressıon, Ketamine, Beck Suicidal Ideation Scale

Pub No: S-034

Airway Management in an Adult Patient who Operated for Arnold-Chiari Type I: Combined Use of Videolaryngoscopy and Elastic Gum Boogie, and VIDIAC Score

Umut Cahit ERSOY[1], Nadide Aysun POSTACI[1]

[1]Ankara City Hospital

INTRODUCTION - PURPOSE: Arnold-Chiari Malformation (ACM) is characterized by herniation of the cerebellar tonsils down into the spinal canal and its most common type is ACM type 1. We present opered an ACM type 1 patient who intubated via videolaryngoscopy and elastic gum boogie in this case report.

CASE: 56 y, 56 kg woman, for interval debulking surgery due to ovarian cancer. Seven years ago with headache, extremity pain, vertigo, hypoesthesia and impaired coordination. Arnold-Chiari Type I was diagnosed and she had been operated for it. MMT score: 2, interincisor gap ≥ 2.5 cm and neck movements were partially restricted In addition to standard anesthetic monitoring, BIS and TOF monitoring (kinemyography of the Aisys CS2 GE anesthesia device) were also performed before induction. Premedication given by 2 mg of midazolam. Fentanyl 2 mcg/kg, lidocaine 80 mg, propofol 2.5 -2.5 mg/kg, and rocuronium 0.6 mg/kg was induced after three minutes of preoxygenation. Intubated with Storz branded videolaryngoscopy and elastic gum boogie. VIDIAC score, used for easing of VL 0 (-1-5),CL score 1. The elastic gum boogie was sent between vocal cords, endotracheal tube was advanced over it. Patient was intubated easily without neck movements thorough these steps. Anesthesia maintenance: BIS %45-50, Et-sevoflurane 1.8-2 %, Et-O2 at 32 % and air. Remifentanyl: 0,1-0,2 mcg/kg/min. Extubation: under deep anesthesia with 200 mg sugammadex.

1

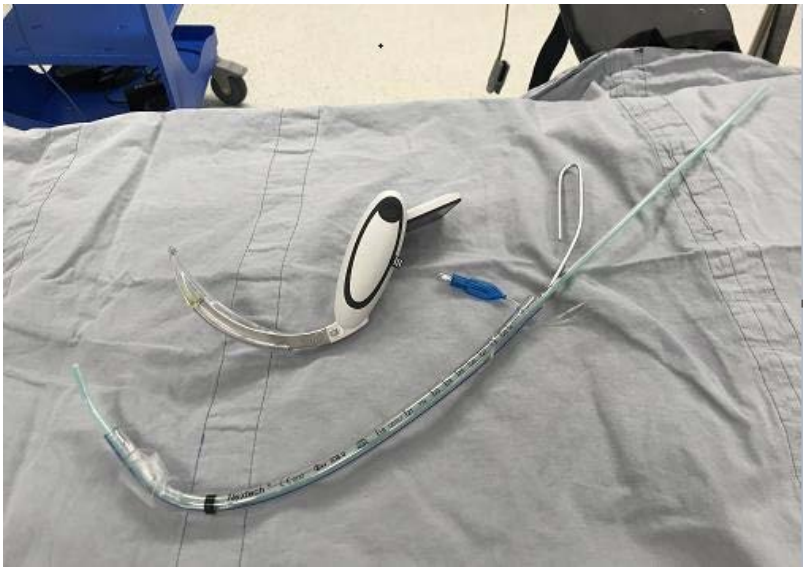

2



3

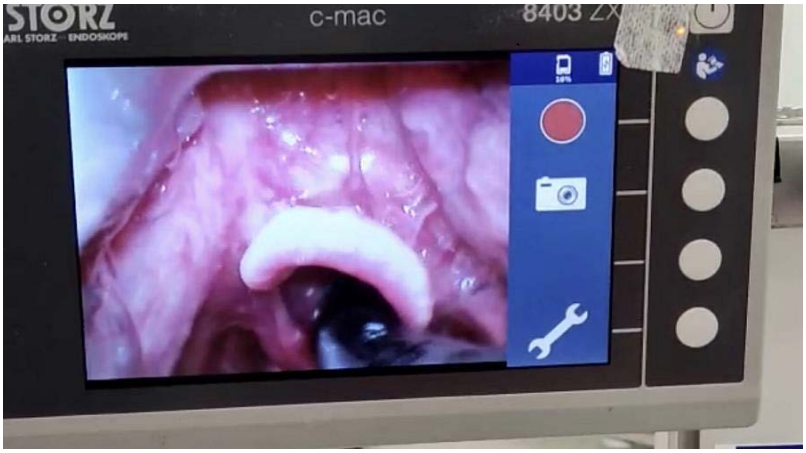

DISCUSSION - CONCLUSION: General anesthesia, especially during laryngoscopy and tracheal intubation, might lead to increase in ICP or cerebrospinal fluid pressure gradient. Sleep apnea, prolonged expiratory apnea with cyanosis, and aspiration pneumonia are other potential breathing risks associated with ACM. For avoiding any flexion and extension of the neck, especially during induction, fiberoptic intubation or videolaryngoscopy is recommended. In the anaesthesia management of ACM patients, it is recommended to avoid cranial pressure increases, avoid aspiration, and avoid coughing, which increases CSF pressure during extubation.

Keywords: Arnold Chiari, Videolaryngoscopy, VIDIAC, Combined

Pub No: S-035

Our Non-cardiac Surgery Experience in a Patient with LVAD: Multidisciplinary Approach

Eda UYSAL AYDIN[1], Efe Volga ÖZKAN[1], Ezgi ERKILIÇ[1], Tülin GÜMÜŞ[1], Orhan KANBAK[1]

[1]Ankara City Hospital

INTRODUCTION - PURPOSE: Heart failure is a case group with high morbidity and mortality, and its prevalence is increasing withthe aging population. LVADs (left ventricle assist device) are used in addition to medical treatmentsin heart failure. These devices provide benefits such as symptomatic improvement, shortening ofhospital stay, and bridging therapy for cardiac transplantation. As the life expectancy and the numberof patients with LVAD increases day by day, these patients are seen more frequently in non-cardiacsurgeries. In this presentation, we aimed to review the anesthesia management in a patient withLVAD who will undergo tracheostomy.

CASE: A 63-year-old female patient with cardiac arrhythmia, diabetes mellitus, hypertension, acute renalfailure and heart failure who had Hearhmate III LVAD inserted 3 months ago, was taken to theoperating table for surgical tracheostomy due to prolonged intubation. Preoperative transthoracicecho reported as; EF: 15-20%, 2-3 Mitral İnsuffiency, 3 Tricuspit İnsuffiency and heart movementswere global hypokinetic. Before surgery LVAD settings were made. The patient, who was taken to theoperating room with noradrenaline infusion, was administered 1mg Midazolam, 0.5 mcg/kg Fentanyl,0.6 mg/kg Rocuronium after monitoring. Mechanical ventilator adjustments were made andanesthesia was maintained with a mixture of Desflurane-Oxygen-Air. During the operation, a nurseexperienced in LVAD was ready in the operation room. During the 30-minute procedure, nocomplications developed, no LVAD adjustment required, and no blood replacement performed. Afterthe procedure; patient transferred to the intensive care unit monitorized, tracheostomized andsupported with a portable mechanical ventilator without any complications.

DISCUSSION - CONCLUSION: As in the case we presented above, hemodynamic changes caused by LVAD during non-cardiacsurgery and the need for anticoagulation are among the most common problems in anesthesiapractise. At the same time LVAD patients are prone to newly developing cardiac arrhythmias. Weaimed to keep the mean arterial pressure between 70-90 mmHg and avoiding volume overload inour patient during the case. We avoided hypoxia, hypercapnia and acidosis. We would like to pointout that in this type of patients; in whom complex pathophysiological mechanisms are active, oneshould be careful about end-organ damage and a multidisciplinary approach is required.1. Lancet 2018;391:5725802. Eur Heart J. 2021 Sep 21;42(36):3599-37263. Anesth Analg. 2018 Jun;126(6):1839-1850.

Keywords: Non-cardiac Surgery, left ventricle assist device), surgical tracheostomy

Pub No: S-036

Combined Axillary Brachial Plexus Block And Spinal Anesthesia In Selected Patient

Esra ONHAN TEKOĞLU[1], Merve SARIYILDIZ PEHLIVAN[1], Erbil TÜRKSAL[1]

[1]Ankara Ataturk Sanatoryum Training and Research Hospital

INTRODUCTION - PURPOSE: In orthopedic surgery, regional anesthesia provides advantages in various aspects such as difficult airway, gastric aspiration, postoperative nausea and vomiting, and postoperative analgesia compared to general anesthesia. We will present a case of combined axillary brachial plexus block and spinal anesthesia in a patient with a narrow mouth opening due to a burn scar around the mouth and assumed to be difficult intubation for whom flap reconstruction was planned from right thigh to right hand fingers.

CASE: In the preoperative anesthesia evaluation of a 53-year-old, 100 kg, 185 cm ASA-1 male patient, the mouth opening was very narrow due to the burn scar around the chin, mouth and lips (Figure-1). Elective regional anesthesia was planned for the patient with a high risk of difficult intubation. After hemodynamic monitoring in the operating room, he was sedated with 0.03 mg/kg IV midazolam. 10 ml of 2% lidocaine, 20 ml of 0.25% bupivacaine in USG guidance, using an 80 mm 22 G nerve block needle (Stimuplex, Braun) with in-plane technique, axillary brachial plexus block was performed on the patient (Figure-2A,2B). Then, spinal anesthesia was performed with 3 ml of 0.5% hyperbaric bupivacaine through L4-5 space in sitting position (Figure-3). The operation took a total of 4 hours. There was no need for additional analgesics and sedatives during the operation.

Figure-1



Figure 2



Figure 3



DISCUSSION - CONCLUSION: Today, anesthesiologists prefer regional anesthesia more than general anesthesia in terms of providing many advantages in surgeries where regional techniques are possible. We also think that the combined application of spinal anesthesia and axillary brachial plexus block will be useful in terms of patient comfort, anesthesia follow-up and reducing the possibility of complications, unless there are contraindications in surgeries where the lower extremity and upper extremity will be operated simultaneously.

Keywords: axillary brachial plexus block, spinal anesthesia

Pub No: S-037

Anesthesia Management of A Newborn With Prolonged QT İnterval And Operated For İntestinal Atresia: A Case Report

Hülya KAŞIKARA[1]

[1]Ankara City Hospital

INTRODUCTION - PURPOSE: The long QT syndrome (LQTS), classified as congenital or acquired, is a disorder of myocardial repolarization predisposing to life-threatening ventricular arrhythmias, particularly torsades de pointes. In this case, the anesthesia management of a newborn who was found to have prolongation of the QT interval on the 1st day of his birth and was operated due to ileojejunal atresia was shared.

CASE: A male baby born at 37 weeks of gestation, weighing 3100 grams, was operated for ileojejunal atresia. A prolonged QT (44-48 sec) interval was detected in the ECG taken before the operation (Figure 2). The patient was intubated after induction of anesthesia with intravenous fentanyl (1.5mcg/kg), ketamine (0.5 mg/kg), propofol (1.5 mg/kg) and rocuronium (0.5mg/kg). Low-dose propofol infusion (4mg/kg/hour) and sevoflurane at a MAC level of 0.5 were administered for anesthesia maintenance. Heart rate remained stable between 120-125/min throughout the operation. No arrhythmia or bradycardia was observed. After being extubated, he was transferred to the surgical intensive care unit.

figure 1. Radiographic image



Figure 2. intraoperative ECG image

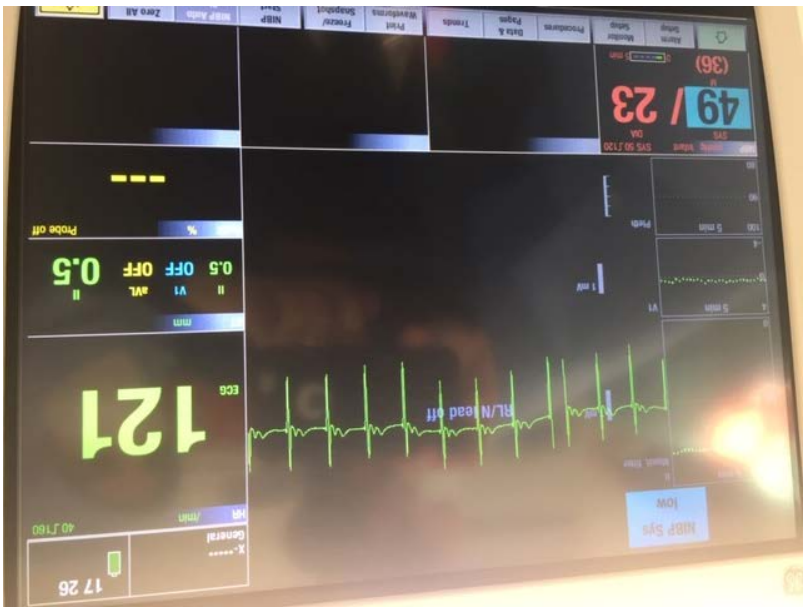

DISCUSSION - CONCLUSION: Patients with long QT syndrome are at risk of developing Torsades de pointes (TdP), known as polymorphic ventricular tachycardia, in the perioperative period. Seizures secondary to TdP, ventricular fibrillation and sudden cardiac death may occur in these patients. In our case, besides the risk of developing fatal arrhythmia during the operation, a very challenging anesthesia management was performed due to the fact that she was a 2-day-old newborn. During the operation, a controlled defibrillator and esmolol were kept ready in the room. Optimal hemodynamics was achieved by using low doses of volatile and intravenous anesthetics together in the induction and maintenance of anesthesia. Patients should be carefully followed throughout the operation and the necessary equipment for the emergency should be available in the room.

Keywords: Long QT syndrome, Newborn, General Anesthesia

Pub No: S-038

Our Pediatric Supraclavicular Brachial Plexus Nerve Block(SBPB) Procedure

Ali KOC[1], Adem SELVI[1], Erbil TURKSAL[1]

[1]ANKARA ATATURK SANATORYUM TRAINING AND RESEARCH HOSPITAL

INTRODUCTION - PURPOSE: Peripheral Nerve Block(PNB) is a form of regional anesthesia technique that can be used to shorten the postoperative recovery period and to protect patients from the systemic effects of anesthesia where general anesthesia(GA) cannot be applied or is applied with high risk when surgery cannot be delayed. Pneumothorax is the most feared complication but it has started to be applied more safely with the increasing use of US in pediatrics too.

CASE: An ASA-1, 8-year-old male patient with a Supracondylar Humerus Fracture(SCHF) was evaluated and it was seen that the patient had URTI signs(runny nose, cough) and his lung sounds became coarser. After the pediatrics consultation, it was decided that GA was high risk in these conditions. A written informed consent for applying SBPB was obtained from the family. The patient was monitored and premedicated with 1 mg midazolam, 10 mcg remifentanil and 10 mg ketamine IV and was taken to the theater. Brachial plexus structures, subclavian artery and pleura were seen in the supraclavicular fossa under US guidance. Local anesthetic injection(2% lidocaine 5 ml, 0.5% bupivacaine 10 ml) was performed using the in-plane technique. After the needle was removed, the sliding motion of the pleura was observed with US and it was confirmed that there was no pneumothorax. The patient had spontaneous breathing and did not need additional anesthetic and analgesics throughout the case. His vital signs remained stable. Neurological examination was found normal after 12 hours.

US image



Supraclavicular fossa structures after LA injection.

DISCUSSION - CONCLUSION: GA increases postoperative atelectasis in the presence of URTI and is associated with perioperative hypoxia.SBPB was preferred in this case both because it can be administered as a single dose and because of its long duration of action, which can reduce the need for additional painkillers in postoperative period. Use of US enabled to exclude pneumothorax at the end of the procedure immediately.

Keywords: Pediatric upper extremity surgery, Brachial plexus block, Pediatric anesthesia, Regional anesthesia, Supraclavicular

Pub No: S-039

Complicated Pleural Effusion As a Rare Complication in Stevens-Johnson Syndrome: Case Report

Selman KARADAYI[1], Melike CENGİZ[2], Murat YILMAZ[2], Burcu ÇELİK[3], Onur KÜÇÜK[4]

[1]Kirklareli Research and Training Hospital
[2]Akdeniz University Hospital
[3]Antalya Kepez State Hospital
[4]Ankara Ataturk Sanatorium Research and Training Hospital

INTRODUCTION - PURPOSE: Stevens-Johnson syndrome (SJS) and toxic epidermal necrolysis (TEN) are severe cutaneous adverse reactions, frequently due to medication and are associated with mortality and morbidity (1). Pulmonary complications are significant causes of morbidity, predominantly presented with bronchiolitis obliterans, chronic bronchitis, and interstitial lung disease (2-4). Our aim is to present a case of a 29-year-old man who suffered from chronic pulmonary complications concomitant to SJS.

CASE: The patient was admitted to intensive care unit (ICU) with drug induced SJS. Respiratory insufficiency of the patient was treated with non-invasive ventilation. In this period, the patient was treated with pulse steroid and cyclosporine. After 36 days of intensive care, the patient was discharged without major pulmonary symptoms. However, the pulmonary symptoms recurred during the patient's follow-up in the clinic. Pulmonary tomography revealed unilateral pulmonary effusion with partial atelectasis and pleural thickening. On the 49th day of the onset of symptoms, the patient was admitted to the ICU for the second time and intubated. Since the effusion fluid could not be drained externally due to septa formation, the patient underwent thoracotomy, decortication and wedge resection. The patient was extubated on the 6th postoperative day, and was discharged to the clinic later on.

DISCUSSION - CONCLUSION: Although SJS and TEN primarily affect the skin in most patients, it can also present with serious pulmonary complications leading to invasive surgical procedures and ICU admission (5, 6). Bone marrow transplantation recipients are frequently presented by pulmonary manifestations (7). Immunosuppressive treatment may be the precipitant factor for progression of infectious pulmonary complications in our patient. Our present case exhibits that patients with SJS and TEN are prone to pulmonary complications. We recommend, pulmonary complications of SJS and TEN should be observed meticulously.

Keywords: stevens-johnson syndrome, toxic epidermal necrolysis, chronic pulmonary complications, pleural thickening, decortication

Pub No: S-040

The Effects of Hypertension in Operating Room on Intraoperative and Postoperative Hemodynamics

Gülsen Keskin[1], Bengü Kocaman[1], Oya Kale[1], Selime Elif İşlek Aksoy[1], Gözde Bumin Aydın[2]

[1]Department of Anesthesiology and Reanimation, Etlik City Hospital, Ankara, Turkey
[2]Department of Anesthesiology and Reanimation, Dışkapı Yıldırım Beyazıt Training and Research Hospital, Ankara, Turkey

INTRODUCTION - PURPOSE: Hypertension in operating room during non-cardiac surgery may predispose to intraoperative hemodynamic instability with a prevalence of 25%. In this study, it was aimed to determine the preoperative risk factors of patients with a preoperative blood pressure of 140/90 mmHg and above and to investigate their effects on intraoperative hemodynamics.

MATERIALS AND METHODS: Noncardiac elective surgery cases in the study were included in the study who were over the age of 18 and agreed to participate. Demographic data of the patients, ASA physical status, comorbidities and drugs, operation history, smoking, urea and creatinine values were recorded. Blood pressure (BP) measurements above 140/90 mmHg of the patients who were taken to the operating room without premedication were accepted as hypertension. Patients' surgeries postponed whose BP did not fall below 180/110 mmHg after sedation with 0.03 mg/kg. Systolic blood pressure (SBP), diastolic blood pressure (DBP), mean arterial blood pressure (MABP) and heart rate (HR) values were recorded in intraoperative and postoperative anesthesia care unit (PACU).

RESULTS: The mean age of 307 patients included in the study was 49.06±15.69 years and the mean body mass index (BMI) was 27.76±5.01. Demographic data and clinical characteristics of the patients are given in Table 1. BP measurements of 47.9% patients on the operating table were above 140/90 mmHg. In the intraoperative and PACU, 63% patients had a hypotensive attack lasting longer than 5 minutes (Figure 1). In our group, hypertension in operating room was found to be associated with age, weight and BMI ($p<.001$) (Table 2). Hypertension in operating room was associated with previous surgery and the presence of comorbidities, but not with smoking (Table 3).

Table 1. Demographic data and clinical characteristics of the patients

Parameters	Values
Age (year)	49.06 ± 15.69
Height (cm)	168.45 ± 8.78
Weight (kg)	78.60 ± 13.87
BMI (kg/m²)	27.76 ± 5.01
ASA physical status I/II/III/IV, n (%)	53/215/38/1 (17.3/70.0/12.4/0.3)
Comorbidity Yes/No, n (%)	147/160 (47.9/52.1)
Operation history Yes/No, n (%)	180/127 (58.6/41.4)
Smoking Yes/No n (%)	146/161 (47.6/52.1)
Operation	
Urology	169 (55.0)
Neurosurgery	43 (14.0)
General Surgery	41 (13.4)
Plastic and reconstructive surgery	21 (6.8)
Orthopedics	17 (5.5)
ENT	16 (5.2)

Table 2. The relationship of hypertension in operating room with age, weight and BMI

Parameters	Hypertension in Operating Room		
	Yes	No	*p*
Age (year)	43.50 (18.00 - 77.00)	57.00 (20.00 - 88.00)	<.001
Height*(cm)	75.00 (42.00 - 125.00)	85.00 (43.00 - 111.00)	<.001
Weight*(kg)	167.00 (149.00 - 191.00)	170.00 (150.00 - 190.00)	.256
BMI*(kg/m²)	167.00 (149.00 - 191.00)	28.06 (16.98 - 39.54)	<.001
* Mann–Whitney U test			

Table 3. The relationship of hypertension in operating room with previous operation, comorbidity and smoking

Parameters	Hypertension in Operating Room						
	No		Yes		Total		*p*
	n	%	n	%	n	%	
Operation history*							.047
No	74	46.5	52	35.4	127	41.4	
Yes	85	53.5	95	64.6	180	58.6	
Comorbidity*							.001
No	98	61.3	62	42.2	160	52.1	
Yes	92	38.8	85	57.8	147	47.9	
Smoking*							.371
No	80	50.0	81	55.1	161	52.4	
Yes	80	50.0	66	44.9	146	47.6	
*Chi-square test; **Fisher Exact test							

DISCUSSION - CONCLUSION: It should be kept in mind that hypertension in operating room isassociated with advanced age and increased BMI and patients with comorbidities may be the cause of hemodynamic instability.

Keywords: Hypertension in operating room, perioperative morbidity and mortality, preoperative hypertension

Pub No: S-041

Intraoperative Hiccups During Tympanaplasty Surgery

Alpay KARAÇAM[1], Yasemin AKÇAALAN[1], Ezgi ERKILIÇ[1], Tülin GÜMÜŞ[1], Orhan KANBAK[1]

[1]BILKENT CITY HOSPITAL

INTRODUCTION - PURPOSE: Hiccup is a laryngeal closure following the sudden onset of irregular contractions of diaphragm and intercostal muscles. The abrupt air rush into lungs elicits a sound. A reflex arc including peripheral phrenic, vagal and sympathetic pathways and central midbrain modulation is conceivably responsible for hiccup. What we would like to present to you with this case report is the case of the resistant hiccups which we encountered during the ear surgery under general anesthesia that we followed up with neuromonitorization.

CASE: A 21-year-old male patient who has no history of any diseases except celiac was preliminary diagnosed with chronic otitis media. The induction of general anesthesia with Lidocaine 1mg/kg, Propofol 180mg, Fentanyl 100mcg and Rocuronium 50mg. A combination of Remifentanil and Propofol was used as a total intravenous anesthesia (TIVA) for maintenance of anesthesia. The first hiccup was noticed at the 40th minute of the operation. Consequently, Prednol 100 mg, Feniramin 45.5mg, Atropine 0.5mg and Metoclopramide 10mg were administered as a treatment respectively. Subsequently, Propofol was stopped and Sevoflurane was started. The hiccups weren't suppressed in spite of all the remedies. The hiccups had not suppressed in spite of all the remedies until Rocuronium 20mg administration after the surgical team stopped using the neuromonitoring. He was awoken with Sugammadex 200mg administration after the surgery finished. The hiccups continued for one hour after the surgery and went away by itself without any interventions.

DISCUSSION - CONCLUSION: Acute hiccup that occurs during surgery may cause discomfort through the procedure. Hiccup may also lead to ventilation problems according to its increasing level. There are some published literatures on the use of TIVA consisting Propofol that induced hiccup. Curiously, drug-induced hiccups are reported more commonly in men than women, alike our case. We believe with our case that hiccups develop because of multifactorial etiology not just one.

Keywords: HICCUP, TYMPANOPLASTY SURGERY

Pub No: S-042

Awake Intubation Experience in a Patient with Cervical Fracture Secondary to Trauma

Ahmet Furkan GÜREL[1], Said Sencer GÜNEY[1], Alper KEPENEK[1], Meryem GÜREL[1], Mehmet ÇAKIRCA[1], Hülya BAŞAR[1]

[1]Ankara Eğitim ve Araştırma Hastanesi Anesteziyoloji ve Reanimasyon Kliniği

INTRODUCTION - PURPOSE: Cervical spine trauma encompasses a wide variety of injuries,from minor muscle strains to life-threatening fracture-dislocations associated with spinal cord lesions.Endotracheal intubation for anesthesia carries significant risk in patients with cervical spine fractures(1).Awake tracheal intubation involves inserting a tracheal tube into an awake,spontaneously breathing patient,usually with flexible bronchoscopy or videolaryngoscopy.In this case,awake intubation management in a patient with cervical spine fracture is presented.

CASE: An operation was planned for a 24-year-old female patient with cervical fracture.ECG,NIBP,SpO2 were monitored.Preoxygenation was performed with a mask with 100%oxygen at 6lt/min for 3minutes.At the same time,1mg of midazolam was administered to the patient as ananxiolytic.Remifentanil infusion was started at 0.1mcg/kg/min as a sedative.With the patient following the commands,mouth opening was achieved,and 20puffs of 10%lidocaine were applied.Under spontaneous respiration,after 2-minute infusion patient was successfully intubated with spiral-cuffed tube(7.5) with videolaryngoscope within 15 seconds.

DISCUSSION - CONCLUSION: Severe limitation of head and neck movements may make direct laryngoscopy and tracheal intubation difficult or impossible.It is suggested that the most ideal method to ensure airway safety in such patients is awake fiberoptic intubation with mild sedation and no muscle relaxation(2).Wang et al.(3) reported that in patients with various anatomical and anthropometric limitations for whom difficult laryngoscopy and difficult intubation are predicted,awake videolaryngoscopy is a method that should be kept in mind.A dose of 0.1mcq/kg/min remifentanil combined with midazolam provides success in patients who will be intubated while awake(4).With the prediction of a difficult airway,we provided sedation and analgesia with the combination of midazolam-remifentanil in the patient who was intubated while awake with videolaryngoscopy.In cases where difficult airway and difficult laryngoscopy are expected,the use of awake intubation and videolaryngoscopy should be considered where access to fiberoptic bronchoscopy is limited or as an alternative to fiberoptic bronchoscopy.The need to increase clinical experience by conducting more studies on this subject should also be discussed.

Keywords: Awake tracheal intubation, Cervical spine trauma, Difficult airway management, Videolaryngoscopy

SAĞLIK BİLİMLERİ ÜNİVERSİTESİ

II. ULUSLARARASI katılımlı Anesteziyoloji ve Reanimasyon Sempozyumu

SAĞLIK BİLİMLERİ ÜNİVERSİTESİ
GÜLHANE EĞİTİM VE ARAŞTIRMA HASTANESİ
KONGRE MERKEZİ

ANKARA
2-3 ARALIK 2022

ÇEVRİMİÇİ SÖZLÜ BİLDİRİLER

Pub No: O-001

Does Procalcitonin Indicate Myocardial Damage in Patients with Elevated Troponin T in Severe COVID-19 Disease?

Hilal SIPAHIOGLU[1]

[1]Kayseri City Training and Research Hospital

INTRODUCTION - PURPOSE: Coronavirus Disease 2019 (COVID-19) has quickly progressed to a global health emergency. Hypertension, arrhythmia, cardiomyopathy and coronary heart disease are amongst major cardiovascular disease comorbidities seen in severe cases of COVID-19. Elevated troponin T in patients with COVID-19 indicates myocardial damage. Our aim in this study is to investigate the relationship between procalcitonin level and myocardial damage in patients with elevated troponin T.

MATERIALS AND METHODS: Six hundred and thirty-five patients hospitalized with severe COVID-19 disease were admitted to the tertiary intensive care unit between August 2020 and September 2021. 102 patients did not have troponin T value on the day of hospitalization in the intensive care unit, and 13 patients were diagnosed with acute myocardial infarction. Demographic data, laboratory and clinical findings of a total of 305 patients were recorded.

RESULTS: Three hundred and five patients with severe Covid 19 disease were divided into normal (n:228) and elevated troponin (n:77) groups according to the hospitalization troponin T value being four times greater than the normal threshold value. The mean age of the patients was 64±12 years, and the mean age was greater in the troponin-elevated group than in the normal group ($p<0.001$). While the procalcitonin value was higher in the troponin high group ($p<0.001$) compared to the normal group, CRP, another indicator of inflammation, was similar between the two groups ($p=0.805$). Factors affecting troponin elevation in univariate analysis were age ($p<0.001$), BUN ($p<0.001$), creatine (<0.001), albumin ($p=0.008$), procalcitonin (<0.001), CKMB ($p=0.02$). In multivariate analysis, age (OR =1.073, 95% CI=1.024-1.125) and procalcitonin (O.R: 1.001, 95% CI=1.011-2.199) were affecting troponin elevation.

Baseline characteristics of the 305 patients

Variables	**Patients (n:305)**
Age	64±12
Gender male n(%)	177(58)
BMI(kg/m$^{2)}$ mean±SD	26.9 ±4.5
Diabetes n(%)	87(28.5)
Hypertension n(%)	142(46.6)
Heart Disease n(%)	66(21.6)

Asthma n(%)	18(5.9)
Chronic Respiratory Disease n(%)	24(7.9)
Chronic Respiratory disease n(%)	14(4.6)
SOFA mean±SD	3.7 ±1.5
GCS mean±SD	13.8 ±2.8
APACHE II mean±SD	16 ±5.5
Respiratory rate/min	33±6.7
Systolic blood pressure mm/Hg mean±SD	119±24.2
Diastolic blood pressure mm/Hg mean±SD	71 ±17.7
HR /min mean±SD	111.9± 21.1
Mechanical ventilator requirement n (%)	241(79)
Vasopressor requirement n(%)	153(50.2)
Number of days in hospital, day, mean ±SD	20.1 ±12
Number of intensive care days mean ±SD	15.1 ±9.6
Mortality n(%)	183(60)

Table 2. Comparison of the properties of the elevated troponin T and normal troponin T groups

	Overall n:305	**Normal troponin T n:228**	**Elevated troponin T n:77**	**p**
Age year ±SD	64±12	62±12	69±11	**<0.001**
BMI	26.9±4,5	26.98±4.5	26±4.7	0.941
BUN mg/dL	26(18-38)	24(16-32)	34(29-41)	**0.03**
Creatinine mg/dL	0.9(0,7-1,4)	0.8(0,6-1.1)	1.2(0.9-1.5)	**0.04**
AST U/L	36(24-55)	36(24-53)	38(25-65)	0.168
ALT U/L	28(18-45)	29(19-47)	25(16-40)	0.161
Lactate Dehydrogenase U/L	501(387-680)	514(407-695)	457(335-601)	0.310
Ca mg/dL	8.3±0.66	8.39±0.66	8.35±0.61	0.909
Lactate mmol/L	2.4±1,2	2±1	3±2	0.063

Albumin g/L	3.27±0,45	3.31±0.42	3.2(2.8-3.5)	**0.025**
Bilirubin mg/dL	0.5(0.3-0.7)	0.5(0.4-0.7)	0.4(0.3-0.8)	0.168
CRP mg/L	106(58-182)	101(56-167)	133(64-204)	0.805
Procalcitonin ng/ml	0.23(0.1-0.9)	0.16(0.08-0.45)	0.94(0.36-2.4)	**<0.001**
Ferritin µg/L	876(424-1564)	882(478-1523)	832(320-1862)	**0.030**
Fibrinogen mg/L	6433±1811	6472±1785	6319±1893	0,272
D-dimer µg/L	1212(619-2379)	1126(568-2110)	1594(920-2907)	**0,003**
WBC 10^3/µL	10840(7885-14980)	10840(8112-14937)	10820(7085-15587)	0,731
Neutrophil 10^3/µL	9520(6580-13535)	9620(709-13605)	9190(5530-13465)	0,246
Lymphocyte 10^3/µL	700(485-1050)	660(480-970)	870(520-1305)	**0,008**
Eosinophil 10^3/µL	0(0-10)	0(0-10)	10(0-30)	**<0.001**
Platelet 10^3/µL	235000±95000	241444±95089	217844±93731	0,06
CK U/L	94(50-209)	90(51-177)	120(49-282)	0,09
CK-MB U/L	32(27-52)	31(29-50)	39(28-87)	**<0.001**

ALT; alanine aminotransferase, AST; aspartate aminotransferase, BUN; blood urea nitrogen, CK; creatine kinase, CRP; C-reactive protein, INR; international normalized ratio, WBC; white blood cell count

Univariate and multivariate analysis of baseline risk factors for Elevated troponin T

	Univariate OR (%95 CI)	P	Multivariate OR (%95 CI)	p
Age	1.060(1.034-1.087)	**<0.001**	1.073(1.024-1.125)	**0.004**
Gender	1.393(0.828-2.342)	0.212		
BMI	0.999(0.944-1.054)	0.982		
BUN	1.045(1.030-1.060)	**<0.001**	1.019(0,993-1.046)	0.200
Creatin	2.020(1.474-2.790)	**<0.001**	1.567(0.997-2.465)	0.052
Albumin	0.924(0.871-0.980)	**0.008**	0.950(0.876-1.030)	0.216
Procalsitonin	1.085(1.018-1.156)	**<0.001**	1.001(1.011-2.199)	**0.001**
Ferritin	1.000(1.000-1.000)	0.213		
D-Dimer	1.000(1.000-1.002)	0.065		
Lymphocyte	1.000(1.000-1.001)	0.057		
Eosinophils	1.003(0.995-1.006)	0.141		
Ck-Mb	1.011(1.001-1.020)	**0.02**	0.997(0.979-1.006)	0.398

CI: confidence interval; OR: odds ratio;

DISCUSSION - CONCLUSION: In conclusion, troponin T elevation, an indicator of myocardial damage in COVID-19 patients, is affected independently by age and procalcitonin. Therefore, in the presence of high troponin T and procalcitonin, myocardial damage should be evaluated with a careful ECG and echocardiography.

Keywords: COVID-19, troponin T, procalcitonin, myocardial damage, CRP

Pub No: O-003

Species Distribution and Antimicrobial Susceptibilities of Gram-Negative Bacteria Isolated from Blood Cultures of Patients In ICU

Neslihan ARICI[1]

[1]University of Health Sciences, Haydarpaşa Numune Research and Training Hospital, Medical Microbiology, Istanbul

INTRODUCTION - PURPOSE: Gram-negative bacteremia in critically ill patients is associated with significant morbidity and mortality. The aim of this study was to determine the species distribution and antimicrobial susceptibilities of gram-negative bacteria most commonly isolated from blood cultures of hospitalized patients in a general intensive care unit (ICU) over a three-year period.

MATERIALS AND METHODS: Blood cultures with growth of gram negative bacteria from 01.01.2020 to 31.10.2022 were included in the study. Blood cultures were performed using a fully automated blood culture device, BacT/Alert® (bioMérieux, France). The identification of the isolated microorganisms was done using MALDI-TOF, VITEK-MS (bioMérieux,). The VITEK 2 automated system was used to determine antibiotic susceptibility. Colistin resistance was also confirmed by broth microdilution, and carbapenem resistance was confirmed by the gradient diffusion method. Results were evaluated according to the criteria of the European Committee on Antimicrobial Susceptibility Testing (EUCAST).

RESULTS: Overall (n=721), the most frequently isolated gram-negative bacteria were {Klebsiella pneumoniae} (40.2%), {Acinetobacter baumannii} (28.2%),{Pseudomonas aeruginosa} (17.4%), and {Escherichia coli} (14%)(Fig-1). Generally, carbapenem and colistin resistance were found in 49.3% and 10.2% of {K.pneumoniae} isolates, respectively. {A.baumanni} presented the highest resistance to most antibiotics except colistin (0%) and tigecycline (2.3%). A significant increase in ceftazidime, amikacin and piperacillin-tazobactam resistance (25-92.3%, 3.6-73%, 21.5- 77%, respectively) was detected for {P.aeruginosa} isolates. ESBL positivity (44-55%) remained stable in {E.coli} strains within three years (Table-1).

.

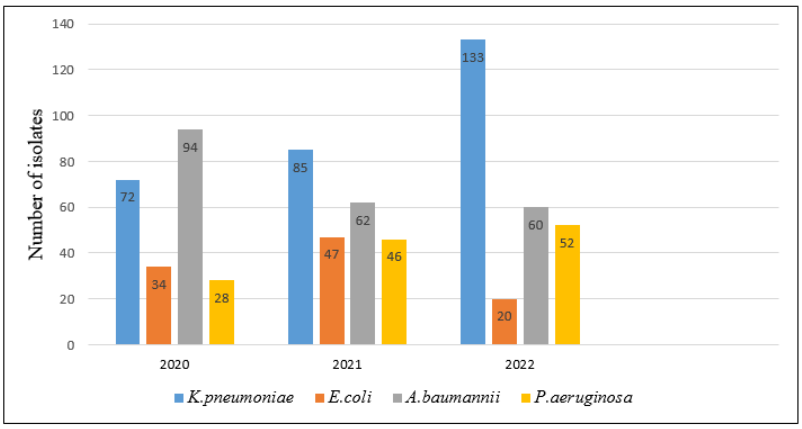

Fig-1. Species distribution of microorganisms over the years

.

Table-1. Resistance rates of gram negative bacteria isolated from blood cultures to commonly used antibiotics

	2020				2021				2022			
	K.pneu (n:72)	*E. coli* (n:34)	*A.bau* (n:82)	*PSA* (n:28)	*K.pneu* (n:85)	*E. coli* (n:47)	*A.bau* (n:62)	*PSA* (n:46)	*K.pneu* (n:133)	*E. coli* (n:20)	*A.bau* (n:60)	*PSA* (n:52)
Amikacin	27.8%	5.9%	94%	3.6%	41.2%	2.1%	78%	19.6%	75.2%	0%	78.4%	73%
Ceftriaxone	75%	44.1%	-	-	75.3%	49%	-	-	87.2%	55%	-	-
Ceftazidime	75%	44.1%	-	21.5%	72%	48%	-	45.7%	76.4%	55%	-	77%
Ciprofloxacin	66.7%	44.1%	-	14.3%	64.7%	55.4%	-	28.3%	82%	50%	-	54%
Colistin	5.6%	0%	0%	0%	10%	0%	33%	0%	15%	0%	0%	2%
Meropenem	48.6%	0%	100%	21.5%	48.6%	0%	90%	30.5%	54.2%	0%	95%	82.7%
Piperacillin-Tazobactam	73.6%	32.4%	-	25%	73.6%	19.2%	-	47.9%	36.9%	15%	-	92.3%
Tigecycline	-	-	1.3%	-	-	-	3.3%	-	-	-	0%	-

K.pneu: K. pneumoniae, E.coli: Escherichia coli, A.bau: Acinetobacter baumannii, PSA: Pseudomonas aeruginosa

DISCUSSION - CONCLUSION: Considering the distribution of microorganisms, it is noteworthy that {K.pneumoniae} increased over time. Besides, the high antibiotic resistance found in our study is alarming. Increased resistance to last-line antibiotics carbapenem and colistin in {K.pneumoniae}, and piperacillin-tazobactam resistance in {P.aeruginosa} indicates that the treatment of gram-negative sepsis will become more difficult for ICU-patients. Therefore, the rational use of antibiotics based on updated information on common organisms in ICU and their antibiotic susceptibility patterns is essential for effective treatment.

Keywords: antibiotic resistance, blood culture, sepsis, ICU

Pub No: O-004

Needle Tip Type And Nerve Injury Relation in Peripheral Nerve Blockade; Experimental Animal Study

Cevdet YARDIMCI[1], Hüseyin YILDIZ[2], Emin SİLAY[3], Hamide SAYAR[4], Ergül BELGE KURUTAŞ[5], İsmail COŞKUNER[6], Nimet ŞENOĞLU[7], Davut ÖZBAĞ[8], Yalçın KARAGÖZ[9], Cengiz YAVUZ[5]

[1]Medical Faculty of Yozgat Bozok University
[2]Private Medical Park Gaziantep Hospital
[3]Kayseri City Hospital
[4]Medical Faculty of Mersin University
[5]Medical Faculty of Kahramanmaraş Sutcu Imam University
[6]Private Ipekyolu Hospital
[7]Medical Faculty of Bakırcay University
[8]Medical Faculty of Inonu University
[9]Medical Faculty of Sıvas Cumhuriyet University

INTRODUCTION - PURPOSE: Nerve injuries due to peripheral nerve blocks may be caused by traumatic, vascular , and chemical(1). We aimed to evaluate the injury and needle type relationship.

MATERIALS AND METHODS: Ethical approval was obtained. Five groups containing 6 rats each were formed; Group1(Control), Group2(25G Sharp), Group3(25G Blunt), Group4(27G Sharp), Group5(27G Blunt) groups. After the anesthesia application, the sciatic nerve was explored and the needles were fully passed through (Figure 1). After 48 hours, samples were taken. X2, Kruskall Wallis and Mann Whitney U tests were used in the analysis of biochemical and the histopathological results ($p<0.05$ significance).

Experimental Needle Nerve Contact

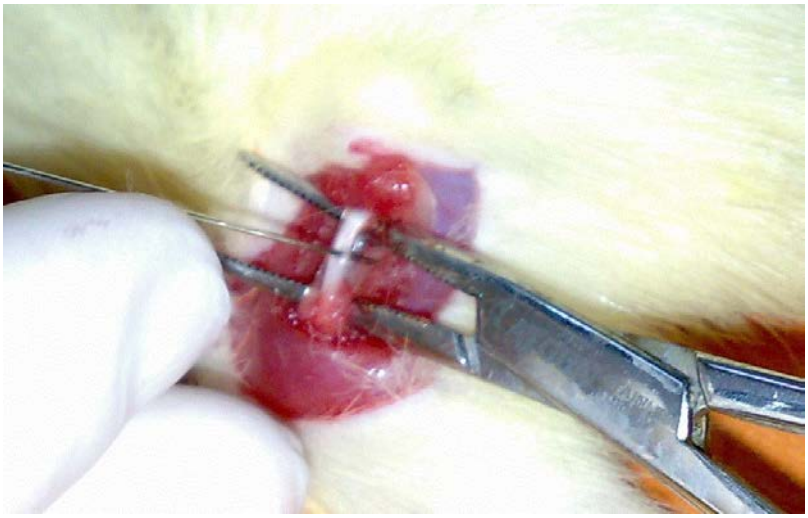

After the sciatic nerve was explored under anesthesia, the needle was passed through the sciatic nerves in full thickness. After application, the wound was properly closed accouding to anatomical structures. After 48 hours, the surgery sides were reopened under anesthesia and sciatic nerve samples were harvested.

RESULTS: In the biochemical analysis, statistically significant difference was observed between MDA and SOD values ($p<0.05$), no difference was observed in CAT values (Table 1) ($P>0.05$). In the PostHoc analysis, MDA levels in Group3 and Group5 was statistically higher than other groups ($P<0.05$).Nerve injjury scores, congestion degree, hemorrhage, and inflammatory cells were statistically increased in the Group 5 and Group2 than other groups (Table 2) ($P< 0.05$).

Comparison of Biochemical results

		Groups					
		Group1	**Gorup2**	**Group3**	**Group4**	**Group 5**	**P**
MDA (nmol/mg_prt)	Mean±SD	2,72±0,48	2,99±0,57	4,59±0.79	2,73±0,66	3,83±0,72	,001
SOD (U/mg_prt)	Mean±SD	2,15±0,48	4,06±0,78	4,92±1,52	4,69±0,45	4,22±0,79	,004
CAT (U/mg_prt)	Mean±SD	3,34±1,95	2,57±1.12	4,12±1,65	5,75±2,71	4,87±2,69	,110

Kruskal Wallis and Man-Whitney U tests were used in the analysis. There was difference between groups according to MDA and SOD levels. In the posthoc analysis, MDA levels in Group3 and Group5 were higher from other Groups ($P<0,05$), SOD levels in Group2, Group3 and Group5 were higher than other groups.

Comparison of Histopathologic Results

	GROUPS					
	Group1 (Mean±SD)	**Group2 (Mean±SD)**	**Group3 (Mean±SD)**	**Group4 (Mean±SD)**	**Group5 (Mean±SD)**	**P**
Nerve Injury Scoring	1,29±0,49	2,57±0,65	1,00±0,00	1,29±0,49	4,78±0,80	0,000
Congestion	1,00±0,00	1,79±0,43	1,00±0,00	1,57±0,53	1,44±0,51	0,002
Hemorrhage	1,00±0,00	1,36±0,50	1,00±0,00	1,14±0,38	1,15±0,53	0,027
Inflammation Cells	4,43±5,86	19,71±10,25	6,00±12,25	8,14±9,06	32,48±13,40	0,000

Non-parametric Chi-square, Kruskal Wallis and Mann Whitney U tests were used in the analysis. In further evaluation; nerve injjury scores, congestion degree, hemorrhage, and inflammatory cells were statistically increased in the Group 5 and Group2 than other groups ($p<0,05$).

DISCUSSION - CONCLUSION: Needle-nerve contact is still possible even in ultrasound guidance (2). Selander et al., stated that short-bevelled needles caused less harm than long ones(3). Steinfeld et al. reported no difference between the injury with 24G Pencilpoint and 24G short bevelled needle (4). However, they did not evaluate relation of the needle diameter and injury relationship. In this study, the severity of the damage seems to increase as the diameter of the needle decreases when it is blunt (for 25G and 27G needles) and as the diameter increases when it is sharp. This may be due to the use of more force during blunt needle usage. In choosing needle type between 25G and 27G in peripheral nerve blockade and subarachoidal spinal block, blunt needle in 25G and sharp needle in 27G will be less harmful if the needle get contact to nerve involuntarily.

Keywords: Needle Type, Nerve Injury, Blunt Tipped Needle, Sharp Tipped Needle, Peripheral Nerve Block

Pub No: O-005

Comparison of ultrasound-guided costoclavicular and lateral sagittal infraclavicular block characteristics with perfusion index

Büşra Ceran Serçe[1], Derya Arslan Yurtlu[1]

[1]İzmir Katip Çelebi University Hospital

INTRODUCTION - PURPOSE: The aim of this study was to compare the characteristics of costoclavicular and lateral sagittal infraclavicular blocks applied in upper extremity surgery, accompanied by the perfusion index.

MATERIALS AND METHODS: This study was planned as prospective and observational. After the approval of the ethics committee, >18 years old, ASA 1-3 patients who were planned for elective or emergency hand, wrist and forearm surgery were included in the study. The patients were divided into two groups as the costoclavicular approach(Group CC) and the lateral sagittal infraclavicular approach(Group LS). Both groups were administered 15 ml of 0.5% bupivacaine and 15 ml of 2% lidocaine during the procedure. After the application, the sensory block levels of the extremity were evaluated by verbal rating beard (VRS), motor block levels were evaluated with the Bromage scale (BS), and the Perfusion Index (PI) values were evaluated every 5 minutes for the first 30 minutes. Block levels in both groups were compared with PI.

RESULTS: The study included 46 patients in Group CC and 50 patients in Group LS Sensory block at 1st, 5th, 10th and 15th minutes, motor block at 1st, 5th, 10th, 15th, 20th, and 25th minutes were significantly higher in Group CC. When the change in perfusion index over time was compared between the two groups, it was significantly higher in Group CC at the 5th and 10th minutes. While the time to complete block was 11.41 ±6.38 min in Group CC, it was 17.8 ±7.22 min in Group LS ($p<0.05$).

DISCUSSION - CONCLUSION: In infraclavicular brachial plexus block, the costoclavicular approach was compared with the lateral sagittal approach in terms of block onset times, and it was concluded that both sensory and motor block started earlier in the costoclavicular approach. Perfusion index, on the other hand, supported this result as an objective parameter.

Keywords: Infraclavicular block, costoclavicular approach, lateral sagittal approach, perfusion index

Pub No: O-006

Effect of Ultrasound Guided Neuroaxial Anesthesia on Anesthesia Performance

Berna ÇALIŞKAN[1], Öznur ŞEN[1]

[1]Department of Anesthesiology and Reanimation, Haseki Training and Research Hospital, İstanbul, Turkey

INTRODUCTION - PURPOSE: Traditionaly neuroaxial anesthesia procedures based on blind techniques to identify correct intervertebral level with palpation and sensation of loss of resistance in attempts of epidural anesthesia. However, landmark based palpation can be inaccurate depending on the experience of the anesthesiologist(1). Moreover factors like obesity, anatomical deformities of vertebra and more can result in challenges in this traditional technique(2). In result of this we intend to present effects of our preprocedural ultrasonography (USG) examinations of lumbar vertebra before combined spinal epidural procedures of anesthesia management for the knee arthroplasty.

MATERIALS AND METHODS: After ethical approval of our institution, we selected patients eligible for combined spinal epidural anesthesia procedure. An experienced anesthesia specialist applied all USG examinations at the sitting position. Before sterilization we drew lines marking the L3-4 intervertebral area, midline and measured the distance from the skin to the posterior complex to assume the depth of epidural space. After standart monitorization we started attempt of traditional aseptic techniques of neuroaxial anesthesia. Single needle success, number of attempts, number of needle redirecting, duration of procedure, distance measured by USG, distance concluded, gap between distances, complications and side effect were recorded.

RESULTS: There was significant correlation between distance measured by USG and distance concluded (correlation coefficient 0.950; p 0.001). There were no significant correlations between body mass index (BMI) and number of attempts, number of needle redirecting (p 0.806; 0.247, duration of procedure.

Table 1

Number of patients	18
Age (years)*	56.6±14.5
BMI (kg/m2)*	31.1±7.3
Sex	
Male	3 (16.7%)
Female	15 (83.3%)
ASA score	
ASA 1	4 (22.2%)
ASA 2	14 (77.8%)
Single needle success	11 (61.1%)
Number of attempts *	1.7±1.1
Number of needle redirecting *	1.1±1.2
Duration of procedure *	4.3±3.5
Distance measured by USG *	5.4±1.1
Distance concluded *	5.7±1.3
Gap between distances *	0.4±0.4
Complications and side effect	-

* mean±standard deviation, USG: ultrasonography, BMI: body mass index, ASA: American Society of Anesthesiologists

Table 2

	Correlation Coefficient	P value
Distance measured by USG / Distance concluded	0.950	0.001
BMI / Number of attempts	0.062	0.806
BMI / Number of needle redirecting	0.287	0.247
BMI- Distance measured by USG	0.450	0.061
BMI / Distance concluded	0.570	0.014

USG: ultrasonography, BMI: body mass index

DISCUSSION - CONCLUSION: USG guidance for neuroaxial anesthesia could provide correct locations for the procedure and minimize needle attempts(3). USG guided measurement to epidural space can maintain a safety belt especially for the unexperienced residences who can not perfectly discriminate loss of resistence during learning process. Traditional landmark based technique may get harder with increase of BMI however with USG guidance it would not effect the procedure(4).

Keywords: neuroaxial anesthesia, ultrasound guidance, total knee arthroplasty, combined spinal epidural anesthesia

Pub No: O-007

Comparison Of Effects On Sedation And Parent Separation Of Intranasal And Oral Midazolamine Applied For The Premedication Of Pediatric Patients

DİLEK METİN YAMAÇ[1], Hidayet Nedret ERGÜVEN[2]

[1]Sultan 2. Abdulhamid Han Training and Research Hospital
[2]S.B.Ü. Haseki Training and Research Hospital

INTRODUCTION - PURPOSE: The aim of this study is to compare the effects of intranasal and oral midazolam administered for premedication on hemodynamic parameters, sedation and separation from parents in preschool children.

MATERIALS AND METHODS: In this prospective, randomized, single-blind study, a total of 60 patients aged 2-6 years who would undergo elective surgery under general anesthesia were included in the study after the approval of the hospital ethics committee. The patients were divided into two equal groups using the closed-envelope method and 0.5 mg/kg oral midazolam was administered to one group (Group O, n=30), and 0.25 mg/kg intranasal midazolam (Group N, n=30) to the other group, 20 minutes before the operation. Vital signs and sedation score level were recorded every five minutes. At the end of the 20th minute, the parental separation score was evaluated and recorded.

RESULTS: There was no statistically significant difference between the two groups in terms of age, gender, height and weight averages. Also, there was no significant difference between the heart rate and noninvasive arterial pressure values measured every 5 minutes. Differential nasal irritation was detected in 11/30 (36%) patients in Group N. The sedation score values of both groups at the 10th minute were found to be significantly higher than the initial values. No statistical difference was observed between other values. No statistically significant difference was observed between Group N and Group O's mean separation scores at the 20th minute. ($p>0.05$)

INTERGROUP SEDATİON SCALE

SEDATION SCALE	GROUP N	GROUP O	*p*
5. MİN	1,47-0,51	1,47-0,51	1,000
10. MİN	2,23-0,43	2,07-0,25	0,073
15. MİN	2,83-0,46	2,73-0,45	0,039
20. MİN	3,23-0,50	3,20-0,48	0,795

Intergroup parental separation scale

	GROUP N (-SD)	GROUP O (-SD)	*p*
Parental Separation Scale Score	1,55-(0,63)	1,47-(0,63)	0,606

DISCUSSION - CONCLUSION: In our study; It has been determined that 0.25 mg/kg intranasal or 0.5 mg/kg oral midazolam administered for premedication in children aged 2-6 is an effective method, and there is no significant difference between the two applications in terms of sedation and separation from parents. Oral midazolam was considered to be a more preferable method due to nasal congestion in patients who underwent nasal administration.

Keywords: preanesthetic sedation, intranasal midazolam, Children, oral

Pub No: O-008

In A Pseudotrombocytopenic Pregnancy: Regional? General?

Şükran İÇÖZ[1], İlker COŞKUN[1]

[1]Ordu University, Faculty of Medicine, Department of Anesthesiology and Reanimation, ORDU

INTRODUCTION - PURPOSE: Thrombocytopenia is the thrombocyte count below 150,000/µL(1).Gestational thrombocytopenia, ITP, pseudothrombocytopenia, obstetric diseases are its causes in pregnancy(Table 1).Those that do not require treatment, such as pseudothrombocytopenia, should be well differentiated. In this presentation, perioperative anesthesia management of a pseudothrombocytopenic pregnant who will have a cesarean section will be discussed.

Table 1. Causes of thrombocytopenia in pregnancy (in order of decreasing frequency)

Gestational thrombocytopenia.
Immune thrombocytopenia (Idiopathic, SLE, drugs, HIV infection).
pseudothrombocytopenia.
Diseases of pregnancy (preeclampsia, eclampsia, HELLP syndrome, acute fatty liver).
Drugs (aspirin, acetaminophen, ampicillin, digitalis, heparin, methyldopa, cyclosporine..).
Connective tissue diseases (SLE, antiphospholipid syndrome).
TTP (Thrombotic thrombocytopenic purpura) (Acquired, hereditary).
HUS (Hemolytic Uremic Syndrome).
DIC (Disseminated intravascular coagulation).
Hereditary platelet diseases.
Bone marrow diseases.
Viral infections, bacterial sepsis.
Hypersplenism.
Alcoholism, malnutrition, B12 and folate deficiencies.

CASE: A 28-year-old pregnant with no history of additional disease was admitted for elective cesarean section. In her previous pregnancy;It was learned that she was diagnosed with pseudothrombocytopenia and she was operated under general anesthesia.Preoperative blood tests were normal except for PLT:25,000/µL.No signs of bleeding were found.A control hemogram was run in a tube with EDTA and Na-citrate on the morning of the operation(Table 2).She was taken to cesarean section under general anaesthesia.There was no intraoperative bleeding, no transfusion was required.

Table 2. Comparison of the patient's hemogram and peripheral smear results

	Preoperative - 1 months ago	Preoperative-15 days ago (tube with EDTA)	Preoperative morning (tube with EDTA)	Preoperative morning (tube with Na-citrate)
PLT (µL)		25.000	32.000	141.000
MPV (fL)		9.7	9.9	11.7
PDW (fL)		10.1	10.4	12.1
HGB (dL)		11.4	11.2	11.7
WBC (µL)		12.900	12.300	12.000
periph. platelet on smear (sample with EDTA)	there is a cluster			
periph. platelet in smear (citrate sample)	no clustering			

DISCUSSION - CONCLUSION: Pseudothrombocytopenia is a low count of platelets as a result of in vitro aggregation(2). It is most commonly caused by tubes containing EDTA(3).It has no clinical significance, does not increase the risk of bleeding(4).It is confused with true thrombocytopenias, first of all, pseudothrombocytopenia should be excluded.Failure to recognize;may result in inappropriate platelet transfusion, unnecessary additional testing, and avoidance of neuraxial anesthesia.The thrombocyte count is an easy method to repeat using a citrated tubed blood sample.The presence of thrombocyte aggregation on peripheral smear is the gold standard for diagnosis.Neuraxial anesthesia is the gold standard in cesarean sections(5). Depending on the severity of thrombocytopenia, neuraxial techniques may be contraindicated due to the risk of spinal epidural hematoma(6).The acceptable threshold for neuraxial techniques differs among clinicians(7).While making an anesthesia plan;recognition of pseudothrombocytopenia is very important, especially for pregnant who will benefit from neuraxial anesthesia.While deciding on the platelet count required for safe neuraxial anesthesia, the rate of platelet decline, the risks associated with general anesthesia,the clinical picture,and patient factors should be considered.

Keywords: Anesthesıa Management, Pregnancy, Pseudotrombocytopenıa

Pub No: O-009

Comparison of Epidural Bupivacaine and Bupivacaine+Prilocaine Combination in Labour Analgesia

Zehra BİNGÖL[1], İlker COŞKUN[1], Ebru ÇANAKÇI[1], Tuba ÇATAK[1], Zübeyir CEBECİ[1]

[1]Ordu University, Faculty of Medicine, Department of Anesthesiology and Reanimation, Ordu

INTRODUCTION - PURPOSE: Our aim in this study is to compare the effects of epidural bupivacaine and bupivacaine+prilocaine combination on analgesia quality and delivery conditions.

MATERIALS AND METHODS: Our study was conducted on 40 primigravid pregnant on September 1-December 31, 2019. Pregnant women at 36-42 weeks of age,with vertex presentation,cervix opening of 3-4cm were included in the study and the pregnant were randomly divided into two groups. An epidural catheter was inserted through a 20GTouhy needle. Bupivacaine group (Group B,n=20)and Bupivacaine+Prilocaine group (Group BP,n=20)were included in the study.Adjuvant Fentanyl was added to Group B as 0.25% Bupivacaine 10cc and 10mcg per cc Fentanyl.10cc volume (5cc bupivacaine, 2cc fentanyl, 3cc SF) was transfused through the epidural catheter.In addition to bupivacaine,prilocaine was added to the pregnant in Group BP and adjuvant Fentanyl was added as 10mcg per cc. 10cc volume (3cc Prilocaine,2cc Bupivacaine, 2cc Fentanyl, 3cc SF)was transfused through the epidural catheter. Sensory blocks,hemodynamics,and VAS scores were monitored at intervals of one hour latest. When VAS values were 4-5; 10cc intermittent bolus was planned through epidural catheters. After the catheter was inserted,the VAS value recorded at the first bolus dose was considered as the first VAS,and the VAS value recorded at the second bolus dose was accepted as the second VAS Further bolus doses,were performed when the VAS score was 4 or higher.

RESULTS: The median value of the first VAS was obtained as 5 in both groups,but the VAS values were lower in the bupivacaine+prilocaine group(p=0.022).Though the median value of the second VAS was lower in the pure bupivacaine group,the hatch VAS values were lower in the combined pilocaine+bupivacaine group (p=0.016). Comparisons of quantitative data by groups are presented in Table 1

Table 1: Comparisons of quantitative data according to the groups

	Group B	Group BP	p
Maternal age**	27.0 ± 7.0	26.6 ± 4.9	0.196
Maternal weight**	79.7 ± 9.6	78.8 ± 11.2	0.422
Maternal height**	161.7 ± 5.0	162.6 ± 4.3	0.696
First VAS*	5(2-7)	5(2-7)	0.022
Second VAS*	0(0-7)	2(1-3)	0.020
Vaginal exit VAS*	2(0-4)	0(0-1)	0.016

*Mann Whitney U test, **Independent samples t test, VAS: Visual Analog Scale

DISCUSSION - CONCLUSION: Bupivacaine+prilocaine combination may be a good choice for epidural analgesia.

Keywords: Epidural labour analgesia, Bupivacaine, Prilocaine, VAS

Pub No: O-012

Determination of the Relationship between Frail Frailty Index, ASA Scoring, Neutrophil-Lymphocyte Ratio and Erythrocyte Distribution Width and Mortality and Morbidity in Geriatric Patients

Ayşe Gül PARLAK ÇIKRIKCI[1], Mehtap HONCA[2], Ahmet YÜKSEK[3]

[1]yozgat Bozok Üniversitesi Araştirma Ve Uygulama Hastanesi
[2]ankara Şehir Hastanesi
[3]sağlik Bilimleri Üniversitesi Derince Eğitim Araştirma Hastanesi

INTRODUCTION - PURPOSE: The increase in the geriatric population in the world causes an increase in the number of geriatric surgeries. Clinicians should be more careful in the follow-up of the elderly patient group due to the physiological changes that occur with age. Our aim in this study is to determine the predictive power of Frail index, ASA scoring and hemogram findings to be applied to the patient in the preoperative period on postoperative mortality and morbidity.

MATERIALS AND METHODS: This prospective study was conducted with geriatric patients scheduled for elective surgery at Bozok University Research and Application Hospital between 01.05.2020 and 31.12.2021. The fragility index was applied to the patients in the preoperative period and their ASA scores were determined. Preoperative and postoperative hemogram data of the patients were recorded.

RESULTS: In the study, which included a total of 167 patients, 33.5% of the patients were female and 66.5% were male. The mean age of the patients was 74.6±8.01. When we classified patients according to the frailty index, 39.5% patients were evaluated as normal, 37.7% patients as prefrail, and 22.8% patients as frail. When we classified patients according to ASA scores, we did not have any patients in the ASA I group, while 29.9% patients were ASA II ; 50.3% patients were ASA III; 19.8% patients were found in ASA IV group. When all groups were evaluated in terms of postoperative three-month mortality and morbidity, Frail index, ASA, preoperative NLR, postoperative NLR, preoperative RDW-SD and postoperative RDW-SD were found to be the most effective parameters in predicting mortality and morbidity ($p<0.0001$, $p<0.0001$, $p<0.0001$, $p=0.002$, $p<0.0001$, respectively).

Relationship of FRAIL, ASA and hemogram parameters with postoperative third month status

		Postoperatif 3. ay durumu	FRAİL	ASA	Preoperatif NLO	Postoper NLO
Pearson Correlation	Postoperatif 3. ay durumu	1	-0,42	-0,391	-0,367	-0
	FRAIL	-0,42	1	0,458	0,334	0
	ASA	-0,391	0,458	1	0,35	0
	Preoperatif NLO	-0,367	0,334	0,35	1	0
	Postoperatif NLO	-0,255	0,184	0,421	0,389	
	Preoperatif RDW-SD	-0,223	0,309	0,242	0,255	0
	Postoperatif RDW-SD	-0,255	0,355	0,349	0,258	0
Sig. (1-tailed)	Postoperatif 3. ay durumu	.	0	0	0	
	FRAIL	0	.	0	0	0
	ASA	0	0	.	0	
	Preoperatif NLO	0	0	0	.	
	Postoperatif NLO	0	0,009	0	0	
	Preoperatif RDW-SD	0,002	0	0,001	0	0
	Postoperatif RDW-SD	0	0	0	0	0
N	Postoperatif 3. ay durumu	167	167	167	167	
	FRAIL	167	167	167	167	
	ASA	167	167	167	167	
	Preoperatif NLO	167	167	167	167	
	Postoperatif NLO	167	167	167	167	
	Preoperatif RDW-SD	167	167	167	167	
	Postoperatif RDW-SD	167	167	167	167	

DISCUSSION - CONCLUSION: Our study shows that preoperative combined evaluation of ASA scoring, Frail frailty index, NLR and RDW of the geriatric patients will have a higher prediction of mortality and morbidity in the postoperative three-month period follow up.

Keywords: preoperative, ASA, frail, NLR, RDW

Pub No: O-013

Preeclampsia And Pres Syndrome In Patients With Tricuspit And Mitral Valve Insufficiency

Selda TEKIN[1], Esra ADIYEKE[1]

[1]Martyr Prof. Dr. İlhan Varank Education and Research Hospital

INTRODUCTION - PURPOSE: Posterior reversible encephalopathy syndrome(PRES) is a clinic condition characterized by vasogenic edema affecting the posterior occipital and parietal lobes of the brain which presented by epilepsy,visual disturbances and changes in consciousness.It has been associated with preeclampsia/eclampsia,hypertension, immunodeficiency syndromes and immunosuppressive drugs in the literature.In our case,we aimed to present a 41-year-old patient who underwent emergency c/s due to preeclampsia and was followed up and treated in our icu with the diagnosis of PRES syndrome on the 5th postoperative day.

CASE: 41-year-old patient(with the history of mitral-tricuspid valve insufficiency)who had an emergency C/S operation 5 days ago due to preeclampsia,was admitted to our icu with altered mental status and respiratory distress.With the results of chest X-ray and echocardiography, she was taken to non-invasive CPAP support due to diagnosis of hypertensive pulmonary edema and forced diuresis treatment was started. Antihypertensive treatment was also applied to the patient who was hypertensive despite active diuresis.Cranial MRI was performed in the patient whose respiratory distress regressed but the altered mental status did not improve. Because of the symmetrical edema was observed in the occipital and both parietal lobes on MRI,antiedema treatment was started with the diagnosis of PRES syndrome.The patient was discharged after 3 days of icu admission with GCS:15/15 and without sequelae.

DISCUSSION - CONCLUSION: The most common cause in the etiology of PRES syndrome is preeclampsia at a rate of 7-20%.However, it can also be seen frequently due to resistant hypertension.Early diagnosis,treatment are important.Otherwise,it may cause permanent brain damage and neurological sequelae.We think that preeclampsia,persistent hypertension after c/s,pulmonary edema due to valve insufficiency caused the disease in our case.In pregnant patients diagnosed with preeclampsia/eclampsia and altered mental status,blood pressure regulation,close follow-up and consideration of PRES syndrome in the differential diagnosis will be life-saving by preventing the development of neurological sequelae with early diagnosis and treatment.

Keywords: PRES, ICU, Persistent Hypertension, eclampsia, preeclampsia

Pub No: O-014

Forearm and Cerebral Oxygenenation State Monitorization in Newborns During Ductus Arteriosus Stenting with Axillar Artery Cannulation

Ezgi DIRENÇ YÜCEL[1], Hatice Dilek ÖZCANOĞLU[1], Funda GÜMÜŞ ÖZCAN[1]

[1]Başakşehir Çam ve Sakura Şehir Hastanesi

INTRODUCTION - PURPOSE: Near-infrared spectroscopy (NIRS) offers non-invasive, real-time monitoring of tissue oxygenation. Although it has been used predominantly to assess cerebral oxygenation, it has gained popularity in many clinical settings in all age groups, including newborns. We aimed to discuss our experience in 3 newborns who underwent axillary cannulation for ductus arteriosus (DA) stenting recently in pediatric angiography cath lab.

CASE: All cases were male and the mean age was 7.6 days, and the mean weight was 3 kg. The cardiac pathology of the patients were; ventricular septal defect(VSD) with pulmonary atresia(PA), total pulmonary venous return anomaly with tricuspit atresia(TA), hypoplastic left heart syndrome (HLHS) with pulmonary stenosis(PS). All patients needed axiller artery approach, due to their ductus arteriosus' vertical shape. After induction of anesthesia by considering hemodynamic stabilization. On ventilator,the fiO2 was set to 21%,but increased in deep hypoxic conditions. After the stent placement, fiO2 was increased to 100%. Cerebral NIRS(cNIRS) and forearm NIRS(fNIRS) were placed and recorded during the procedure. All patients were cyonatic and the mean SO2 was 63,6%. The mean decrease in fNIRS at the time of axillary cannulation was 42,6% (max 53%, min 25 %). On the other hand, cNIRS decreased during stent replacement, and the mean decrease was 32%. And correlation between cNIRS values and SO2 change was observed. All NIRS values returned to the base level at the end of the cannulation. Patients were transferred intubated to the pediatric cardiovascular intensive care unit after the procedure. Pseudoaneurysm was occured as a complication in one patient whose fNIRS decreased most, and it treated surgically.

DISCUSSION - CONCLUSION: Whereas arterial oxygen saturation (SO 2) reflects only oxygen supply to tissue, NIRS may reflect changes in regional tissue oxygenation and thus the balance of local oxygen supply and demand. It can show early changes and be a warning sign before complications occur.

Keywords: pediatric anesthesia, monitorization, near-infrared spectroscopy, congenital heart disease, newborn

Pub No: O-015

Fluoroscopy guided caudal epidural anesthesia in severe ankylosing spondylitis patient who undergoing TUR-P : a case report

Seza SENTURK[1], Saba Nur KAYA[1], Hatice Betul ALTINISIK[1]

[1]Çanakkale 18 Mart Üniversitesi Sağlık Uygulama Ve Araştırma Hastanesi

INTRODUCTION - PURPOSE: Spinal anesthesia with a sensory level T10 is the first line anesthesia technique used for Transurethral resection of the prostate (TUR-P) operation. However, the insertion of the spinal needle in AS patient is impossible due to the formation of bony bridges between the vertebral bones. We present a case who has diagnosed a severe AS were successfully operated under fluoroscopy guided caudal epidural anesthesia(CEA) with highest sensory block level L1.

CASE: A 58-year-old ASA IV male, with AS complicated with pulmonary dysfunction was scheduled for TUR-P. Median and paramedian lumbar puncture attempts were failed. The patient prepared for fluoroscopy CEA. 10 ml 0.5% bupivacaine and 10 ml 2% lidocaine hydrochloride in a volume of 20 mL was injected into the caudal epidural space under fluoroscopy guide.(Fıgure 1) The highest sensory block level were evaluated as L1. Operation was completed uneventfully. At the end of the operation sensory block level were L3.

Fıgure 1



DISCUSSION - CONCLUSION: Discussion To the our best of PubMed research there are limited clinical studies and case report published about the use of CEA for TUR-P operations show that selective spinal anesthesia with above S1 sensory block level provides adequate anesthesia for TUR-P operations.ConclusionThis case report highlighted that 1) T10 sensory level is not necessary in TURP patient when using continue resectoscope. 2) Caudal epidural block should be keep in mind in patient with AS who has difficult airway and difficult spinal block circumstances. On the other hand, to our opinion fluoroscopy guided CEA is not easy technique in patient with AS due to difficulty of positioning. Patient with lateral sided position may be more comfortable when compared to prone position. Further studies should be made by in an experienced hands to evaluate ultrasound guided CEA under lateral sided position in patient with AS.

Keywords: Ankylosing spondylitis, TUR-P, caudal epidural block

Pub No: O-016

Percutaneous Tracheostomy Management in COVID-19 Patients

Şule VATANSEVER[1], Gaye ŞENSÖZ ÇELİK[1], Cengiz POLAT[1], Melike DUMAN[1], Zekeriya ERVATAN[1]

[1]Prof. Dr. Cemil Taşçıoğlu Şehir Hastanesi

INTRODUCTION - PURPOSE: Prolonged mechanical ventilation(MV) has a negative effect on morbidity and mortality in COVID-19 patients in the intensive care unit(ICU). We aimed to investigate the effect of the timing of percutaneous tracheostomy(PC) on mortality and morbidity.

MATERIALS AND METHODS: Following ethics committee approval, patients admitted to the ICU with diagnosis of COVID-19 and who underwent PC due to prolonged MV were analysed retrospectively. PC were performed by the same team and performed under strict asepsis and with full personal protective equipment. Patients' demographics, medical history, SOFA scores on admission, discharge and the day after tracheostomy, CRP, procalcitonin, tracheostomy timing, Horowitz ratio before and after the procedure, complications, weaning time and discharge/exitus status were recorded.

RESULTS: Results are shown in Table-A.

Table-A

	Discharged(n=18)	**Exitus(n=12)**	**Total(n=30)**
Mean age	68	62,4	63,1
Gender	W:5 M:13	W: 3 M:9	W:8 M:22
Medical history	DM:9 HT:7 CVD:6 COPD:4 IHD:2 CKD:3 Asthma:1 Neurological disorder:1	DM:4 HT:5 CVD:1 COPD:4 IHD:1 CKD: 3 Malignity:3	DM:13 HT:12 CVD:7 COPD:8 IHD: 3 CKD:6 Asthma:1 Neurological disorder:1

	Malignity:1 Arrhythmia:1 CHF:1		Malignity:4 Arrhythmia:1 CHF:1
Mean length of ICU stay (days)	56,9	46,4	52,7
Mean number on mechanical ventilation (days)	43,7	45,2	44,3
Mean SOFA scores on admission	5,08	5,25	5,16
Mean time from intubation to Percutaneous tracheostomy	12,4	18,4	14,8
Mean SOFA score after Percutaneous tracheostomy	6	7,7	6,7
Mean Horowitz index (pO_2/fiO_2) before/after Percutaneous tracheostomy	275,6 / 325,06	258 / 282	268,9 / 308,4

DM: Diabetes Mellitus, HT: Hypertension, CVD: Cerebrovascular Disease, COPD: Chronic Obstructive Pulmonary Disease, IHD: Ischemic Heart Disease, CKD: Chronic Kidney Disease, CHF: Congestive Heart Failure

DISCUSSION - CONCLUSION: Early tracheostomy is defined as <10(1) or <14(2) days in different studies, a multidisciplinary guideline suggests delaying tracheostomy at least 10 days post-extubation(3), our mean tracheostomy day was 14.8. Anticoagulant therapy, hemodynamic instability, prolonged time of prone positioning, and physicians' hesitations due to the risk of transmission caused the prolongation of the tracheostomy period after intubation. PC timing was shorter in patients discharged compared to patients who died, however no significant difference found in mortality between early and late tracheostomies in previous studies. Early tracheostomy reduces length of stay(LOS)(4)(5), our LOS was longer in patients who underwent early tracheostomy(<14days). The need for tracheostomy is higher in SOFA score >4.5(6), our mean SOFA score was 5.16. SOFA score after PC was found higher in patients who died. Criteria for tracheostomy were identified as PaO2/FiO2>200mmHg(6), our mean PaO2/FiO2 was 268,9 and meet the criteria.None of the staff was diagnosed COVID-19, and it might be more appropriate for a specialized team for interventional procedures during the pandemic. As a result, we believe that tracheostomy performed before 14 days will give more positive results on mortality and morbidity.

Keywords: COVID-19, Percutaneous tracheostomy, ICU, Mortality, Morbidity

Pub No: O-017

Anesthetic Approach In Pregnant Women With Arnold-Chiari Type I Malformation: A Case Report

Dr. Yusuf İPEK[1], Dr Hakan AKELMA[2]

[1]Mardin Training and Research Hospital
[2]Mardin Artuklu University Faculty of Medicine

INTRODUCTION - PURPOSE: Arnold-Chiari malformation(ACM) has been defined as 4 types and Arnold-Chiari malformation type I (ACM-I) is the condition of herniation of the cerebellar tonsils towards the cervical spinal canal without myelomeningocele(1).Hydrocephalus accompanies 10% of ACM Type 1 cases, 30% of them are asymptomatic(2).Anesthetic approach is important because cranial nerve involvement and increased intracranial pressure may occur in ACM (3).In this case, we aimed to review the anesthetic methods of cesarean section performed under elective conditions in a patient with ACM-I diagnosis.

CASE: Our case was a 30-year-old woman,78kg,38 weeks pregnant,diagnosed with ACM-I. In the anesthesia evaluation,it was learned that the patient was admitted to our hospital with complaints of vertigo and weakness in the upper extremity 3-years-ago, and the diagnosis was made after cranial MRI(Figure 1.The patient did not have any systemic problems other than this disease.Routine physical examination were normal in laboratory examinations.In the examination,it was evaluated that there would be no difficulty in intubation an appropriate anesthetic approach was planned.The patient was routinely monitored. In the supine position,heart rate was 84beats/min and blood pressure was 115/73 mmHg.After induction with propofol 2.5mg/kg and rocuronium 0.6mg/kg,successful intubation was achieved in the neutral position by avoiding hyperextension of the head.Anesthesia was maintained with 2% sevoflurane and oxygen/dry air(50%:50%)inhalation.After a healthy delivery,2mcg/kg fentanyl was added.The surgical procedure took 45 minutes.Hemodynamic parameters remained stable and there were no complications.There was no neurological problem in our postoperative patient.Two days later, the patient was discharged with full recovery.

Figure 1

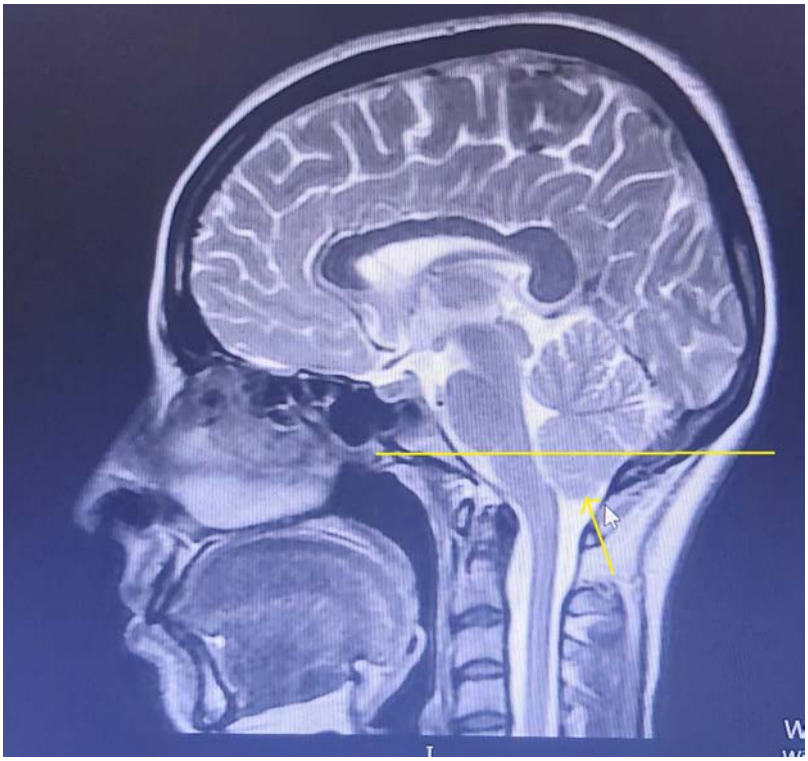

Previously diagnosed Arnold-Chiari Malformation lesion site

DISCUSSION - CONCLUSION: When evaluating patients with ACM-I who will undergo cesarean section,the joint approach of the Department of Pediatrics,Neurosurgery and Anesthesiology and Reanimation is essential.While choosing the anesthesia method, first of all, the clinic of the patients should be taken into consideration,the benefit and harm of the method should be determined and the method should be decided.

Keywords: Arnold-Chiari Malformation, General Anesthesia, Pregnancy

Pub No: O-018

Anesthesia Management in Emergency Urological Surgeries: Analysis of 110 Cases

Nurettin KURT[1]

[1]Department of Anaesthesiology and Reanimation, Van Yuzuncu Yil University Faculty of Medicine, Van/Turkiye

INTRODUCTION - PURPOSE: Admissions to hospital emergency departments with urological complaints are relatively common, but they are rarely life-threatening, and few require emergency surgery. From these urological complaints; Testicular torsion,ureteral stones,penile fracture,priapism and traumas are the most urgent conditions requiring surgery. A multidisciplinary approach between emergency clinic, urology and anesthesiology is important for the early diagnosis and surgical decision of these patients(1,2). In the literature,studies on anesthesia management in urological emergencies are rare. The aim of this study is to evaluate the anesthesia methods, diagnoses, comorbidities and surgical durations used in urological emergencies.

MATERIALS AND METHODS: This retrospective study;The data of the patients who were operated under emergency conditions by the urology clinic between 2020-2022 were planned by obtaining the patient follow-up forms and the hospital information management system.Patients whose data could not be reached and missing were excluded from the study. 110 patients aged between 18-82 years,whose data were fully accessible and informed consent was obtained, were included in the study.

RESULTS: Of the cases, 98 were male and 12 were female,with a mean age of 41.5±15.9 years.The ASA-I, ASA-II, and ASA-III scores of the patients were 57.9%, 27.4%, and 14.7%, respectively(Table-I). Reasons for operation in patients;47.3% were ureteral calculi 20.0% testicular tumor, 13.6% penile fracture, 11.8% testicular torsion, and 7.3% Fournier's gangrene. The anesthesia methods applied to the patients were spinal anesthesia with 79.1%, general anesthesia with 19.1% and sedo-analgesia with 1.8%, respectively(Tablo-II). No major complications developed in any of the patients.

Table-I. Demographic Characteristics of the Patients

		Min.-Max.	Median	Mean ± SD/n%
Age		18-82	39	41.5 ± 15.9
Gender	male			98 89.1%
	female			12 10.9%

ASA Score	I		64	57.9%
	II		30	27.4%
	II		16	14.7%

SD: standard deviation, **Min-Max:** Minumum-Maximum

Table-II. Anesthesia methods applied to patients and the causes of the operation

		Min-Max	Median	Mean±SD/n-%
Anesthesia Methods Applied	Spinal anesthesia			87 79.1%
	General anesthesia			21 19.1%
	Sedo-analgesia			2 1.8%
Cause of Operation	Ureteral calculi			52 47.3%
	Testicular tumor			22 20.0%
	Penile fracture			15 13.6%
	Testicular torsion			13 11.8%
	Fournier's gangrene			8 7.3%
Duration of Surgery (minute)		30.0 - 120.0	60.0	54.9 ± 18.5

SD: standard deviation, Min-Max: Minumum-Maximum

DISCUSSION - CONCLUSION: Surgery is required in only 6.1% of urological cases admitted to the emergency department(3). These urological emergencies are not usually life-threatening, but can have irreversible consequences if not managed promptly(4).In the literature, studies on the anesthetic management of urological emergencies requiring surgery are limited.We believe that regional anesthesia techniques can be used successfully in anesthesia management in these patients,unless there are significant contraindications.

Keywords: Urologic emergencies, Anesthesia method, Testicular torsion, Ureteral calculi, Regional anesthesia

Pub No: O-019

Effect Of Postoperative Erector Spinae Plane Block As A Rescue Pain Therapy In Patients Undergoing Upper Abdominal Surgery: A Case Series

Taner ABDULLAH[1], Huru Ceren GOKDUMAN[1], Funda GUMUS OZCAN[1]

[1]University of Health Sciences, Istanbul Basaksehir Cam and Sakura City Hospital, Istanbul, Turkey

INTRODUCTION - PURPOSE: Postoperative pain management is an important concern for abdominal surgeries. Although opioids are frequently administered, their respiratory and gastrointestinal side effects might limit their adequate usage. Here, we present a case series of Erector Spinae Plane Block (ESPB) for the postoperative usage in patients undergoing upper abdominal surgery.

CASE: Ten patients who preferred regional techniques over opioid administration were evaluated. Demographic and surgical characteristics are presented in Table 1 and 2, respectively. After standard monitoring, anesthesia was induced with 2mg/kg propofol along with 2mcg/kg fentanyl and 0.6mg/kg rocuronium bromide, and maintained with sevoflurane (1%-2%) and remifentanil (0.05-0.3mcg/kg/min). 8mg dexamethasone, 3g magnesium-sulphate, 1g paracetamol, 20mg tenoxicam and 100mg tramadol was used for the multimodal analgesia. Fluid administration during the surgery was set between 3–5ml/kg/h and additional boluses were used for maintaining perfusion. In the postoperative care unit (PACU), ESPB was performed at the T8-level using a linear ultrasound probe and a peripheral nerve block needle. After confirming the location with physiological saline, 5ml 1% lidocaine and 20ml 0.25%bupivacaine were injected and its spread was visualized under ultrasonography. The indicated doses were within the safe dose range for all patients to be used according to their weight. Blocks were applied unilaterally (right) or bilaterally in line with the surgical incision. Meperidine boluses were used when the target numeric rating scale (NRS) score <4 was not achieved. Patients were followed up for 60 minutes in the PACU. NRSs of patients on different time points are shown in Figure 1. Only 2 (20%) patients needed meperidine bolus while 8 (80%) patients were saved from opioid administration. A significant decrease was observed in NRS-scores on the 15th min compared to baseline (p:0,024).

Numeric Rating Scale Scores on Different Time points

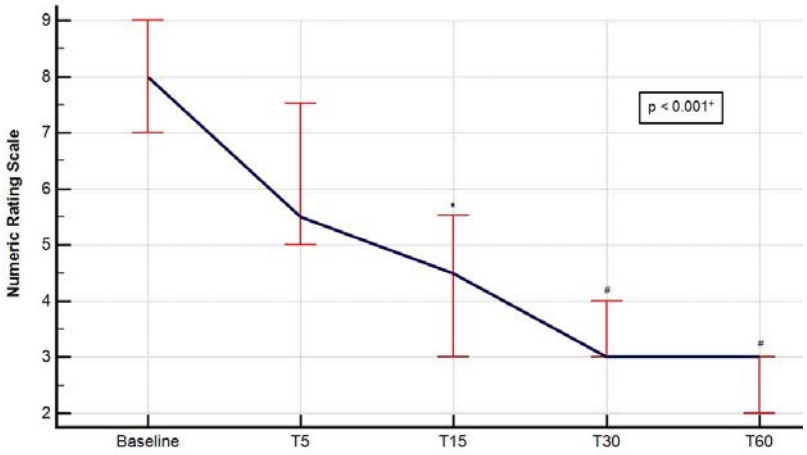

Data are expressed as median 95% (confidence interval). T5, T15, T30 and T60 indicate 5th, 15th, 30th and 60th minutes following the baseline, the moment when ESPB was applied. The Friedmann test was used for evaluating the intragroup differences (+p<0,001). Pairwise comparison was performed using the Dunn test. * p:0,0024 when compared to the baseline value. # p<0,001 when compared to the baseline value.

Table 1: Characteristics of Patients.

Variables (n=10)	
Gender (M / F)	8 / 2
Age (years)	46,1 ± 11,2
BMI (kg/m^2)	23,9 ± 2,5
ASA (1 / 2)	3 / 7
Comorbidities	
DM	2 (%20)
HT	2 (%20)
Asthma	1 (%10)
Thyroid Dysfunction	1 (%10)

Values are expressed as number (percentage), mean ± S. m: male, f: female, BMI: body mass index, DM: diabetes mellitus, HT: hypertension

Table 2. Surgical indications and surgeries performed

Patient No	Diagnosis	Surgery	Incision	Surgery duration (min)
1	**HCC**	**Left Hepatectomy**	**Epigastric median + subcostal (right)**	**175**
2	Gastric Cancer	Total Gastrectomy	Epigastric median	165
3	Gallbladder neoplasia	Open Cholecystectomy	Subcostal (right)	100
4	HCC	Left Hepatectomy	Epigastric median + subcostal (right)	195
5	Pancreatic Cancer	Whipple Procedure	Bilateral Subcostal	240
6	**Gallbladder neoplasia**	**Open Cholecystectomy**	**Subcostal (right)**	**100**
7	Gastric Cancer	Total Gastrectomy	Epigastric median	260
8	Cyst Hidatid	Hepatic Segmentectomy	Epigastric median + subcostal (right)	180
9	Cyst Hidatid	Hepatic Segmentectomy	Epigastric median + subcostal (right)	210
10	Gastric Cancer	Total Gastrectomy	Epigastric median	240

HCC: hepatocellular carcinoma. Patients who needed additional IV medication are indicated with bold font.

DISCUSSION - CONCLUSION: The use of ESPB as a rescue therapy postoperatively diminishes the need for opioid administration. This effect might be able to enhance patient outcomes.

Keywords: truncal blocks, regional anesthesia, major abdominal surgery, erector spinae plane block

Pub No: O-020

The Effects Of 5 Cmh2o Peep Application On Respiratory Mechanics, Oxygenization And Hemodynam During General Anesthesia In Prone Position In Lumbar Disc Hernia Operations

İbrahim DEMIR[1], Şule VATANSEVER[2]

[1]Mardin Training and Research Hospital
[2]Professor Doctor Cemil Taşcıoğlu City Hospital

INTRODUCTION - PURPOSE: During the surgical procedures,the vital parameters of the patients may vary not only depending on the type of surgery and general anesthesia,but also depending on the positions in which they are operated.The prone position is used for specific surgical indications,as well as to improve oxygenation, especially in the treatment of acute respiratory failure(1).Many surgeons find the prone position more appropriate in lumbar disc herniation(LDH) surgery(2).However, in the prone position, the patient's thorax and abdomen remain under pressure and many respiratory and hemidynamic changes occur.In this study,we investigated the effects of PEEP application at physiological limits(5cmH2O) on respiratory mechanics,arterial oxygenation and hemodynamic parameters in patients who underwent LDH in the prone position.

MATERIALS AND METHODS: We conducted our prospective, randomized study,after the ethics committee approval, in the approved ASA I-II group,aged 18-65 years,who were planned for LDH operation in the neurosurgery operating room of our hospital,who agreed to volunteer for the study,body mass index<30kg/m2.We performed this study on 50 patients with pre-existing cardiac and pulmonary disease and no sensitivity to general anesthetic agents.We randomly divided our patients into Group I(PEEP 0) without PEEP and GroupII(PEEP 5) with 5cmH2O PEEP.

RESULTS: We did not observe a statistical difference in SAB, DAB, MAP and Pulse with the application of PEEP.In our study, we found a statistically significant increase in PaO2, Pplato, PIP and compliance values (Cd: Dynamic Compliance, Cs: Static Compliance) with the use of 5cmH2O PEEP.Changes in Cs,PIP,Pplato,PaO2:(Table 1,2,3,4,5 and Chart 1,2,3,4,5).Statistical between groups in terms of VD/VT and P(a-et)CO2 values we could not find a difference(p>0.05).

Graphic 1

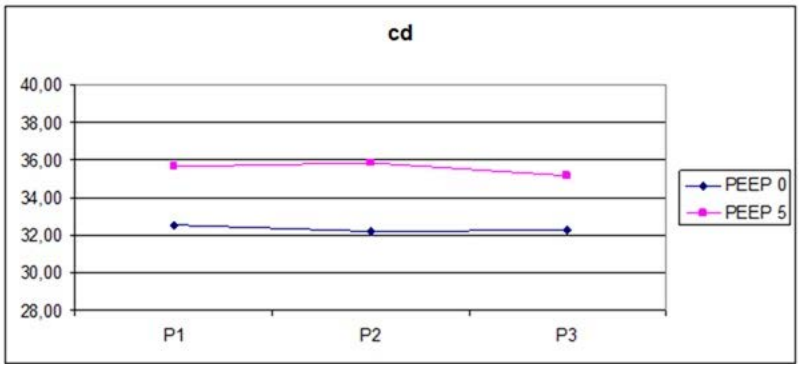

Graphic 1: Affecting dynamic compliance of PEEP: Changes in Cd value

Graphic 2

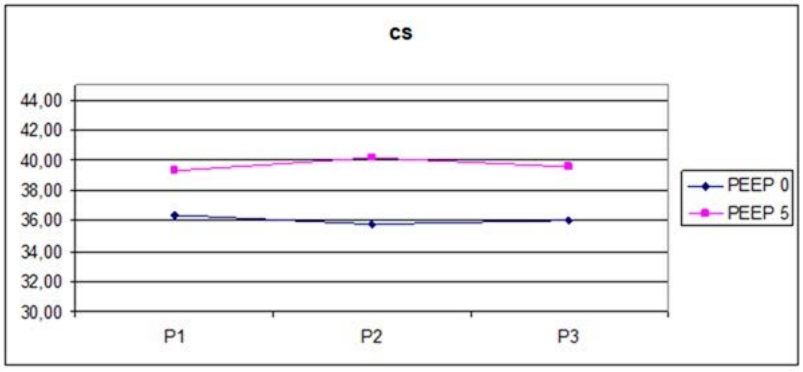

Graph 2. Influence of dynamic compliance of PEEP: Changes in Cs value

Graphic 3

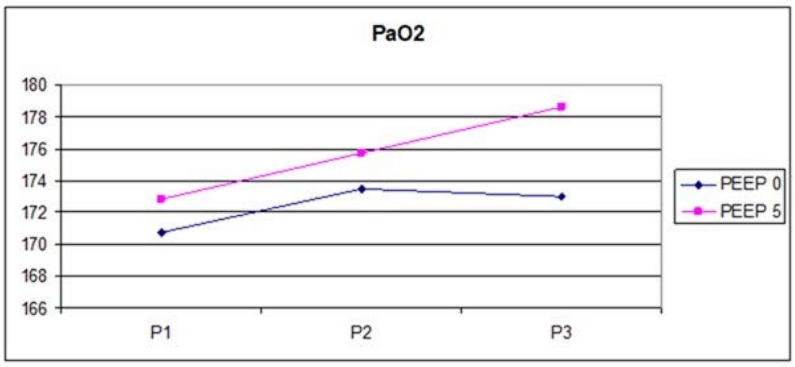

Graphics 3. Changes in PaO2

Table 1

	PEEP 0	**PEEP 5**	**t**	**p**
Cd_S1	36,10 ± 2,16	37,40± 2,02	-2,203	**0,032**
Cd_P	32,37±1,63	35,56 ± 1,82	-10,223	**0,000**
Cd_S2	33,18 ±2,05	35,28 ± 2,11	-3,558	**0,001**
F	66,041	29,363		
P	**0,000**	**0,000**		

Affecting dynamic compliance of PEEP: Changes in Cd value

Table 2

	PEEP 0	**PEEP 5**	**t**	**p**
Cs_s1	40,08 ±2,53	41,40 ± 2,50	-1,861	**0,069**
Cs_P	36,08 ± 1,93	39,66 ±1,98	-9,932	**0,000**
Cs_s2	37,18 ± 2,04	39,28 ± 2,26	-3,456	**0,001**
F	48,494	22,255		
P	**0,000**	**0,000**		

Influence of dynamic compliance of PEEP: Changes in Cs value

Table 3

	PEEP 0	**PEEP 5**	**t**	**p**
PaO2_S1	169,24 ± 10,28	166,68 ± 11,69	0,822	0,415
PaO2_P	172,43 ±6,87	175,75 ± 11,69	-1,941	0,054
PaO2_S2	167,20 ±8,48	176,04 ± 13,82	-2,727	**0,009**
F	3,904	29,432		
P	0,035	**0,000**		

Changes in PaO2

DISCUSSION - CONCLUSION: The use of 5cmH2O PEEP in the prone position increased compliance and PaO2 without causing any hemodynamic adverse effects;We observed that it prevents the rise of P(a-et)CO2.Therefore,we believe that the application of physiological PEEP can be recommended in healthy people who will be operated in the prone position.

Keywords: lumber disc surgery, prone position, PEEP application, gas exchange parameters, general anesthesia

Pub No: O-021

The Effectiveness of Clavipectoral Fascia Plane Block In Patients Undergoing Emergency Clavicle Fracture Surgery

Arzu KARAVELİ[1], Hayri Fatih METİNYURT[1], Ali Sait KAVAKLI[2]

[1]University of Health Sciences, Antalya Training and Research Hospital, Department of Anesthesiology and Reanimation, Antalya, TURKEY
[2]Istinye University Medical Faculty, Department of Anesthesiology and Reanimation, Istanbul, TURKEY

INTRODUCTION - PURPOSE: Clavicle fractures (CF) are frequently encountered in emergency operating room settings, and they constitute 2.6% of all fractures. Regional anesthesia (RA)-techniques is always challenging due to the variability and complexity of the clavicle nerve innervation. Moreover, peripheral nerve block techniques are associated with undesirable effects. Clavipectoral fascial plane block (CPB), is a novel procedure-specific RA-technique that can provide anesthesia/analgesia for clavicle surgeries. In this case series, it was aimed to report the effectiveness of CPB in nine patients undergoing emergency surgery. Informed written consent was obtained.

MATERIALS AND METHODS: CPB was performed before the operation and with USG (linear probe/in-plane technique). Local anesthetic (LA) (analgesia:0.25%-bupivacaine/anesthesia:0.5%-bupivacaine) was injected between the clavipectoral fascia and the clavicle periosteum on both the medial and lateral side of the fracture (10 mL/per side/total 20 mL). Postoperative pain was evaluated using the NRS scores. As part of the multimodal-analgesia-approach, all patients were received acetaminophen and tramadol before the end of the surgery, and were ordered to receive acetaminophen(1g-iv) every 8h, postoperatively. If the patient reported NRS scores of ≥4, tramadol(50 mg-iv) was ordered. Demographic data, type of anesthesia, surgery duration , cause of fracture, opioid consumptions length of hospital stay and complications related to the block were recorded.

Figure 1. (a) Radiological image of clavicle fracture before surgery, (b) Ultrasonographic view of the clavipectoral fascial plane block, (c) Radiological image of clavicle fracture after surgery

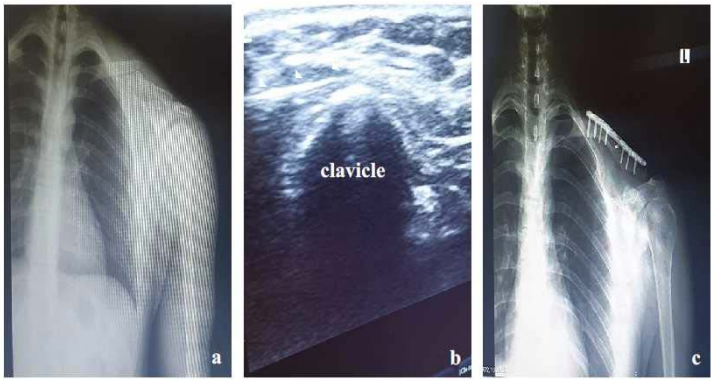

RESULTS: The mean age of the patients was 32.55±10.97years. The CF was developed due to simple fall in five patients. In two of the nine patients, the operation was performed with CPB and did not require general-anaesthesia. Only one patient needed additional LA-infiltration due to latero-posterior clavicle pain during the incision. The intraoperative fentanyl requirement was 1.11±22.04mcg. The patients maintained a NRS for pain of 0–2/10, postoperatively. None of the patients needed rescue analgesia. No complications related to block were observed.

DISCUSSION - CONCLUSION: In conclusion, CPB provides effective anesthesia and/or analgesia for CF by eliminating the undesirable effects of proximal peripheral nerve block techniques.

Keywords: clavicle fracture, clavipectoral fascial plane block, postoperative pain

Pub No: O-022

Infections that may be missed during the COVID-19 Pandemic, Legionella Pneumophila Infection: a Case Report

Mehmet Kılıç[1], Kübra Saçar Kübüç[1]

[1]Van Education and Research Hospital, University of Health Sciences

INTRODUCTION - PURPOSE: SARS-CoV-2 is a new virus that causes coronavirus-19 disease(1,2).Legionella bacteria,can be spread either sporadically or as an outbreak,is one of the important nosocomial and community acquired pneumonia causes.In this case,we would like to present the patient diagnosed as Covid-19 than as a differential diagnosis,had Legionella Pneumonia.

CASE: 43years old male who has not any chronic disease before,had admitted to the hospital with complaints of confusion,dysartria,weakneess,pain and respiratory failure.On laboratory findings;hyponatremia(Na:120mml/L),on thorax CT-scan;ground glass opacities bilaterally were detected and he was internalized in intensive care unit with hypoxia and suspect of Covid-19.It is learned that he was a worker at decontamination and air conditioning systems and he had stayed at a hotel for 7 days.He had contact with a Covid-19 patient at his work 1 week ago. He is smoker (4pockets/day/22 years),drinks alcohol (22years).He had 2 dose of BioNtech vaccine(3.5 months ago).At physical examination;confusion,tremor,muscle weakness at lower extremities were detected.He was stabile hemodynamically,with 5L/min O2 mask SPO2:%95, respiratory rate:22/min.Covid-19PCR was negative at two tests one day apart.With these findings,Legionella pneumonia had place as differential diagnosis.Legionella pneumophilia Sg-1 antigen was positive at blood,urine and sputum analysis.He was discharged from ICU 4 days and hospital 10 days after the Legionella treatment.

Figure- 1. some images in the treatment of the patient

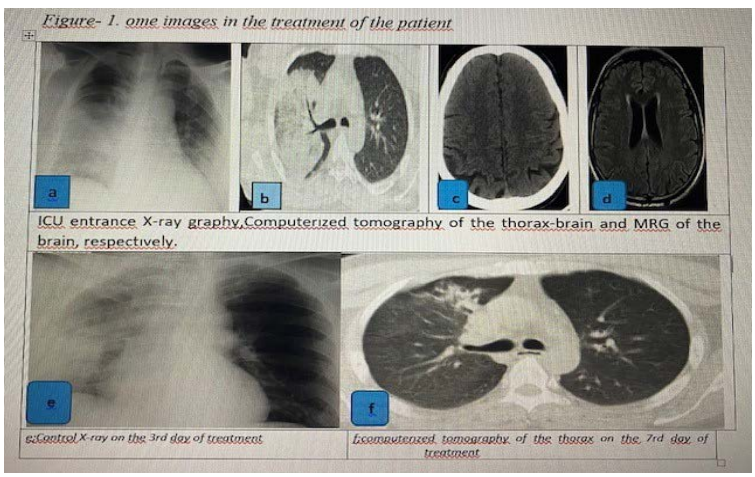

Table -1. Table showing the laboratory parameters of the patient.

	Admission to the ICU	1rd day	2rd day	3rd day	6rd day	10rd day
Biochemistry	15.02.2022	16.02.2022	17.02.2022	18.02.2022	21.02.2022	25.02.2022
Serum Sodyum (Na) mmol/L	120	130	140	136	130	136
Kalsiyum (Ca) mg/dL	7,96	8,04	7,45	8,35	9,63	9,80
Potasyum mmol\L	4,14	4,48	3,36	4,0	6,0	5,48
Klor (Cl) mmol\L	83,2	90,6	99,4	94	98	96,7
Bilirubin (total) mg\dl	0,571	0,504	0,356	0,351	0,30	0,035
CRP mg\L	327,18	297	239	127	18	3,97
Procalcitonin ng/mL	0,43	0,49	0,32	0,10	0,12	0,07
Glukoz(mg/dL)	179,6	285	276	374	568	340
Aspartat Transminaz (AST)U\L	94,7	87,6	35,2	23,4	26,3	18
Alanin Aminotransferaz (ALT)U\L	46,4	48,8	40,1	35,8	78,5	59,1
Kanda Üre mg/dl	32,0	32,2	61	70	66,8	65,8
Kreatinin mg/dl	1,07	0,91	0,90	0,92	0,86	1,08
Troponin I ng/mL	0,100	0,100	0,100	0,100	0,100	0,100
Kreatin kinaz (CK) U\L	1471	-	238	18	-	-
Laktat denidrogenaz (LDH) U\L	337	184	-	-	-	-
D-dimer ng/mL	887	735	424	131	-	-
Ferritin ng/mL	>2000	5815	>2000	2183	>2000	1717
Hemogram						
WBC 10^9/L	9,66	7,21	9,09	10,11	11,49	14,01
HGB g/dL	14,2	14,1	13,7	14	15,8	16,7
PLT 10^3/uL	265	256	329	421	699	463
LY 10^9/L	1,25	0,50	0,63	0,78	1,78	3,97
Protrombin zamanı (INR)	1,10	1,09	1,12	1,08	-	-
Arterial Blood Gas						
pH	7,492	7,35	7,45	7,48	7,42	7,43
pCO2 mmHg	31,2	34,9	39,6	41,7	34,8	37,6
pO2 mmHg	40,1	78	82	80	81	64,1

sO_2 %	76,8	94,6	96	94	95	90,5		
HCO_3^- mmol/L	25,2	20,0	26,5	29,3	24	24,6		
Base(Ecf)	0,6	-5,6	2,4	7	-0,9	0,2		
Laktat mmol/L	2,1	2,6	1,6	3,0	2,8	2,5		
COVİD19 PCR	Negatif	Negatif						
ICU: intensive care unit, PCR;polymerase chain reaction								

Tablo- 2.Table showıng the methods the test ıs worked and the test results.

Worked method	Sample type	Sampling date	Laboratory acceptance date of the sample.	Result date	R
Legionella pneumophila Serogrupg-1	Urine	17.02.2022	21.02.2022	21.02.2022	P
Legionella pneumophila IgM (IFA)	Serum	17.02.2022	21.02.2022	28.02.2022	P
Legionella pneumophila (culture)	Sputum	17.02.2022	21.02.2022	02.03.2022	N
TLegionella pneumophila Serogrupg-1, IFA; Indirect Fluorescent Antibody.					

DISCUSSION - CONCLUSION: Some rare diseases can appear at risk groups during pandemics. Legionella spp which is aerobic,gram negative intracellular pathogen;is an important microorganism for public health.It is a cause of both community acquired and nosocomial pneumonia.Legionella Pneumophilia is the major cause of legionella cases with %90 percent.For Covid-19 patients who were followed in ICU,Legionella should be considered as differential diagnoses as it has the same clinical findings.The patients should be evaluated for any diagnoses and in case of suspicion;with fast and reliable tests should be performed.Thus early diagnosis and early treatment can prevent inappropriate antibacterial treatment and higher ICU mortality.

Keywords: Legionella Infection, Covid-19, Pandemic, pneumonia

Pub No: O-023

Trauma Followed In The Intensive Care Unit Affecting Mortality And Morbidity In Patients Factors

Cansu KILINÇ BERKTAŞ[1], Müslüm AKKILIÇ[1], Kadir YEŞİLDAL[1], Tarkan MINGIR[1], Namigar TURGUT[1]

[1]Prof. Dr. Cemil Taşçıoğlu City Hospital

INTRODUCTION - PURPOSE: Trauma is an important public health problem with sociocultural and economic consequences that affect the mortality and morbidity caused by primary damage caused by its direct effect and secondary damage that develops afterwards. The aim of this study is to determine the factors affecting mortality and morbidity in trauma patients followed in the intensive care unit (ICU).

MATERIALS AND METHODS: In this study we included patients who were followed up in the ICU due to trauma between 2019-2021; demographic data, laboratory findings, used for vasopressors, development of renal failure, need for dialysis, blood replacement requirement, mechanical ventilation (MV), trauma and ICU admission scores (APACHE II, SOFA, GKS, TRISS, ISS, RTS) were recorded. Statistical analysis performed and $p<0.05$ values considered statistically significant.

RESULTS: 194 trauma patients were included in the study. 179 were male, mean age±SD 37.20±16.32 years. The most common traffic accident in the patients (34.5%) was the head and neck region with 39.2%. Mortality was observed in 19.6% of the patients, and the highest mortality was in traffic accidents with 50.3% and the highest in the head and neck region with 31.6%. ICU hospitalization days were 3 (0-73), and MV days were 0.25 (0-73). Vasopressordrug use in 34.5% of the patients, MV need in 53.1%, septic shock in 4.1%, renal failure in 3.1%, need for hemodialysis in 1.5%, 17% pressure ulcers developed in 0.5%, need for blood product replacement in 51.5%, and reoperation in 9.8%. Low GCS and TRISS score, high APACHE II, SOFA and ISS scores increased ICU, MV days and mortality.

Şekil 1: Skorlamaların mortaliteyi öngörmedeki ROC eğrileri

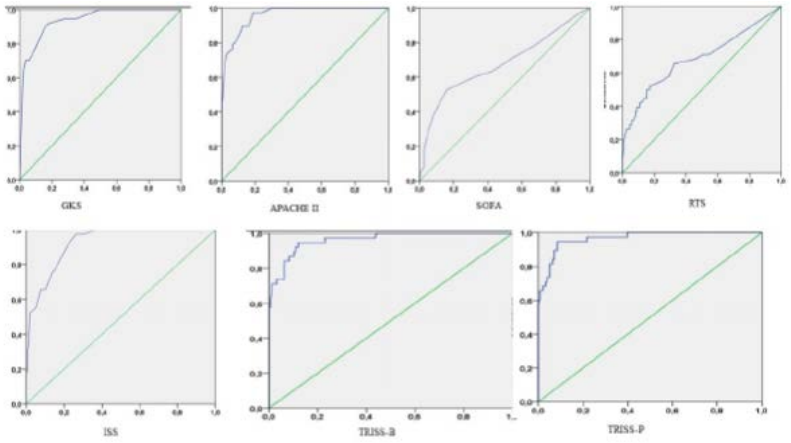

DISCUSSION - CONCLUSION: The results of our study showed that traffic accidents and head and neck injuries were the most common in our patients, APACHE II and ISS scores were more sensitive to predict mortality than TRISS, SOFA, GKS and RTS but TRISS score was more reliable in predicting mortality.

Keywords: trauma, intensive care, trauma scores, mortality, morbidity

Pub No: O-024

Our Application of Deep Cervical Block for Postoperative Analgesia in 2 Cases with Mastoidectomy and Temporal Bone Resection

Onur SARBAN[1], Nur USLU[1], Hilal ŞAHAN[1], Funda GÜMÜŞ ÖZCAN[1]

[1]Başakşehir Çam ve Sakura City Hospital

INTRODUCTION - PURPOSE: Neural innervation of temporal and mastoid bone regions are provided by the great auricular nerve and the lesser occipital nerve. Therefore, deep cervical plexus block (dCPB) involving these nerves can be used for analgesia in surgeries of this region. In this case report, we aimed to share our experience of dCPB for analgesia in one patient who underwent radical mastoidectomy and another patient who underwent subtotal temporal bone resection.

CASE: A 42-year-old male patient without any known additional disseases, who is scheduled for left modified radical mastoidectomy due to severe mastoiditis and a 58-year-old male patient with chronic obstructive pulmonary disease (COPD) who is scheduled for subtotal temporal bone resection due to squamous cell carcinoma was taken to the operating table, after the procedures were explained and informed consents was obtained. Both patients were intubated after routine anesthesia induction. Subsequently, invasive blood pressure monitoring was performed with radial artery catheterization in addition to routine anesthesia monitoring. In supine position under general anesthesia, the faces of the patients were turned to opposite side. With the help of 12 mHz linear probe, dCPB was applied by observing the transverse process from the C3 level and observing its spread into deep prevertebral fascia with 8 mililiters of 0.25% bupivacaine. Both surgeries lasted around 5 hours. Patients were extubated after administering 1 gram paracetamol and 100 miligrams tramadol for analgesia and transferred to service. The Visual Analogue Scale (VAS) scores of the patients, who were administered 3x1 paracetamol within postoperative 24 hours period were recorded.

USG Image of Deep Cervical Plexus



Image of Modified Radical Mastoidectomy Incision

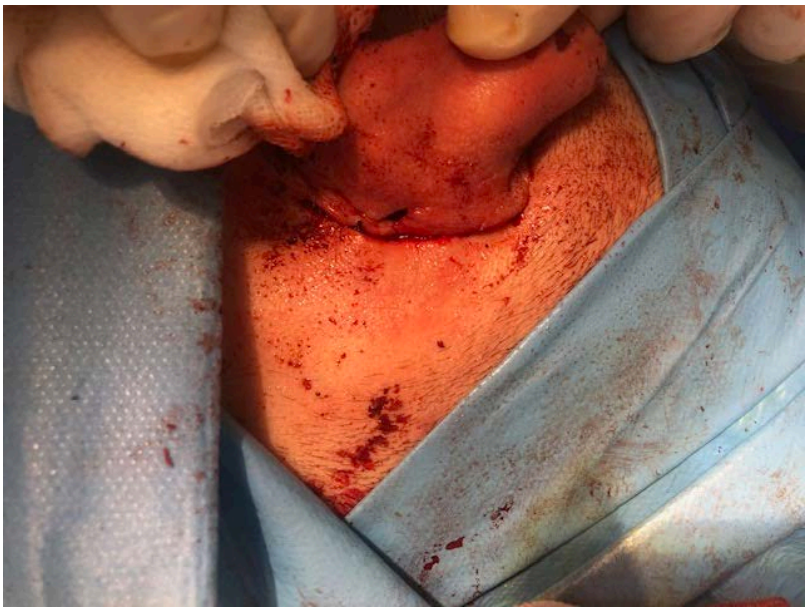

Image of Subtotal Temporal Bone Resection Incision



VAS Scores for Patients

	1st hour	4th hour	12th hour	24th hour
Patient 1	2	1	2	3
Patient 2	2	2	3	3

Preoperative Vital Signs for Patients

	Patient 1	Patient 2
Blood Pressure(mmHg)	132/84	148/89
SpO2(%)	100	96
Pulse(bpm)	76	68

DISCUSSION - CONCLUSION: VAS scores of patients were below 3 in 24-hour period and they did not need additional analgesics. We think, regional anallgesia in such patients has positive contribution both in terms of perioperative hemodynamics and by reducing the need for additional postoperative analgesics, avoiding possible complications and shortening hospitalization.

Keywords: cervical plexus, Mastoidectomy, Temporal Bone Resection, deep cervical plexus block, regional anesthesia

Pub No: O-025

An Unusual Shock With Extreme Tachycardia Without Hypovolemia in a Multi-Trauma Patient: Case Report

Alparslan Koç[1], Nurhan Eren[1]

[1]Erzincan Binali Yıldırım University Mengücek Gazi Training and Research Hospital

INTRODUCTION - PURPOSE: Tachycardia is a finding that occurs in vasodilatory shocks such as cardiogenic, hemorrhagic, hypovolemic, anaphylactic, and septic shock. Neurogenic shock, a consequence of spinal cord injury (SCI), manifests as hypotension, bradyarrhythmia, and temperature irregularities due to peripheral vasodilation after injury. This article evaluated a case with unusual tachycardia and shock after trauma in which pulse steroid therapy with inotropic support was successful.

CASE: A 39-year-old man was brought to the emergency department after a traffic accident. Radiological examination revealed multiple fractures of both ribs, lumbar spine, and pelvis, also a hematoma in the spleen. A splenectomy was performed, and the tear in the diaphragm was repaired. A tube was inserted due to hemothorax. Five units of erythrocyte suspension and three units of fresh frozen plasma were intraoperatively administered. The orthopedist applied a pelvic pressure hammock to the pelvis. After eight hours, tachycardia of 204/min occurred, and blood pressure decreased to 50/30 mmHg. Inotropic support (norepinephrine 0.05 mcg/kg/min, adrenaline 0.5 mcg/kg/min, dobutamine 5 mcg/kg/min) was administered. The hemoglobin level, whose baseline was 9.3 g/dL, was 9.1 g/dL. Abdominal ultrasound did not reveal any hemorrhage. The ECG and troponin findings ruled out acute myocardial infarction. No tamponade and atrial dilation were detected. Although without bradycardia, neurogenic shock was considered. Methylprednisolone (30 mg/kg in 1 hour, 23-hour infusion at 5.4 mg/kg) was administered. At the 48th hour, inotropic support therapy was gradually discontinued. He was extubated and transferred to the service.

DISCUSSION - CONCLUSION: Although hypovolemia did not occur in the case presented here, extreme tachycardia and shock were observed. The causes of tachycardia and shock can vary in patients with SCI. After ruling out common causes of shock with tachycardia in the ICU, it should be considered that autonomic dysfunction and impaired heart rate variability may cause different tachycardias/ tachyarrhythmias, and steroid therapy should be reviewed.

Keywords: spinal cord injury, tachicardia, neurogenic shock, prednisolone

Pub No: O-026

Bilateral Costoclavicular Block Catheter İn Frozen Shoulder Surgery: A Case Report

Serdar Yeşiltaş[1], Emine Şeyda Teloğlu[1]

[1]Bezmialem Vakıf Üniversity

INTRODUCTION - PURPOSE: Effective postoperative analgesia in shoulder surgeries has been associated with a reduction in adhesion, capsule retraction, and intra-articular fibrous tissue deposition (1). Interscalene block is the gold standard method for postoperative analgesia in shoulder surgeries. Unfortunately, ISB often results in ipsilateral hemidiaphragm paralysis, which limits its use in bilateral applications. It has been reported that infraclavicular block applied with the costoclavicular approach (CCB) provides analgesia equivalent to ISB, but the risk of hemidiaphragm paralysis is quite low. We aimed to present our continuous CCB in a patient who underwent bilateral arthroscopic arthrolysis for frozen shoulder

CASE: A 52-year-old ASA-2 female patient underwent bilateral shoulder arthroscopic arthrolysis under general anesthesia. Postoperatively, linear USG probe was placed under the clavicle just medial to the coracoid process. After the 18G Tuohy needle was advanced in the plane from the lateral border and its position was confirmed by hydrodissection, the catheter was placed by applying 10 ml of 0.25% bupivacaine. Bupivacaine (0.125%) was administered bilaterally at 0.25 mL/kg bolus and 0.1 ml/kg/hour infusion dose. . Diaphragm paralysis was evaluated using B mode and M mode at the 5th, 15th, and 30th minutes with an USG probe placed in the parasagittal orientation on the left anterior axillary and right mid-clavicular line and costal margin. Complete or partial diaphragmatic paralysis was not observed. In the postoperative period, the patient's resting and movement VAS values were measured as 2, the highest value in the first 72 hours.

Picture 1



USG probe and needle placement in costoclavicular block

Picture 2

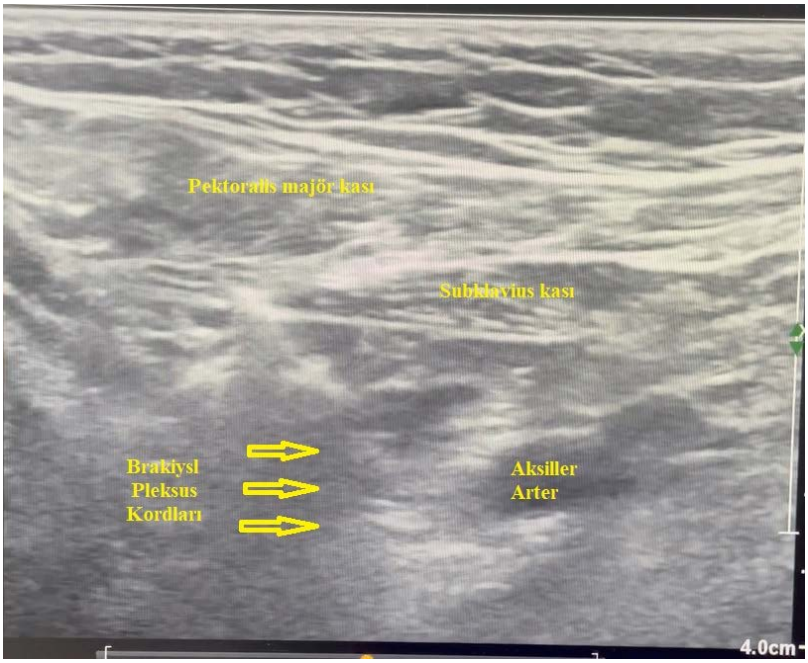

USG image of costoclavicular block and drug distribution

Picture 3



Costoclavicular catheter placement

DISCUSSION - CONCLUSION: In the patient who underwent arthroscopic arthrolysis, we provided effective analgesia without diaphragmatic paralysis with postoperative bilateral CCB application. We think that USG-guided CCB is an important potential analgesic method in bilateral shoulder surgeries as well as being safe. Although the risk of diaphragmatic paralysis is low in CCB, it is important to closely monitor especially patients with severe respiratory disease.

Keywords: diaphragm-sparing brachial plexus nerve block, frozen shoulder, interscalene block, costoclavicular block

Pub No: O-027

Return To Life With Ecmo And Cabg After Two Hours Of Cardioopulmonary Resusitation

Esra Adıyeke[1], Ayşe Hilal Meriç[1], Selda Tekin[1], Nilüfer Coşkun[1], Yücel Özen[1], Murat Uğur[1], Nurten Bakan[1]

[1]sancaktepe martyr prof.dr.ilhan varank education and research hospital

INTRODUCTION - PURPOSE: In this case report,we wanted to share the process after a friend of ours who was an internist at our hospital had chest pain on the way to work,came to the emergency room by car,and was arrested.

MATERIALS AND METHODS: 41year-old male patient came to the emergency room with sudden onset chest pain.Arrest at the door and CPR was started immediately,he was taken to the angio unit and thrombus was detected in the LAD and a stent was inserted,he was arrested again,It was detected that the stent was occluded in the angiography.Aggressive antithrombolytic therapy was administered.Response was obtained ECMO cannulation to a total of 120 minutes of resuscitation.Emergency CABG decision was made in the working heart.After the development of tamponade in the patient with active bleeding secondary to antithrombolytic therapy in the postoperative intensive care unit follow-up,she was revised 4times.DIC secondary to massive blood transfusion occurred.In the intensive care follow-up, a total of nearly 100u of blood and blood products were replaced.Compartment syndrome developed due to circulatory disorder in the right leg in the patient who was cannulated from the right femoral vein and femoral artery, fasciotomy was done.Hemodiafiltration was started in the patient whose CK increased and GFR decreased.Patient weaned from ECMO on postoperative day 4.Sepsis developed and antibiotic therapy was administered. On the 10th day, his sedation was reduced and cooperated on the 12th day. On the 19th day of the follow-up, tracheostomy was opened and respiratory physiotherapy was started.Decannulated on the 40th day of follow-up.The patient was transferred to the service on the 45th day and was discharged 2months later with GCS 15,EF 47%, and moderate loss of function(muscle atrophy) in the lower leg.He returned to work 4months later.

RESULTS: Effective and prolonged CPR should be performed in young patients with acute MI and arrest,all possibilities should be used.

DISCUSSION - CONCLUSION: .

Keywords: CABG, CPR, MI

Pub No: O-028

Post-Coronary Restenosis After Rectal Malignancy Surgery Anesthesia In A Patient Who Had MI Three Weeks Ago

Harun ÖZMEN[1], Bahar AYDINLI[1]

[1]MERSİN CITY HOSPITAL

INTRODUCTION - PURPOSE: Introduction-Aim: Morbidity increases in the early stages of myocardial damage, malignancy and severe infection. In this case, we will share our anesthesia experience in a patient with rectal malignancy, and low-anterior resection; who had MI 3 weeks ago, and performed coronary angiography, balloon dilatation, stenting.

CASE: Case: In the preoperative visit of the patient, it was learned that he had presented with myocardial infarction 3 weeks ago. PTCA+stent was applied to the LAD and RCA during angiography in a 53-year-old male patient with known Type 2 DM and hypertension. Before the patient was discharged ecopirin, metoprolol, ticogrelor, atorvastatin were started. In the second week colonoscopy was performed in the patient because of hematochezia. In his biopsy, advanced dysplasia, strong possibility of invasion were reported. Tikogrelor was stopped and enoxaparine was started. Propofol, rocuronium bromide, remifentanil were administered to the patient and then ETE was performed. Anesthesia was maintained with 02 +N20+sevoflurane+ remifentanil. On the second day, the troponin level increased to 132,500 . Reconstructed angiography revealed total occlusion of the stented LAD, and a stent was inserted after balloon dilatation. Troponin decreased to 61,590 in the patient who was followed up with added ticagrelor.

DISCUSSION - CONCLUSION: Discussion: The timing of noncardiac surgery is associated with morbidity and mortality in patients with acute coronary syndrome who underwent percutaneous revascularization. Reinfarction 37% and mortality up to 70% are reported in these patients. Switching to bridge therapy with LMW heparin for anticoagulation before major surgery, and presence of hypertension and diabetes, as in our patient, were factors that increased the risk . It was thought that coagulation and hyperactivation by major surgery may have been effective in the reocclusion of the vessel.Result: Ensuring cardiovascular stability, regulation of anticoagulation, and close cardiological follow-up are important for patients with a recent myocardial infarction.

Keywords: myocardial infarction, malignancy, general anesthesia

Pub No: O-029

Thromboelastometry Guided Hemostatic Management of a Syndromic Patient After Congenital Heart Surgery

Selin Sağlam[1], İncila Ali Kahraman[1], Funda Gümüş Özcan[1]

[1]Başakşehir Çam ve Sakura Şehir Hastanesi

INTRODUCTION - PURPOSE: Noonan syndrome (NS) ('Turner-like' syndrome) is an autosomal dominant genetic disorder. Most people with NS have unusual facial features, heart defects and bleeding problems. In this case, we present a pediatric patient with NS and hemostatic management with the rotational thromboelastography (ROTEM®) after left ventricular outflow obstruction (LVOTO) surgery.

CASE: A 2-year-old male child who has NS admitted to pediatric cardiovascular unite for LVOTO surgery (Picture 1). He was diagnosed with hypertrophic cardiomyopathy in his postnatal examination due to respiratory distress. He also had a surgery before for bilateral undescended testicles and needed platelet transfusion after that operation. His mother was told that his platelet counts were adequate but he might have platelet disfunction because of his syndrome. Before the LVOTO surgery, in his CBC, platelet count was 246,000/mm3 and first ACT in the operating room was 158 seconds. In the surgery, 350 u/kg heparin was administered and the patient was successfully operated with cardiopulmonary bypass. After he was off cardiopulmonary bypass, protamine was administered and ACT measured as 152 seconds. The patient was also given 30 cc of cryoprecipitate, however, the bleeding continued, so we decided to manage the transfusion guided by ROTEM® (Picture 2). In EXTEM, A5 (the clot firmness at 5 min) was low (19 mm). That suggested a problem with fibrinogen or platelet function. In FIBTEM, A5 (amplitude at 5 min) was > 9 mm (10 mm), so we thought there was thrombocyte dysfunction, not hypofibrinogenemia. So the patient was given 10 ml/kg pooled platelet suspension, and the bleeding was instantly under control.

Picture 1



Picture 2



DISCUSSION - CONCLUSION: ROTEM® is a diagnostic tool that shows the functionality of the clot. We suggest that ROTEM® may be considered for hemostatic management when faced with dilemmas after congenital heart surgery, especially if the patient has a rare genetic syndrome that may cause bleeding disorders.

Keywords: hemostasis, congenital heart surgery, noonan syndrome, pediatric anesthesia, thromboelastometry

Pub No: O-030

Gender distribution of editorial board members in anesthesiology journals: assessment of gender parity

Mehmet Nuri Yakar[1], Duygu Bilge[2], Nurgazy Shermatov[2], Merve Oltulu[2], Volkan Hancı[1]

[1]Division of Intensive Care, Department of Anaesthesiology and Reanimation, Faculty of Medicine, Dokuz Eylül University, İzmir, Turkey
[2]Department of Anaesthesiology and Reanimation, Faculty of Medicine, Dokuz Eylül University, İzmir, Turkey

INTRODUCTION - PURPOSE: Gender disparity is a crucial matter in different fields of medicine (1-3) and persists in anesthesiology (4, 5). However, gender diversity on editorial boards of anesthesiology journals remains unclear. A greater understanding of this issue may improve the policies targeting gender parity. This cross-sectional study aims to analyze the gender distribution of editorial board members of anesthesiology journals and reveal independent factors related to gender diversity.

MATERIALS AND METHODS: The local ethics committee of Dokuz Eylül University approved the study (Date:31.08.2022 and nubmber:2022/28-08). Editorial board members of the anesthesiology journals indexing in Web of Science, Science Citation Index-Expanded core collection were enrolled in the study. Participants' genders were defined according to first names/pictures obtained from journals' websites between 01 and 20 October 2022. Publisher properties and journal metrics were also recorded. Chi-square, Fisher exact, Mann–Whitney U tests, and Pearson's correlation coefficient were used for the analysis. Independent factors related to gender diversity were revealed by using logistic regression analysis.

Figure 1. Flowchart of the study

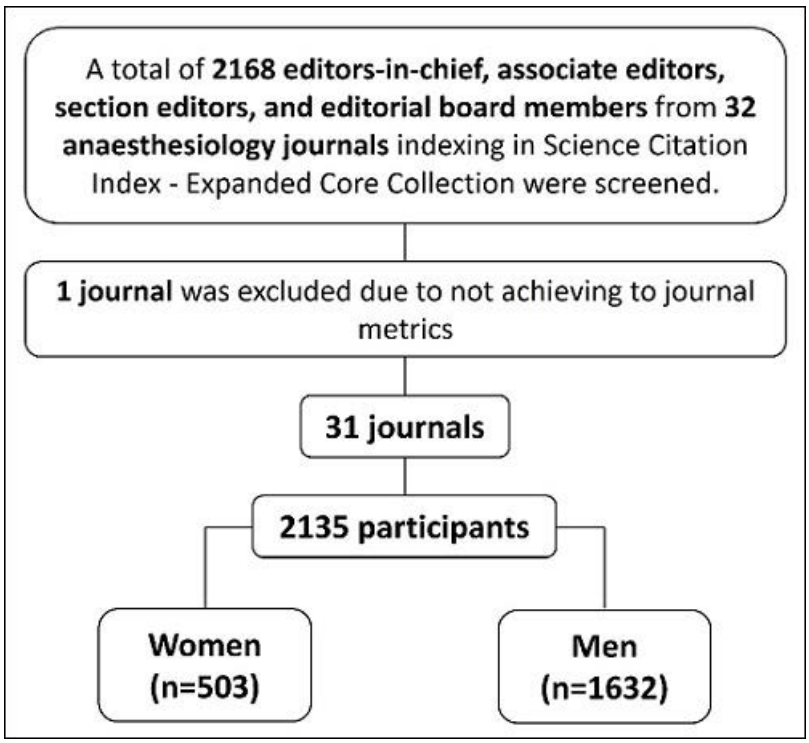

RESULTS: Women's representation on editorial boards and among editors-in-chief were 23.6% (n=503) and 2.7% (n=1), respectively. The Web of Science Coverage Category of Neurosciences (Odds ratio [OR], 0.52, 95% confidence interval [CI], 0.36–0.75, $p < 0.001$), the UK as a publisher country (OR, 0.68, 95% CI, 0.51–0.90, $p = 0.007$), Canada as a journal country (OR, 0.45, 95% CI, 0.21–0.99, $p = 0.046$), and Cataloging and Classification Quarterly category of Q1 (OR, 0.52, 95% CI, 0.31–0.86, $p = 0.011$) were independently related to gender parity. Conversely, the uni-disciplinary perspective of editorial board policy was independently related to gender disparity (OR, 1.34, 95% CI, 1.03–1.73, $p = 0.028$).

Table 1. The catalog info, publication properties, and metrics of the journals

Journals	Country		Primary Language	CCQ	IF	IF (5-year)	H-index*	H-index* (5-year)	Publication counts*	
	Journal	Publisher							PubMed	WoS
Pain	USA	USA	English	Q1	7.926	8.085	-	49	11468	11541
Canadian Journal of Anesthesia	Canada	USA	English	Q1	6.713	5.304	103	31	8894	9202
Pain Medicine	USA	UK	English	Q2	3.637	3.721	103	32	4984	5210
International Journal of Obstetric Anesthesia	UK	UK	English	Q3	3.282	2.959	53	19	2590	2491
European Journal of Pain	UK	USA	English	Q2	3.651	4.169	113	31	3220	3331
Pediatric Anesthesia	UK	USA	English	Q4	2.129	2.349	80	22	6062	6253
Anaesthesia	UK	UK	English	Q1	12.893	9.217	-	50	20445	26468
British Journal of Anaesthesia	UK	UK	English	Q1	11.719	9.872	-	55	20410	23867
Schmerz	Germany	Germany	German	Q4	1.629	1.306	42	10	2329	2003
Perioperative Medicine	UK	UK	English	Q3	2.904	3.516	28	14	308	311
Anaesthesia and Intensive Care	Australia	UK	English	Q4	1.512	1.709	69	13	7070	7377
Clinical Journal of Pain	USA	USA	English	Q2	3.423	4.228	128	28	3148	3234
Current Opinion in Anesthesiology	USA	USA	English	Q3	2.733	2.971	69	24	2755	2039
Anesthesia and Analgesia	USA	USA	English	Q1	6.627	6.041	-	52	26911	37185
Journal of Neurosurgical Anesthesiology	USA	USA	English	Q2	4.010	2.974	63	18	2114	2114
Brazilian Journal of Anesthesiology	Brazil	USA	English	Q3	1.098	N/A	4	4	1222	276
Anaesthesia Critical Care & Pain Medicine	France	France	English	Q1	7.025	4.713	31	27	1114	1100
Regional Anesthesia and Pain Medicine	UK	UK	English	Q2	5.564	6.643	101	35	3958	4063
Anesthesiology	USA	USA	English	Q1	9.198	8.832	-	35	24707	34132
Acta Anaesthesiologica Scandinavica	Denmark	USA	English	Q4	2.274	2.423	-	22	9080	10903
Journal of Cardiothoracic and Vascular Anesthesia	USA	USA	English	Q3	2.894	2.495	80	32	9133	7974
Journal of Clinical Anesthesia	USA	USA	English	Q1	9.375	5.013	72	31	6425	6210
BMC Anesthesiology	UK	UK	English	Q3	2.376	2.583	41	24	2213	2127
Korean Journal of Anesthesiology	South Korea	South Korea	English	Q2	5.167	4.000	34	22	2292	1970
Pain Physician	USA	USA	English	Q2	4.396	4.157	90	32	2670	2194
Pain Practice	USA	USA	English	Q3	3.079	3.098	56	21	1705	1390
Minerva Anestesiologica	Italy	Italy	English	Q3	3.396	2.888	58	21	9922	3288
Best Practice & Research-Clinical Anaesthesiology	UK	Holland	English	Q2	3.813	3.855	65	18	944	814
Journal of Clinical Monitoring and Computing	Gernamny	Germany	English	Q4	1.977	1.935	43	20	2231	1966
European Journal of Anaesthesiology	UK	USA	English	Q2	4.183	5.000	76	29	5470	8369
Journal of Anesthesia	Japan	Japan	English	Q3	2.931	2.363	46	18	4048	2645

Abbveriations: IF, impact factor; CCQ, cataloging and classification quarterly; WoS, Web of Science; USA, United States of America; UK, United Kingdom. *Calculated for the journals with less than ten thousand publications on the day of November 1, 2022. †Recorded on the day of November 1, 2022.

Table 2. Gender distribution on the journals' editorial boards and of editors-in-chief

Journals	Editorial board		Editor-in-chief		
	Women (n=502)	Men (n=1596)	Number (n=37)	Women (n=1)	Men (n=36)
Pain	45 (40.5)	66 (59.5)	1	0	1
Canadian Journal of Anesthesia	12 (40.0)	18 (60.0)	1	0	1
Pain Medicine	46 (35.4)	84 (64.6)	3	0	3
International Journal of Obstetric Anesthesia	13 (34.2)	25 (65.8)	1	0	1
European Journal of Pain	32 (34.0)	62 (66.0)	1	0	1
Pediatric Anesthesia	24 (30.8)	54 (69.2)	1	0	1
Anaesthesia	11 (30.6)	25 (69.4)	1	0	1
British Journal of Anaesthesia	19 (28.4)	48 (71.6)	1	0	1
Schmerz	7 (28.0)	18 (72.0)	2	0	2
Perioperative Medicine	15 (27.3)	40 (72.7)	2	0	2
Anaesthesia and Intensive Care	6 (26.1)	17 (73.9)	1	0	1
Clinical Journal of Pain	13 (26.0)	37 (74.0)	1	0	1
Current Opinion in Anesthesiology	9 (25.0)	27 (75.0)	2	0	2
Anesthesia and Analgesia	42 (24.4)	130 (75.6)	1	0	1
Journal of Neurosurgical Anesthesiology	9 (24.3)	28 (75.7)	1	0	1
Brazilian Journal of Anesthesiology	27 (23.5)	88 (76.5)	1	0	1
Anaesthesia Critical Care & Pain Medicine	15 (23.4)	49 (76.6)	1	0	1
Regional Anesthesia and Pain Medicine	19 (23.2)	63 (76.8)	1	0	1
Anesthesiology	13 (20.6)	50 (79.4)	1	0	1
Acta Anaesthesiologica Scandinavica	5 (20.0)	20 (80.0)	1	0	1
Journal of Cardiothoracic and Vascular Anesthesia	35 (19.9)	141 (80.1)	1	0	1
Journal of Clinical Anesthesia	11 (19.6)	45 (80.4)	1	0	1
BMC Anesthesiology	30 (18.0)	137 (82.0)	1	0	1
Korean Journal of Anesthesiology	10 (15.6)	54 (84.4)	2	1	1
Pain Physician	19 (14.4)	113 (85.6)	1	0	1
Pain Practice	9 (13.2)	59 (86.8)	1	0	1
Minerva Anestesiologica	2 (8.3)	22 (91.7)	1	0	1
Best Practice & Research-Clinical Anaesthesiology	1 (6.7)	14 (93.3)	1	0	1
Journal of Clinical Monitoring and Computing	3 (6.0)	47 (94.0)	1	0	1
European Jounral of Anaesthesiology	1 (4.2)	23 (95.8)	1	0	1
Journal of Anesthesia	0 (0.0)	28 (100.0)	1	0	1

All values are expressed as numbers (percentages)

Table 3. Factors related to gender distribution in editorial boards of the journals

Journal metrics and publication properties	All (n=2135)	Gender distribution		*p* value
		Women (n=503)	Men (n=1632)	
The role of editor				
Editor-in-chief	36 (1.7)	1 (0.2)	35 (2.1)	**0.001**
Associate editor	91 (4.3)	17 (3.4)	74 (4.5)	0.31
Section editor	234 (11.0)	50 (9.9)	184 (11.3)	0.46
Editorial board member	1774 (83.1)	435 (86.5)	1339 (82.0)	**0.021**
Publisher's country				
United States of America	1269 (59.4)	307 (61.0)	962 (58.9)	0.44
United Kingdom	598 (28.0)	159 (31.6)	439 (26.9)	**0.041**
Germany	75 (3.5)	10 (2.0)	65 (4.0)	**0.037**
South Korea	64 (3.0)	10 (2.0)	54 (3.3)	0.14
France	62 (2.9)	14 (2.8)	48 (2.9)	1.00
Japan	28 (1.3)	0 (0.0)	28 (1.7)	**0.001**
Italy	24 (1.1)	2 (0.4)	22 (1.3)	0.09
Netherlands	15 (0.7)	1 (0.2)	14 (0.9)	0.22
Journal's country				
United States of America	1033 (48.4)	252 (50.1)	781 (47.9)	0.39
United Kingdom	656 (30.7)	165 (32.8)	491 (30.1)	0.25
Brazil	115 (5.4)	27 (5.4)	88 (5.4)	1.00
Germany	75 (3.5)	10 (2.0)	65 (4.0)	**0.037**
South Korea	64 (3.0)	10 (2.0)	54 (3.3)	0.14
France	62 (2.9)	14 (2.8)	48 (2.9)	1.00
Canada	30 (1.4)	12 (2.4)	18 (1.1)	**0.048**
Japan	28 (1.3)	0 (0.0)	28 (1.7)	**0.001**
Denmark	25 (1.2)	5 (1.0)	20 (1.2)	0.82
Italy	24 (1.1)	2 (0.4)	22 (1.3)	0.09
Australia	23 (1.1)	6 (1.2)	17 (1.0)	0.81
Publisher's continent				
America	1305 (61.1)	318 (63.2)	987 (60.5)	0.27
Europe	738 (34.6)	175 (34.8)	563 (34.5)	0.92
Asia	92 (4.3)	10 (2.0)	82 (5.0)	**0.002**
Journal's continent				
America	1178 (55.2)	291 (57.9)	887 (54.4)	0.18
Europe	842 (39.4)	196 (39.0)	646 (39.6)	0.84
Asia	92 (4.3)	10 (2.0)	82 (5.0)	**0.002**
Australia	23 (1.1)	6 (1.2)	17 (1.0)	0.81
Primary language				
English	2110 (98.8)	496 (98.6)	1614 (98.9)	0.64
German	25 (1.2)	7 (1.4)	18 (1.1)	0.64
Impact factor (2021)	3.637 (2.894-6.627)	3.651 (2.894-6.713)	3.637 (2.773-6.627)	**0.017**
5-year impact factor	4.000 (2.583-6.041)	4.157 (2.959-6.041)	4.000 (2.583-5.304)	**0.001**
H-index	72 (41-90)	80 (41-103)	69 (41-90)	**0.001**
5-year H-index	31 (22-32)	31 (22-35)	31 (22-32)	**0.003**
Publication count				
Web of Science	4063 (2127-7974)	5210 (2127-11541)	3331 (2114-7974)	**0.001**
PubMed	3958 (2231-9133)	4984 (2329-11468)	3958 (2213-9133)	**0.005**

Publication duration, years	34 (22-50)	33 (22-69)	34 (22-50)	0.29
CCQ				
Q1	599 (28.1)	168 (33.4)	431 (26.4)	**0.003**
Q2	628 (29.4)	150 (29.8)	478 (29.3)	0.82
Q3	707 (33.1)	140 (27.8)	567 (34.7)	**0.004**
Q4	201 (9.4)	45 (8.9)	156 (9.6)	0.73

All values are expressed as number (percentages) or median (interquartile range).
Abbveriations: CCQ, cataloging and classification quarterly

Table 4. Web of Science Coverage Categories of the Journals

The category and disciplinarity of the journals		**Gender distribution**		
	All (n=2135)	**Women (n=503)**	**Men (n=1632)**	***p* value**
Web of Science Coverage Category				
Anesthesiology (only)	1030 (48.2)	213 (42.3)	817 (50.1)	**0.003**
Critical Care Medicine	111 (5.2)	23 (4.6)	88 (5.4)	0.57
Clinical Neurology	517 (24.2)	134 (26.6)	383 (23.5)	0.15
Neurosciences	205 (9.6)	77 (15.3)	128 (7.8)	**< 0.001**
Obstetrics & Gynecology	38 (1.8)	13 (2.6)	25 (1.5)	0.12
Cardiac & Cardiovascular Systems	176 (8.2)	35 (7.0)	141 (8.6)	0.27
Peripheral Vascular Diseases	176 (8.2)	35 (7.0)	141 (8.6)	0.27
Respiratory Systems	176 (8.2)	35 (7.0)	141 (8.6)	0.27
Surgery	92 (4.3)	24 (4.8)	68 (4.2)	0.53
Medicine, General & Internal	130 (6.1)	46 (9.1)	84 (5.1)	**0.002**
Pediatrics	78 (3.7)	24 (4.8)	54 (3.3)	0.14
Disciplinarity of the editorial board				
Uni-disciplinary	1030 (48.2)	213 (42.3)	817 (50.1)	**0.003**
Multidisciplinary	1105 (51.8)	290 (57.7)	815 (49.9)	**0.003**

All values are expressed as number (percentages) or median (interquartile range).

Table 5. Logistic regression analysis for independent factors related to gender diversity on editorial boards of anesthesiology journals

Factors related to gender diversity	OR (95% CI)	*p* value
Web of Science Coverage Category		
Neurosciences	0.52 (0.36-0.75)	**< 0.001**
Medicine, General & Internal	0.67 (0.42-1.06)	0.09
Publisher country		
UK	0.68 (0.51-0.90)	**0.007**
Germany	1.46 (0.73-2.93)	0.28
Journal country		
Canada	0.45 (0.21-0.99)	**0.046**
Cataloging and Classification Quarterly		
Q1	0.52 (0.31-0.86)	**0.011**
Uni-disciplinary perspective of editorial policy	1.34 (1.03-1.73)	**0.028**
Being an editorial board member	0.77 (0.57-1.02)	0.07
Publication metrics		
2021-year-IF	1.05 (0.96-1.14)	0.29
5-year H index	1.00 (0.99-1.02)	0.81

Abbreviations: OR, odds ratio; UK, United Kingdom; IF, impact factor.

DISCUSSION - CONCLUSION: The study revealed an under-representation of women on anesthesiology journals' editorial boards, especially in leadership positions. Further efforts are needed to expand diversity policies to foster fair conditions for all anesthesiology professionals.

Keywords: Anesthesiology, Diversity, Gender, Gender disparities, Gender parity

Pub No: O-031

General Anesthesia Management In A Patient With Brugada Syndrome

Fulya Yılmaz[1], Rojin Dağ[1], Aysun Kar[1]

[1]University of Health Sciences Izmir Bozyaka Training and Research Hospital Department of Anesthesiology and Reanimation

INTRODUCTION - PURPOSE: Brugada Syndrome is an autosomal dominant inherited cardiac rhythm dysfunction that can lead to lethal tachyarrhythmias. It was first described in 1992. Diagnosis is based on ECG. Although the prevalence is low (0.005/1000), the patients have numerous potential triggers (Anxiety, drugs, fever). The pathophysiology is still not fully understood. The treatment is a pharmacological or non-pharmacological approach (Automatic implantable cardioverter defibrillator). Despite the lack of evidence that propofol leads to arrhythmogenicity due to sodium channel-blocking properties; cardiologists recommend avoiding propofol. On the other hand in the literature, there are case reports and case series that were successfully managed either with propofol induction and maintained with inhalation anesthesia or with intravenous anesthesia. Here in we describe a case who was managed successfully without any complications under general anesthesia.

CASE: A 49-year-old woman (160 cm,75 kg) was presented for septorhinoplasty. She had no medical history except Brugada Syndrome and she was under cardiologist follow-up without any medication. Her preoperative laboratory test results and chest radiography were within normal limits. After routine monitorization, a continuous infusion of remifentanil was started and anesthesia was induced with lidocaine 60mg, propofol 150mg, and rocuronium 60mg intravenously. The patient's trachea was intubated and volume-controlled mechanical ventilation was started with 5-7 mL tidal volume. Anesthesia was maintained with desflurane 4-6 vol%, oxygen in the air (FiO2:0.40), and a continuous infusion of remifentanil. Respiratory rates were adjusted to maintain an end-tidal CO2 between 35-40 mmHg. The surgical time was 180 minutes. Hemodynamic parameters were within the normal range perioperatively and we did not encounter any arrhythmia perioperatively. Then the patient was extubated uneventfully after antagonization of muscle relaxation with sugammadex. She was discharged from the hospital on the first day of surgery.

DISCUSSION - CONCLUSION: For safe anesthetic care of these patients, a thorough understanding of medications and multidisciplinary team consideration is crucial.

Keywords: General anesthesia, Brugada syndrome

Pub No: O-032

The Case Of Difficult Extubation After Bleeding Pediatric Tonsillectomy

Özlem DELIGÖZ[1]

[1]UNIVERSITY OF HEALTH SCIENCES, HAYDARPAŞA NUMUNE TRAINING AND RESEARCH HOSPITAL, ISTANBUL, TURKEY

INTRODUCTION - PURPOSE: Adeno-tonsillectomy surgery is frequently performed in children,and bleeding after surgery isn't negligible(1).Postoperative bleeding complicates intubation and extubation.Laryngospasm,upper airway edema,hematoma,secretions,tracheomalacia,tracheal collapse are among the causes of extubation failure(2).In this report,we would like to share the experience of a patient who exhibited bleeding after adeno-tonsillectomy,and was re-operated,and couldn't be extubated due to severe laryngospasm.Written informed consent was obtained for the case report.

CASE: A 7-year-old,24/kg,ASA I,adeno-tonsillectomy operation.Induction:30micrograms/intravenous(iv)/Fentanyl,90mg/iv/propofol and 15mg/iv/rocuronium.The patient was easily,and successfully orotracheally intubated(OTE) with a number 5.0spiral intubation tube.Methylprednisolone 20mg/iv was administered prophylactically.The patient was extubated without any complications,and was transferred to ward.The patient was urgently re-operated one hour after leaving the operating room due to active bleeding from the tonsillectomy site.The patient was preoxygenated with 100% oxygen in lateral position.Induction:25micrograms/iv/Fentanyl, 80mg/iv/propofol,and 20mg/iv/rocuronium without ventilation.OTE was performed easily,and successfully with a number 5.0spiral intubation tube in the first attempt.On direct laryngoscopy,laryngeal appearance was normal.After surgery 50mg/iv/bridion was administered.When the patient's reflexes returned,and spontaneous breathing became stronger,the tube cuff was lowered for extubation.The tube didn't come out despite a strong tug.40 mg/iv/prednol and 1mg/iv/midazolam and 50 mg/iv/propofol were administered.100% oxygen support was continued.A cuff check was carried out.After 5 minutes,extubation was reattempted but the tube did not move.Video lagengoscope showed that the larynx was tightly wrapped around the intubation tube.There was no edema in the laryngeal region.In the 25th minute,the tube slipped out without difficulty.During this period,the patient's saturation value didn't fall below 100.The patient was taken to intensive care unit with mask oxygen support,and oriented,and cooperative.The patient had no complications except hoarseness.

DISCUSSION - CONCLUSION: Larygospasm(partial/complete) is a common perioperative airway complication in pediatric patients.When laryngospasm develops,100% oxygen should be provided and iv/propofol should be administered(3,4).Extubation shouldn't be performed before making sure that the spasm has resolved.Experienced team,and availability of necessary equipment are the most important points in reducing morbidity due to these complications.

Keywords: Tonsillectomy, Pediatric, Bleeding, Larygospasm, Difficult Extubation.

Pub No: O-033

Which Insulin Regimen Intraoperatively In Type 2 Diabetic Patients

Nilufer Coşkun[1] , Nursen Koltka[2], Melek Güra Çelik[2]

[1]Şehit Prof Dr İlhan Varank Sancaktepe EAH

[2]Medeniyet univ. Göztepe EAH

INTRODUCTION - PURPOSE: In our study we aimed to compare two different insulin regimens for ensuring glycemic control in patients who have Type 2 Diabetes Mellitus (DM) undergoing elective thyroidectomy.

MATERIALS AND METHODS: Patients were randomly divided into 2 groups;Group I (n=30): 0.5 Ü/h crystalize insulin infusion have started. Infusion rate arranged as to keep the target blood sugar between 80-180 mg/dl during the operation.Group K (n=30): Sustained as control group and bolus 4 U crystalize insulin for every 50 mg/dl in patients blood sugar above >250 mg/dl applied. 2 hours before the operation, blood glucose was measured in all patients. During the operation at intervals of 1 hour, after the operation 2.,4. and at the 6th hour, blood glucose was measured and recorded in all patientsHeart rate (HR), systolic artery pressure (SAP) and diastolic artery pressure (DAP) are measured and recorded after intubation,10. 20. 30. minutes and 1 and 2. hours intraoperatively.

RESULTS: Group I all blood sugar values are statistically lower than before the operation measurements ($p < 0.05$). As to in Group K blood sugar values at intraoperative 60. min and 90. min were higher than preoperative measurement, postoperative 4. and 6. hour measurement were significantly lower than preoperative blood sugar values, there were not any difference among the other measurements ($p<0.05$)

Blood sugar measurements according to the groups

Figure 1: Blood sugar measurements according to the groups

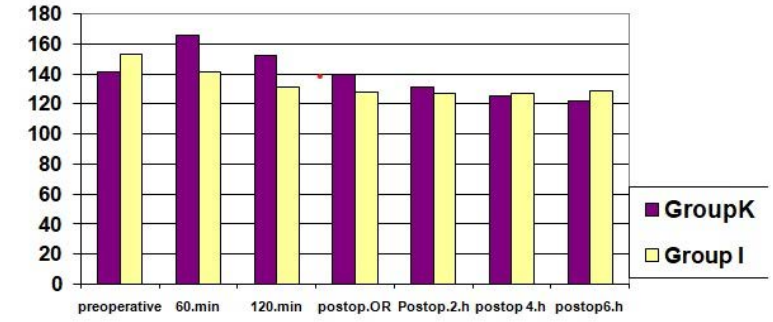

*p<0,05, **p<0,01, ***p<0,001staristically meaningful

*p<0,05 in comparison among preoperative blood sugar measurements

Distribution of cases regarding age, weight, duration of diabetes and operation, HbA1c

		Group K		Gorup İ		
		Mean	SD	Mean	SD	p
Age (years)		57,06	13,294	59,97	11,760	,371
weight (kg)		75,80	14,21	78,80	11,55	,810
Duration of Diabetes (years)		3,75	2,95	8,85	8,98	,134
Gender	Female	13	5,75	16	8,20	,756
	Male	17	7,88	14	6,01	,342
Operation duration		155,5	33,21	160	35,22	,187
HbA1c		7,47	1,22	7.65	1.58	,651

Comparison of Group I and Group K blood sugar values intergroup and within groups.

	Group K		Group İ		
	Mean	SD	Mean	SD	p
2 hours before the operation	140,97	50,666	153,17	44,994	,325
60.min.	165,84	75,611	141,63	49,677	,146
120.min	152,35	56,170	131,47	33,844	,085
Post op.Operation room	139,32	46,414	128,00	29,740	,263
Post op 2.h	131,26	32,368	127,13	28,159	,598
Postop 4.h	125,55	30,169	127,17	26,646	,825
Postop 6.h	121,97	26,399	128,57	29,578	,361

DISCUSSION - CONCLUSION: Intraoperative blood sugar regulation obtained with both two insulin regimens (Bolus and Infusion). Nevertheless continuous insulin infusion seems more advantageous in our opinion.

Differentiation Consumed insulin amounts and duration of hospital stays

	Group K		Group I		
	Mean	SD	Mean	SD	p
Insulin (U)consumption	25	2,03	7,5	0,05	,0005*
Hospital stay (days)	7,9	1,05	8,1	2,05	,453

Keywords: Diabetes Mellıtus, Insulin, General Anaesthesia, Intraoperative

Pub No: O-034

Intensive Care Experience In Two Cases With Imported Malaria

Alev Öztaş[1], Derful Gülen[1], Güldem Turan[1]

[1]University of Health Sciences, Basaksehir Cam and Sakura City Hospital, Intensive Care Unit, Istanbul

INTRODUCTION - PURPOSE: Malaria is one of the most common causes of severe imported infections in nonendemic areas. Plasmodium falciparum malaria has a more severe course and with mortality rate of approximately 1%. These patients require the follow-up of in intensive care units (ICU) due to respiratory failure, cerebral malaria, acute kidney injury (AKI). We aimed to share our experiences in two patients followed up in the ICU for Plasmodium falciparum malaria.

CASE: Case-1: 30year-old male patient was admitted to hospital because of diarrhea lasting for five days. He had returned from Tanzania 10 days ago. He had poor general condition, sepsis, AKI and was admitted to the ICU with the diagnosis of falcifarum malaria. Laboratory findings; urea62mg/dL, creatinine2.28 mg/dL, crp 172mg/L, procalcitonin 53ng/mL, glucose 60mg/dL, Na122mEq/L, Cl 85mEq/L, P0.57mg/dL, Mg1.5mg/dL, plt 16.109/L, pH 7.40, PCO2 31, PO2 90, lac 3, HCO3 19. No parasite was detected in the peripheral smear of the patient who was treated with Artesunate 3 days later. The patient, whose clinical and laboratory findings improved, was transferred to the service 5 days later. Case-2: 22-year-old male patient was intubated from Mauritania with the diagnosis of falcifarum malaria and COVID-19. Poor general condition, unconscious, pH:7.27, urea 137mg/dL, creatinine 1.4mg/dL, crp:101mg/L, procalcitonin 6ng/mL, amylase 146 U/L, lipase 258 U/L, direct bil. 2.8mg/dL, plt:38.109/L. The patient had diffuse edema in the brain and ground glass pulmonary opacity.He was administered Artesunate, Remdesivir, pulse steroid, IVIG. No parasites were detected in the peripheral smear on the fourth day of hospitalization. He was extubated on the 12th day and transferred on the 19th day.

DISCUSSION - CONCLUSION: In severe malaria, anemia, coagulation disorder, DIC, metabolic acidosis, hypoglycemia, AKI and accompanying co-infection can be seen. In fluid therapy, care should be taken for reasons such as ARDS, cerebral edema, and cardiac dysfunction, which are signs of poor prognosis.

Keywords: Imported infections, ICU, Malaria

Pub No: O-036

Transnasal Sphenopalatine Ganglion Block For Postdural Puncture Headache: A Case Series

Onur Senyurt[1], Taylan Sahin[1], Ali Sait Kavakli[1], Emine Yitgin[1]

[1]Istinye University Liv Bahcesehir Hospital

INTRODUCTION - PURPOSE: After spinal anesthesia, post-dural puncture headache (PDPH) negatively affects the quality of life, increases the duration of hospital stay or re-hospitalization. This presentation aims to present our treatment experience with sphenopalatine ganglion block (SPGB) in patients who did not respond to conservative treatment for PDPH and did not accept an epidural blood patch. Written informed consent was obtained from all patients for these case reports.

CASE: SPGB was applied to 3 female patients who underwent elective cesarean section under spinal anesthesia and 1 male patient who underwent spinal anesthesia due to medial malleolus fracture because of failure to respond to conservative treatment for PDPH. The duration of the first postoperative complaints of the patients ranged from 2-36 hours. None of the patients had any neurological symptoms other than headache. Intravenous hydration, theophylline, magnesium, oral caffeine, and non-steroid anti-inflammatory drugs were used for conservative treatment in all patients. Since there was no response to conservative treatment, SPGB was applied to the patient using lidocaine. While the complaints completely regressed with the first application in 2 female patients, the complaint completely disappeared after 48 hours in 1 female patient after the second application. Greater occipital nerve block (GONB) was performed in 1 male patient who underwent orthopedic surgery, after the application of SPGB 2 times with an interval of 24 hours. After that, the complaints completely disappeared.

DISCUSSION - CONCLUSION: Epidural blood patch is still used as one of the most effective treatment methods in patients who do not respond to conservative treatment in the treatment of PDPH. However, patients' doubt about this application constitutes the most important limitation of this treatment. For this reason, we believe that different anesthesia methods such as SPGB and GONB can be used effectively as an alternative in selected patients in the treatment of PDPH.

Keywords: Sphenopalatine ganglion bloc, Spinal anesthesia, Postdural puncture headache

Pub No: O-037

Postpartum thyroiditis coma: A Case Report

Alp Hepsev[1], Nese Kutluturk Sahin[2]

[1]Istanbul Gelisim University
[2]Spektromar Medical Imaging Center

INTRODUCTION - PURPOSE: Postpartum thyroiditis (PPT) is a thyroid dysfunction syndrome that is temporary or permanent that occurs 1 year after giving birth. The occurrence of postpartum thyroiditis is 5 – 10% of postpartum women in the world. Therefore, the symptoms in patients differ according to the period of the disease. In this presentation, we wanted to contribute to the literature by presenting a patient who developed a rare convulsion and loss of consciousness after postpartum thyroiditis.

CASE: A 30 years old woman was present at our emergency department with unconsciousness due to a generalized seizure that occurred in 2nd month of postpartum. She was intubated and transferred to ICU with a Glasgow coma scale of 7. During ICU admission the blood pressure was 230/110 mmHg, body temperature was 37.5, heart rate was 128,Free T3 was 11,24 pg/mL, Free T4 was 3,61 ng/dL, TSH was 0,048 Uıu/mL and ANTİ TPO was 796,3 IU/ml. She was diagnosed with postpartum thyroiditis after hematological tests, blood culture, cerebrospinal fluid culture and radiological tests. She was treated with propylthiouracil, dexamethasone, and beta-blocker. She was uneventful extubated on the 72th hour of consciousness after treatment.

DISCUSSION - CONCLUSION: Postpartum thyroiditis is a triphasic disease, including hyperthyroidism, hypothyroidism, and euthyroidism.Therefore, the symptoms in patients differ according to the period of the disease. Convulsion and coma after postpartum thyroiditis is a rare condition. Although very rare, this situation can lead to a fatal clinical picture. In this case report, we treated and discharged a patient who fell into a coma after postpartum thyroiditis.

Keywords: postpartum thyroiditis, coma

Pub No: O-038

Filgrastim Use in Neutropenic Patients in the Intensive Care Unit

Halide Oğuş[1]

[1]Koşuyolu Yüksek İhtisas Eğitim ve Araştırma Hastanesi

INTRODUCTION - PURPOSE: Development of neutropenia is common during immunosuppressive therapy in patients receiving intensive care. It can be life-threatening in patients who have had an organ transplant, receiving immunosuppressive therapy, or develop sepsis. In this retrospective case series, we report on 6 patients who developed neutropenia in the cardiovascular intensive care unit and were treated with filgrastim.Study approval: The study was approved by the institutional review board.

CASE: During follow-up in the intensive care unit, six patients with a neutrophil count <1500/µL (neutropenic, n=3) or <500/µL (severe neutropenic n=3) were treated with filgrastim. Clinical and laboratory parameters, filgrastim doses and durations, neutrophil, lymphocyte, white blood cell and platelet counts, and body temperatures were recorded. Neutropenia was diagnosed in six ICU patients who had been monitored after lung transplantation (n=3), coronary artery bypass grafting (n=1), and in two patients (1 postpartum) on ECMO due to Covid-19-associated ARDS. Filgrastim was administered at a dose of 30-45 million units for 1 to 7 days. Three patients had been receiving immunosuppressive therapy. Five patients had sepsis, two of whom had no increases in neutrophil counts. None of the patients developed febrile neutropenia. Mortality occurred in five patients. One postpartum patient who was on ECMO due to Covid-19-associated ARDS was discharged.

DISCUSSION - CONCLUSION: Sepsis and/or use of immunosuppressive treatments pose a high risk for severe neutropenia as well as for mortality. Early diagnosis and appropriate treatment of sepsis, and regulation of immunosuppressive treatment in a way that would not result in severe neutropenia may be important considerations to avoid adverse consequences. Treatment of neutropenia with filgrastim may not be sufficient to reverse the poor prognosis.

Keywords: filgrastim, neutropenia

Pub No: O-039

2:1 Atrioventricular Block And Asystole Under Spinal Anesthesia For Cesarean Section. A Case Report

ferdi gülaştı[1]

[1]aydın maternity and health Childs hospital

INTRODUCTION - PURPOSE: Spinal anesthesia(SA) is the most widely used anesthesia form for ceasarean section(CS). However, cardiac arrest(CA) and life-threatening advanced AV blocks are rarely detected. In this case report, we are presenting a case that developed CA after a 2:1 cardiac block following CS under SA.

CASE: A 27-year-old female patient was taken to the surgery room for CS. She did not have any additional preoperative diseases and her laboratory, vital findings, and electrocardiography(ECG) results were normal. SA was applied with hyperbaric bupivacaine. When the fascia was opened during the surgery, a 2:1 block developed suddenly(figure 2a), and consciousness was lost after the asystole in the patient(figure 2b). Mask ventilation was initiated immediately, cardiac rhythm and consciousness recovered spontaneously after 10 seconds of asystole without any medication. Asystole developed again after 30 seconds(figure 2c). Again, cardiac rhythm and consciousness recovered following 10 seconds of asystole in the patient.The patient was administered 0.5mg atropine, and 2mg midazolam intravenously after the birth of a live baby.

Figure 1: Preoperative elektrocardiography

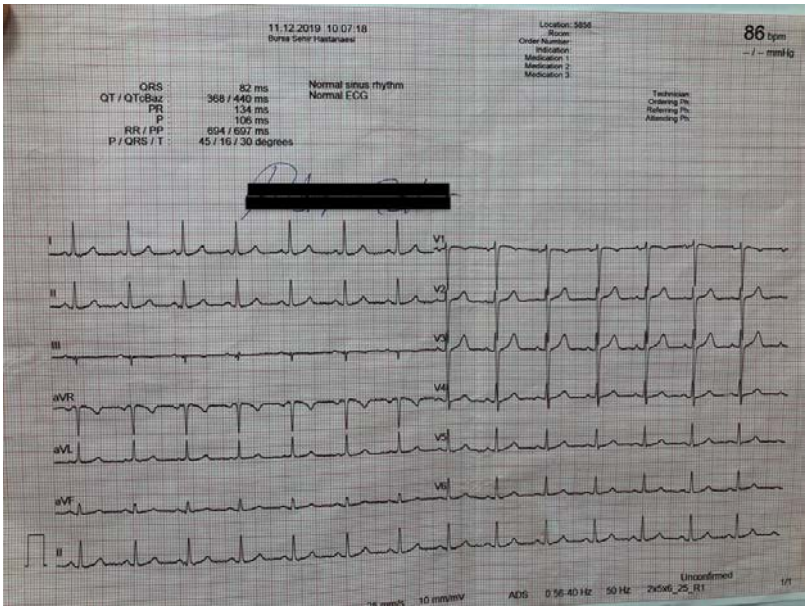

Figure 2: A: Monitor display of 2: 1 block B: Monitor display of asystole (first) C: Monitor display of asystole (second)



DISCUSSION - CONCLUSION: Among the causes of intraoperative cardiac arrest in CS, there are reasons such as the block level increasing to the level of cardiac accelerator fibers coming from the thoracic sympathetic ganglia under SA, increased parasympathetic activity in the manipulation of the uterus, hemodynamic effects during placenta resection, hypovolemia, systemic toxicity of local anesthetic agents, anaphylaxis, and vasovagal reflex.Although rarely, AV block and asystole are seen after SA.To treat these cases in a timely manner, especially young patients with bradycardia, ASA1, and long PR distance in ECG, they must be monitored closely regardless of the size of the surgery in terms of arrhythmia.Vaso-vagal reflex must be kept in mind as one of the intraoperative cardiac arrest reasons that might develop especially in local anesthesia with the triggering of pain, fear, and anxiety irrelevant with the size of the surgical intervention.

Keywords: Asystole, 2:1 atrioventricular (AV) block, spinal anesthesia, caesarean section

Pub No: O-040

Pediatric Paravertebral Block

Selin Bayraktar[1], Volkan Özen[1]

[1]İstanbul Prof. Dr. Cemil Taşçıoğlu City Hospital

INTRODUCTION - PURPOSE: In this case report, we describe the ultrasound-guided bilateral paravertebral block (PVB) that lasts for 36 hours after being applied for postoperative analgesia in explorative laparotomy for Hirschsprung's Disease (HH).

CASE: A 2-year-old male patient, 7900 g was taken to the operating room, sedated with oral midazolam (0.5 mg/kg).After standard monitoring, propofol 2 mg/kg, rocuronium 0.5 mg/kg and fentanyl 1 µg/kg IV were administered for anesthesia induction.After the patient was intubated orotracheal with a 3.5-gauge straight tube, anesthesia was maintained with 2% sevoflurane, 50% oxygen+50% air. Before the surgery, the patient was placed in the lateral decubitus position, after sterilization, the linear ultrasound (US) probe was placed longitudinally-paramedian to the paravertebral area at the T7 level, and the transverse processes, intercostal ligaments, seashore sign and the pleura and paravertebral area were visualized.The paravertebral area was entered after passing the skin-subcutaneously with the in-plane technique with an 80 mm block needle.After negative aspiration, 0.5 ml/kg dose of 0.25% bupivacaine(4 ml) was given and the block was performed.The same procedure was applied for the other side.Meanwhile, a stepsign, which is an indication of the collapse of the pleura, was observed with the expansion of the paravertebral area by administering fluid under ultrasound.The surgery was started 15 minutes after the patient was placed in the supine position.The operation took 170 minutes without complications.At the end, no additional analgesic was applied to the patient for postoperative analgesia.The patient's pain status was assessed by the Face, Leg, Activity, Crying, Consolation (FLACC) score.The FLACC score was zero (0) for 36 hours postoperatively, no additional analgesic medication was used for the first 36 hours.There was no complication related to the use of local anesthetic.

Paravertebral Area



Access to the paravertebral space with a block needle

Stepsign



Stepsign, indicative of collapse of the pleura with enlargement of the paravertebral space by hydrodissection

Local anesthetic injection



Local anesthetic injection

DISCUSSION - CONCLUSION: Ultrasound-guided PVB can be considered as a suitable option because it is an effective method for relieving postoperative pain that may occur after laparotomy.

Keywords: pediatric, Hirschprung, paravertebral block, ultrasound, pain

Pub No: O-041

Our Anesthesia Management in a Patient Who Was Re-operated for Pharyngocutaneous Fistula After Emergency Surgery for Retropharyngeal Abscess: Case Report

Onur Sarban[1], Engin Baydemir[1], Furkan Dikici[1], Pınar İmer[1], Funda Gümüş Özcan[1]

[1]Başakşehir Çam ve Sakura City Hospital

INTRODUCTION - PURPOSE: Although retropharyngeal abscess is mostly seen in pediatric population, it may occur in adults. It requires immediate treatment as it can cause airway obstruction. In this case, we aimed to share our anesthesia management in a patient who was operated for retropharyngeal abscess first and was operated again because of pharyngocutaneous fistula.

CASE: The 17-year-old male patient without any additional disease admitted to the emergency department with difficult swallowing and respiratory distress. After examination, patient was diagnosed with retropharyngeal abscess and decided for emergency surgery. Preoperative imaging revealed a severe anterior deviation of trachea. Because of possible difficult intubation, the decision for awake intubation was made. After the procedure was explained and written consent was obtained, patient was taken to operating room. He had respiratory distress. After administiring 2 mg midazolam, dexmedetomidine infusion was started. Then, local anesthetic was applied to vocal cord region. While awake, patient was intubated using fiberoptic bronchoscope (FOB). After the procedure, the patient was extubated and taken to service for follow-up. During follow-up, local infection occured at incision and medical treatment was applied. On the 30th day the patient, who developed respiratory distress was taken to surgery again for possible diagnosis of tracheoesophageal or pharyngocutaneous fistula. After receiving written consent, anesthesia induction was applied. It was observed that, there was air leakage from the incision during mask ventilation. It was confirmed that there was no pathology in the trachea and lower respiratory tract by intubating with FOB. The patient underwent pharyngocutaneous fistula repair and was successfully transferred to the service.

DISCUSSION - CONCLUSION: Awake intubation with FOB is the recommended for airway safety in such patients. We also think, it is useful for definitive diagnosis of the patient. In this case report, we aimed to share the contribution of our anesthesia management to diagnosis and treatment of the patient.

Preoperative

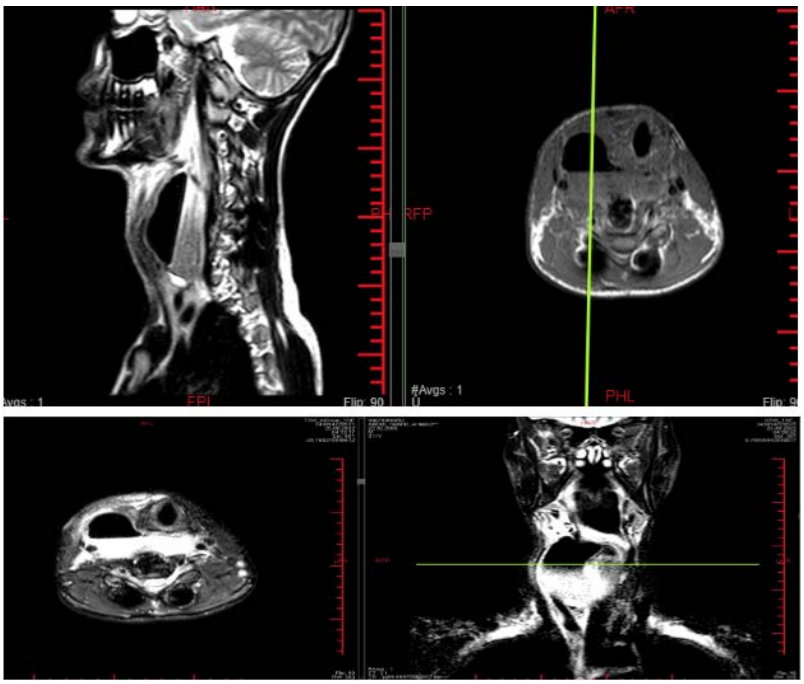

Postoperative

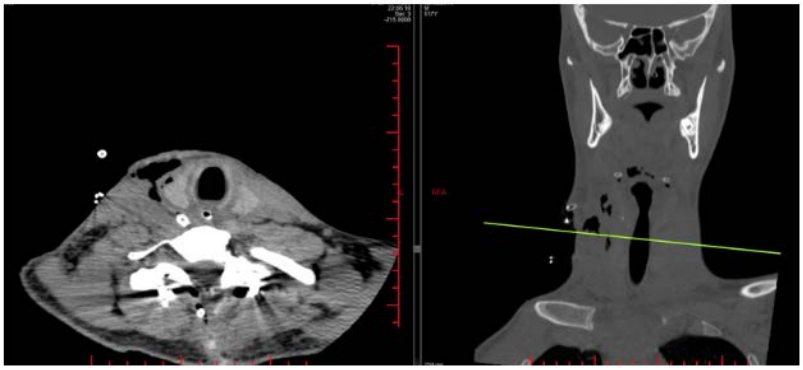

Data on The Abscess Drainage Process

	SpO2	**Pulse**	**Blood Pressure**
Pre-op	94	118	136/82
Post-op	98	74	117/69

Keywords: fiberoptic bronchoscopy, awake intubation, retropharyngeal abscess

Pub No: O-042

Orbital Emphysema After Mask Ventilation

Engin İhsan TURAN[1], Fatma Esin ÖZDEMIR[1], Ayça Sultan ŞAHIN[1], Gülseren YILMAZ[1]

[1]istanbul SBÜ Kanuni Sultan Süleyman Eğitim ve Araştırma Hastanesi

INTRODUCTION - PURPOSE: Orbital emphysema is described as air in the orbital region. It is generally a benign condition which is usually occured after a trauma or fracture. There are some cases in literature about orbital emphysema after orbital trauma or sneezing. Computerized tomography is usefull in diagnosis. Without any occular symptom there is no need for repairment operation. Other than surgery ice application could be a good treatment option.

CASE: Our patient was 28 years old 64 kilograms female patient which has no systematical diseases. She was undergoing dacryocystorhinostomy(DSR) operation. We used 3 number laryngeal mask airway(LMA). There wasn't any anesthesic complications in intraoperative period. For operational reasons ethmoid bone was involved in operation. After the surgery we removed LMA and we ventilated the patient with mask. After the third ventilation patient's operated eye began to swell (figure1). We comunicated immediately with the surgeon. We used ice for orbital emphysema. After the recovery period orbital emphysema significantly reduced. In patients orbital computerized tomography orbital emphysema can be clearly identified(figure2). There wasn't any ocular symptoms other than emphysema. After the one day follow up patient was discharged. After one week patient came to postoperative visit. Emphysema was nearly vanished in the postoperative one week (figure3).

figure 1



postoperative orbital emphysema

figure 2

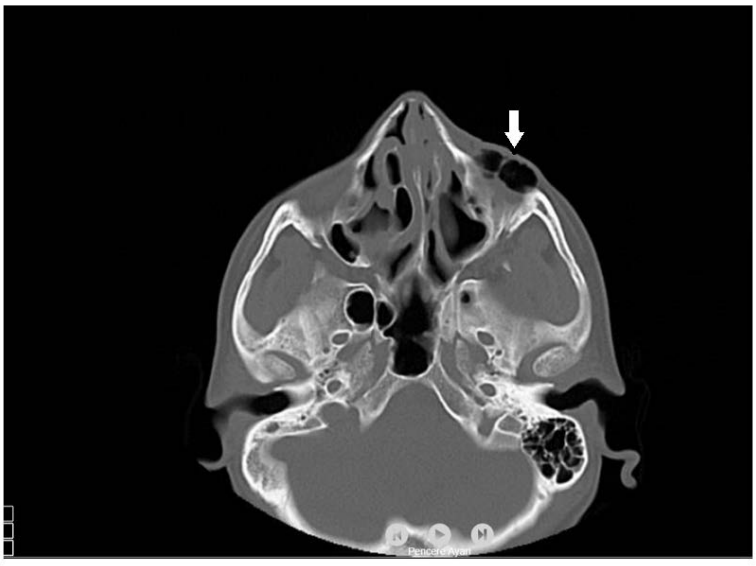

computerized tomography

figure 3



postoperative 1 week

DISCUSSION - CONCLUSION: In conclusion we should be carefull in operations include fascial bones alterations. Mask ventilation in operation including fascial bones can cause orbital emphysema. We need to observe the eye and periorbital area.

Keywords: orbital emphyhsema, anesthesia, laryngeal mask airway, general anesthesia

Pub No: O-043

Acute Appendicitis In Pregnancy: Surgery And Anesthesia Management

Hüseyin KILAVUZ[1], Hürü Ceren GÖKDUMAN[2], Murat DEMIR[1], İdris KURTULUŞ[1]

[1]Başakşehir Çam ve Sakura Şehir Hastanesi Genel Cerrahi Kliniği
[2]Başakşehir Çam ve Sakura Şehir Hastanesi Anesteziyoloji ve Reanimasyon Kliniği

INTRODUCTION - PURPOSE: Acute appendicitis is the most common cause of non-obstetric acute abdomen in pregnancy.Appendectomy surgery and anesthesia applications to be performed in pregnant women may involve risks for mother and fetus.We aimed to present our perioperative approach to patients who underwent appendectomy with a prediagnosis of acute appendicitis.

MATERIALS AND METHODS: Patients who underwent appendectomy in the general surgery clinic of our hospital between June 2021-September 2022 were retrospectively screened.The patients' age, gestational week, diagnostic methods, anesthesia method, operation technique, pathology results, laboratory results, complications and hospital stay were analyzed.Values are expressed as percent (%) and mean (±SD).

RESULTS: The mean age of 17 patients included in the study was 27.4 (±4.8) and there were 1 (5.9%) in the 1st trimester, 11 (64.7%) in the 2nd trimester, and 5 (29.4%) in the 3rd trimester.The mean gestation week was 24.05 (±7.42).For imaging, only ultrasonography (USG) was performed in 5 (29.4%) patients, and USG and magnetic resonance were performed in 12 (70.6%) patients.Spinal anesthesia was applied to 10 (58.8%) patients and general anesthesia to 7 (41.2%) patients.Open surgery with McBurney incision was performed in 16 (94.1%) patients, and laparoscopic appendectomy was performed in 1 (5.9%) patient.Pathology results were consistent with appendicitis in 13 (76.5%) patients, lymphoid hyperplasia in 3 (17.6%) patients, and normal findings in 1 (5.9%) patient.The mean hospitalization day was 2.8 (±3.47) days, and cesarean section was performed on the 7th postoperative day in one patient because of the pain that started on the 1st postoperative day.No perioperative and obstetric complications occurred in the other patients.

DISCUSSION - CONCLUSION: The incidence of acute appendicitis in pregnancy is similar to non-pregnant women, but diagnosis can be difficult.Delay in diagnosis and treatment may cause complications and fetal loss.These risks can be reduced with appropriate preoperative diagnosis and peroperative multidisciplinary approach.

Keywords: Acute appendicitis, Pregnancy, Appendectomy

Pub No: O-044

A Rare Complıcatıon Of Percutane Nephrolıtotomy: Perıoperatıve Management Of Galeblade Perforatıon

Nagihan YILDIZ[1], Ali AKGÜL[1], Hüsniye ASLAN[1], Ahmet BEŞİR[1]

[1]KARADENIZ TECHNICAL UNIVERSITY ANESTHESIOLOGY AND REANIMATION

INTRODUCTION - PURPOSE: Percutaneous nephrolithotomy (PNL) is minimally invasive surgical method used for removal of >2 cm kidney stones. Organ injuries are rare but fatal complications (1,2). In this case, we shared intraoperative effects of massive intraperitoneal fluid accumulation due to peritoneal damage during PNL and early diagnosis and treatment process of gallbladder injury.

CASE: A 36-year-old male patient who was scheduled for PNL due to right nephrolithiasis was evaluated as ASA II due to alcohol use. The patient was operated in the prone position under general anesthesia. Abdominal distention and peripheral edema were observed when he was taken to the supine position after 120 minutes. In the arterial blood gas taken from the patient whose hemodynamics and oxygenation were impaired, pH: 7.00, pCO2: 59mmHg, lactate: 7 mmol/L, HCO3:11.5 mmol/L, BE: -15.1 mmol/L. Necessary fluid replacement, mechanical ventilation strategy and medical treatment were applied to the patient. Free fluid was observed in the abdomen in the USG performed due to the use of approximately 18L of irrigation fluid. Approximately 2 liters of fluid was aspirated in the diagnostic laparotomy. The patient, whose blood gas and hemodynamics were normal at the end of the operation, was extubated. In service follow-ups, pain and tenderness in the abdomen, elevation in acute phase reactants and green fluid in the drain were observed. Biliary perforation was suspected. Abdominal CT revealed perforation of the gallbladder. Laparoscopic cholecystectomy was performed. The patient, whose hemodynamics and laboratory values were good in the follow-up, was discharged.

Resim 1

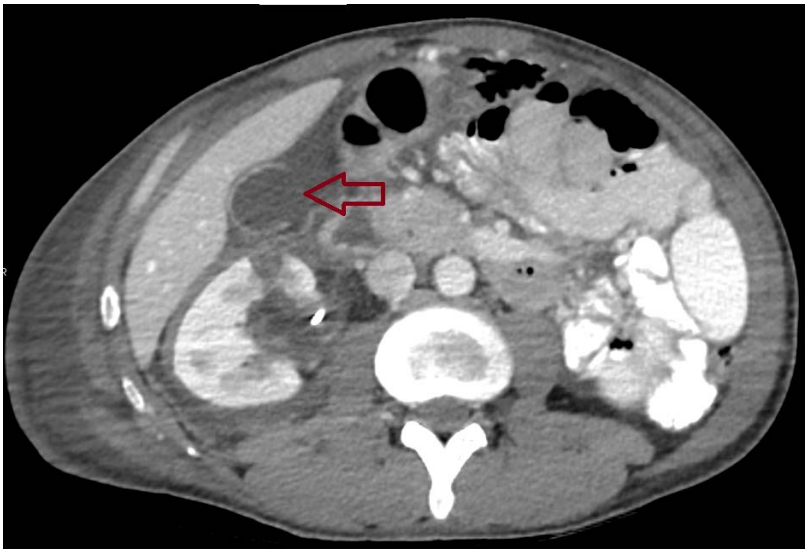

Resim 2

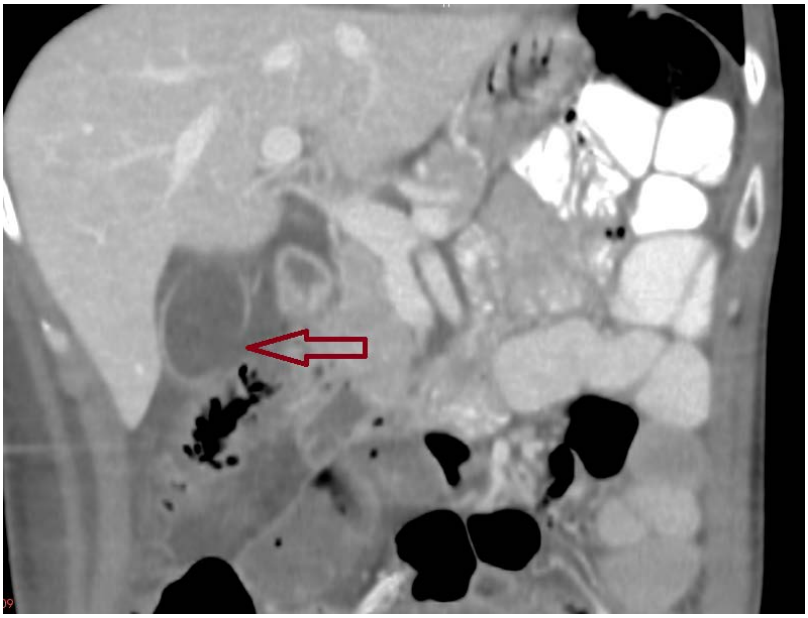

Abdominal bilgisayarlı tomografide perfore safra kesesi ve perikolesistik alanda sıvı

DISCUSSION - CONCLUSION: Biliary system injuries due to PNL are rare in literature (3,4,5). In cases of PNL, there may be increased intra-abdominal pressure due to peritoneal damage, and its effects should be well known. In the postoperative period, acute abdomen findings should warn about organ injuries, and it should not be forgotten that early diagnosis and treatment are life-saving.

Keywords: Nephrolithotomy, complications, biliary tract injury, anesthesia

Pub No: O-045

Anesthesia Management In A Patient With Edwards Syndrome

Oğuzhan HÜNÜK[1], Osman Özgür KILINÇ[1]

[1]Amasya University Sabuncuoglu Serefeddin Training and Research Hospital

INTRODUCTION - PURPOSE: Edwards syndrome, also known as trisomy 18, is autosomal chromosomal disorder that includes many congenital anomalies. The prevalence of live birth is between 1/3600-10,000 and unfortunately has a poor prognosis resulting in death in the first 1 year in 90% of the affected pediatric population. The aim of this article is to present our anesthesia experience in a patient with Edwards syndrome and to contribute to the limited anesthesia literature.

CASE: In the examination of male patient (9 years, 24 kg) who was scheduled for surgery due to a left inguinal hernia; Dysmorphic facial appearance, prominent forehead, small chin, triangular face and pectus carinatum were present. Breath sounds, chest X-ray and routine laboratory results were normal. Electrocardiogram showed sinus rhythm, echocardiography showed stage 1 mitral regurgitation with normal ejection fraction. The patient was classified as ASA 2 and mallampati 3.In the preoperative standard noninvasive monitoring, heart rate was 88/min, TA:100/60 mmHg, SO2 was 98%. After preoxygenation with 100% O2, intravenous (iv) propofol, fentanyl and rocuronium bromide were administered for anesthesia maintenance. After adequate muscle relaxation was achieved, a size 2.5 proseal laryngeal mask (LMA) was placed on the patient. In pressure-controlled ventilation mode, anesthesia was maintained with a mixture of 50:50% oxygen:air and 1-2% sevoflurane. The operation took 30/min. Neuromuscular blockade was reversed using 2mg/kg sugammadex and the LMA was removed while the patient was deep. There was no problem in the postoperative period.

DISCUSSION - CONCLUSION: Anesthesia literature specifically addresses the difficulties experienced in patients with heart problems and emphasizes difficult airway anatomy. The key points in the anesthetic management of patients with Edwards syndrome are a thorough pre-anesthetic assessment and the establishment of a good airway management plan. The publication of new case reports will contribute to increasing our knowledge in anesthesia management.

Keywords: Edwards Syndrome, LMA, Difficult Airway

Pub No: O-046

Differential Diagnosis Of Altered Conciousness After Scoliosis Surgery

Ayfer KAYA GÖK[1]

[1]SBÜ Gaziosmanpaşa Eğitim ve Araştırma Hastanesi , Anestezi ve Reanimasyon

INTRODUCTION - PURPOSE: Adolescent idiopathic scoliosis (AIS) is a common type which affects 1-3% of children in the at-risk population of those between 10-16 years(1). Some of these patients have concurrent cerebral palsy (CP), which is associated with many medical comorbidities (2). Peroperative increased risks and complication rates, prolonged length of stay (LOS) is an important problem. We report this case for the differential diagnosis for the postoperative altered consciousness.

CASE: A 15-year-old man with CP and epilepsy was operated for scoliosis, operation lasted for 8 hours (fluids given was 2000 mL crystalloids and 1 unit of erythrocyte suspension , bleeding was 150 mL and urine output was 1200 mL). He was hemodynamically stable peroperatively, he was discharged from the ICU next morning. The patient remained well until 24 hours after operation, when he complained of vomiting, fever, altered conciousness and abdominal distention. He was irritable and found to have nuchal rigidity. The differential diagnoses were meningitis, pneumonia, ileus and perforation. In the ICU pediatric surgery and neurology consulted the patient; decided to start ceftriaxone and vancomycine although procalcitonin is negative; imaging CT or MR for abscess, bleeding (no cranial pathology, pleural and abdominal effusions); initiation of levotiracetam if seizures start; look for amylase-lipase for changes secondary to possible retroperitoneal scoliosis surgery. Every laboratory test were normal, abdominal examination was normal, gas distension was secondary to immobility, and effusions were secondary to fluid overload. He was taken to the service after 3 days of close follow-up.

resim 1



resim 2

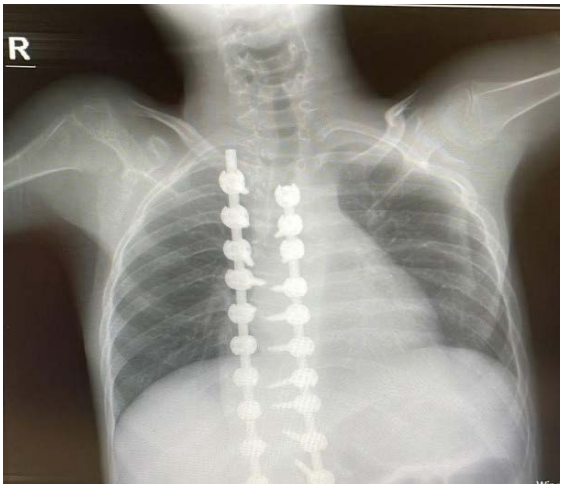

DISCUSSION - CONCLUSION: AIS needs extra care in patient selection and treatment protocols, because complications are defined as neurologic injury, transfusion, hemorrhage, device complications, respiratory distress, abdominal complications, pneumonia, surgical site infection , total parenteral nutrition, mortality, and non-home discharge (2,3,4). To understand the reason of complication doctors need to be careful and tight followup must be done.

Keywords: adolescent idiopathic scoliosis, postoperative complication

Pub No: O-047

Diagnosis and Treatment of Spinal Dural Arteriovenous Fistula: Case Report

H. Ayben KORKMAZ[1], Serpil EKIN[1], Banu YETIK[1], Tirdad SETAYESHI[1]

[1]Bursa Yüksek İhtisas Training and Research Hospıtal

INTRODUCTION - PURPOSE: Spinal dural arteriovenous fistulas (SDAVF) are one of the causes of myelopathy. The increase in spinal vein pressure leads to progressive symptoms. We wanted to present our approaches in the diagnosis and treatment process of a patient admitted to the intensive care unit with myelopathy.

CASE: A 70-year-old male patient was admitted to the intensive care unit when he developed respiratory difficulty while lying in the neurology ward due to weakness, stool incontinence and urinary retention. There was a history of diabetes mellitus, hypertension, intracranial aneurysm operation and intensive care unit admission due to covid-19 pneumonia. In the preliminary diagnosis; Guillain-Barré syndrome, spinal mass and SDAVF were considered. There were no acute neuropathological findings in brain CT and diffusion MRI. EMG was consistent with moderate sensory polyneuropathy MRI of the vertebrae showed suspicious tortuous vascular structures in the posterior subarachnoid distance.DSA showed a dural arterio-venous fistula originating from the anterior spinal artery at the C1 level and extending to L1. After evaluation by neurosurgeons and radiology physicians, histoacryl glue and lipiodol were applied angiographically to the fistula area with a microcatheter. No filling was detected in SDAVF in control angiograms. Anterior spinal artery and PICA fillings were fully detected. After the radiological intervention, dexamethasone 4*4 mg was added to the treatment. The patient was followed in CPAP mode there was no increase in strength loss in the extremities.

Venous Scanning

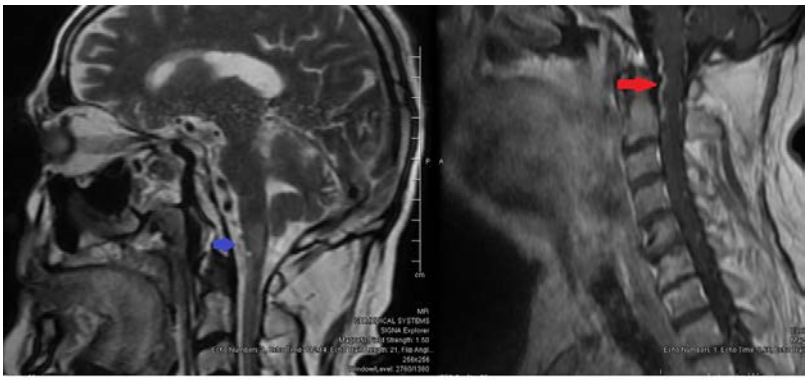

Abnormal venous structures are seen in pre-procedural contrast-enhanced MRI (red arrow) and there are no veins in the area on post-procedure MRI (blue arrow)

DSA

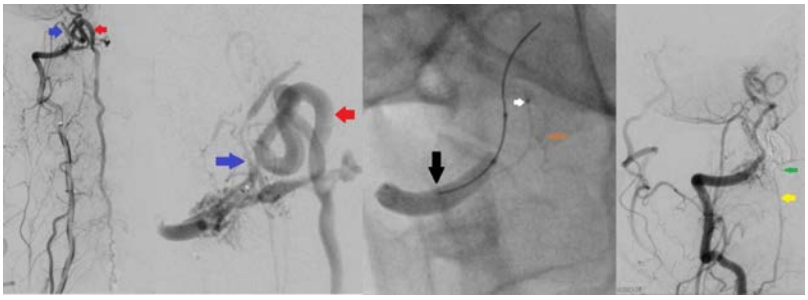

First and second images pre-op AVF level draining vein (red arrow). Fistula level (blue arrow). The third picture is the balloon catheter (black arrow) and microcatheter (white arrow) during the operation and the injected nBCA (brown arrow) into the venous side. The fourth image is the post-embolization images. Open anterior spinal artery (yellow arrow) and embolized venous structures (green arrow)

DISCUSSION - CONCLUSION: SDAVFs are the most common spinal vascular malformation that can cause progressive symptoms. Selective spinal DSA is required to fully understand the disease. In our case, the diagnosis was delayed because muscle weakness started after Covid-19 pneumonia. Dural AVF formed by vascular structures in DSA, explains respiratory distress and loss of strength in the extremities. Neurological symptoms in SDAVF patients are nonspecific; however, it should be considered in patients presenting with myelopathy.

Keywords: vascular malformation, myelopathy, spinal dural arteriovenous fistula, Digital subtraction angiography

Pub No: O-048

Emergency Surgery In Patients With COVID-19: a 2-year prospective study

İrem ERKAN[1], Özge SAYIN AYAN[1], Esra AKDAŞ TEKIN[1], Fethi GÜLTOP[1], Zekeriya ERVATAN[1], Namigar TURGUT[1]

[1]Prof. Dr. Cemil Taşcıoğlu Şehir Hastanesi

INTRODUCTION - PURPOSE: With the COVID-19 pandemic, healthcare professionals have rapidly shifted their professional responsibilities to help meet hospital needs. Except for emergency surgeries, elective surgery applications have decreased rapidly. In the study, 27 patients who were admitted to the service and ICU of our hospital as of the beginning of 2020 COVID-19 and then required emergency operation were followed for 2 years.

MATERIALS AND METHODS: After Ethics Committee Approval, 27 patients who were scheduled for emergency surgery were included in the study. Patients time to COVID-19, time to operation, preoperative co-morbidities, hemoglobin, Platelet/Lymphocyte Ratio (PLR),Neutrophil/Lymphocyte Ratio (NLR), intraoperative events, postoperative complications, and final status information were recorded.

RESULTS: 21 female/6 male patients participated in the study(The mean age 55.96).The patients were divided into Group I (Malign Patients,n=12), and Group II (NonmalignPatients,n=15) according to the presence of malignant tumor undergoing the operation. The operation time for Group I after COVID-19 was 140.08/day, while it was 195.6 for Group II.Preoperative Hb values were similar in both groups (12.49vs12.9%). Preop PLR, NLR value was found higher in Group I than Group II (133 vs 118, 2.5 vs 1.8). DM Type 2 and hypertension were seen in both groups at the beginning of preoperative comorbid conditions. The most common intraoperative hypotension (5 patients in Group I (41.6%),2 patients in Group II(13.3%), hypertension (2 patients in Group II, 1 patient in Group I) and arrhythmia (in 1 patient in Group I) (8.3%) In Group I, the patient who was operated for cranial tumor died on the 21st post-operative day.

DISCUSSION - CONCLUSION: Especially in the first months of the pandemic, emergency surgical intervention was needed for time-sensitive disease processes such as malignant neoplasia in COVID-19 patients requiring hospitalization. For similar situations in the future, national guidelines should be prepared to provide safe surgical care for patients and to minimize hospital-acquired transmission to healthcare workers

Keywords: COVID-19, Malign, Surgery, Emergency

Pub No: O-049

Pericapsular Nerve Group Block: A Novel Analgesic Technique For Hip Surgery

Ufuk TURAN[1]

[1]Bor State Hospital, Ministry of Health

INTRODUCTION - PURPOSE: Pericapsular nerve group (PENG) block is a new ultrasound-guided regional anesthesia technique recommended as an alternative to existing blocks to reduce pain after hip surgery. PENG block shows promising results in providing analgesic effect with a potential motor-sparing effect.

CASE: Three patients scheduled for hip surgery underwent ultrasound-guided PENG block followed by spinal anesthesia. The femoral artery and iliopubic eminence were visualized (Figure 1). The needle was advanced while using in-plane technique. 20 ml of 0,25% bupivacaine was injected between psoas tendon and pubic ramus (Figure 2). Fixed dose intravenous acetaminofen and tramadol administered as postoperative analgesia; intravenous morphine planned as rescue analgesia. Post-operative Numeric Rating Scale (NRS) pain scores of the 3rd, 12th and 24th hour observed for analgesic efficacy. Also need for rescue analgesia and existence of motor blockage of femoral region observed. The analgesic effect of this plane block observed on seven hip surgery cases. Postoperatively, PENG block provided effective analgesia in all of the patients. Median value of NRS pain scores were 4, 2, 1 respectively. No postoperative motor block and need for rescue analgesic was observed in any patient (Table 1).

Figure 1

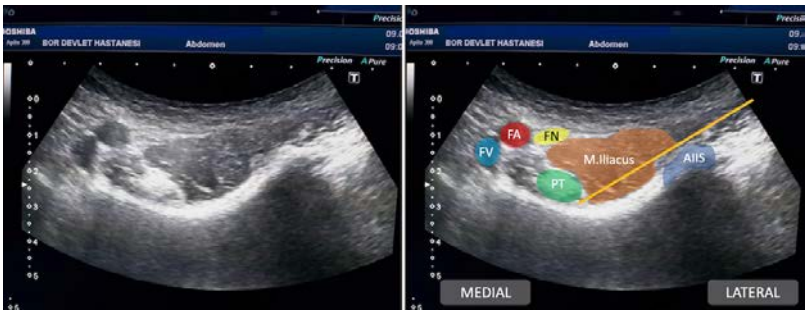

Ultrasound image of location of PENG block. Femoral Artery (FA), Femoral Vein (FV), Femoral Nerve (FN), Inferior Iliac Spine (AIIS) and Psoas Tendon (PT). Orange arrow indicates needle pathway.

Figure 2

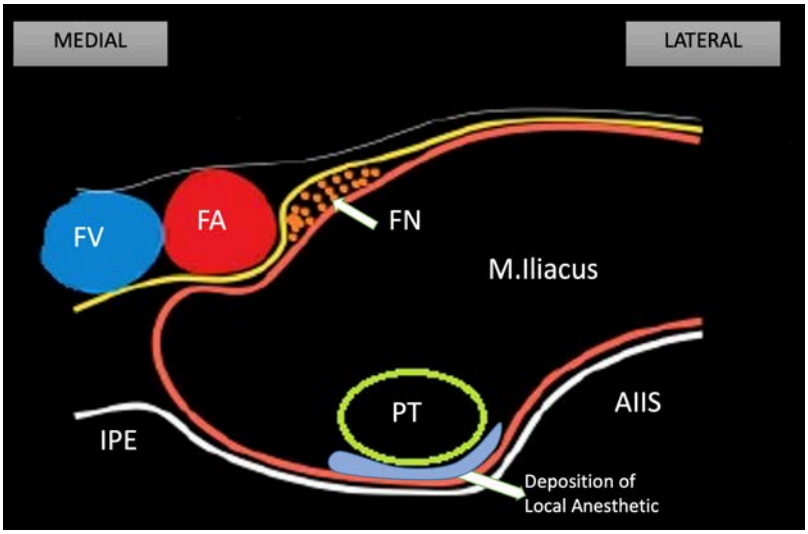

Schematic drawing of the PENG block. Femoral Artery (FA), Femoral Vein (FV), Femoral Nerve (FN), Inferior Iliac Spine (AIIS), Psoas Tendon (PT), Iliopubic Eminence (IPE), and Psoas Tendon (PT). Yellow line indicates the fascia iliaca.

Table 1

Fracture Type	**Surgery Type**	**Age**	**Gender**	**3 hour NRS Score**	**12 hour NRS Score**	**24 hour NRS Score**	**Rescue Analgesic**	**Motor Block**
Femur Neck	Total Hip Replacement	69	F	5	2	2	-	-
Femur Neck	Total Hip Replacement	75	F	4	2	1	-	-
Subcapital	Total Hip Replacement	82	M	2	3	1	-	-

Patient's demographic information and observed result

DISCUSSION - CONCLUSION: PENG block effects the articular nerve branches of the anterior hip capsule. It has many potential advantages over other techniques (femoral nerve block, lateral femoral cutaneous nerve, fascia iliaca block) for hip surgery. Firstly the block has a wide coverage of sensory nerves innervating the joint capsule. Therefore, reduced postoperative opioid consumption results less opioid-related side effect. The motor-sparing effect causes better range of hip motion and fast ambulation after surgery. Further studies are required to address the ideal regional analgesic technique for hip surgery.

Keywords: Pericapsular nerve group block, PENG block, Total hip arthroplasty, Postoperative pain, Regional anesthesia

Pub No: O-050

Does Applying Morphine To The Cerebrospinal Fluid With Heavy Marcain Change The Isobaric Characteristic of Morphine? Animal Trial Via Artificial Cerebrospinal Fluid, A Pilot Study

Fatma Ferda KARTUFAN[1], Erkan BAYRAM[1], Turgay ÇELIK[2]

[1]Istinye University Anesthesiology and Reanimation Dept
[2]Yeditepe University Faculty of Pharmacy

INTRODUCTION - PURPOSE: Studies on intratechal Heavy Marcaine (Hm) administration with adjuvants have reported that the postoperative analgesic efficacy of Morphine is longer than that of other adjuvants (1), but how does Morphine, which is isobarically emitted in the Cerebrospinal fluid, provide longer analgesia than Fentanyl that has a greater efficacy and half-life. The aim of the study was to investigate whether the hyperbaric H.Marcaine in artificial Cerebrospinal fluid (aCSF) causes Morphine precipitation in aCSF. To our knowledge, there is no similar study in the literature.*İlgili kongre tanımlı değilse Kongre adı yazılır (kısa ismi) ekle denir.*İlgili kongre seçilmeli.

MATERIALS AND METHODS: For this pilot study, which was approved by YUDHEK on 11.10.2022, 5 BALBc breed mice were provided by YUDETAM. aCSF composition has been prepared at Y.U. Faculty of Pharmacy. Grouping and Collection of Data; Mice1 and Mice2 were assigned to the aCSF-Hm group, Mice3 and Mice4 to the aCSF-Hm&M group, and Mice5 to the M group.In three groups, tail-immertion(sec), tail-flick(sec), Straub phenomenon parameters were evaluated at 45th, 60th, 75th and 90th minutes after intraperitoneal injection(IP).Methods: Two graduated cylinder(gc) were coded as A-B and filled with aCSF. 1mL Hm and 0.5mL Morphine were added to the A and 1mL Hm to the B. The mixtures were left for 20 min. 1mL was taken from the bottom of each gc to A and B vials. From the A-vial, 0.3mL was applied to the aCSF-Hm&M group and 0.3mL from B-vial, to aCSF-Hm group via IP. Mice were then taken to black observation cages.

RESULTS: Straub phenomenonStraub phenomenon occurred in all mice in the M and aCSF-Hm&M group, while it did not occur in mice in the aCSF-Hm group. The Tail-immertion and Tail-flick test results are as shown in Table 1.Statistics: Straub phenomenon: The results in the aCSF-Hm group and the aCSF-Hm&M group were significantly different(p=0.046-Chi-Square test).Statistical results in the aCSF-Hm group and the aCSF-Hm&M group who underwent

Table 1

Table 1	aCSF-Hm		aCSF-Hm&M		M
	Mice1	Mice2	Mice4	Mice3	Mice5
Tail-immertion(sec)					
45th minute	3	4,4	15	30	25
60th minute	3,2	4,7	13,2	23	30
75th minute	3	4,3	13	28	25
90th minute	4	4	17	30	18
Tail-flick (sec)					
45th minute	3,3	5,3	10	12	12
60th minute	3,7	3,6	10	11	10
75th minute		2,7	15		10
90th minute		3,1			

aCSF-Hm: atrificial cerebrospinal fluid –Heavy marcaine group, aCSFHm&M: atrificial cerebrospinal fluid –Heavy marcaine and Morphine group, M: Morphine group, sec:second

Table 2

Table 2	aCSF-B	aCSF-BM	p
Tail-flick test			
45.dk	0,618±0,15	1,040±0,06	0.061
60.dk	0,561±0,02	1,021±0,029	**0.003**
Tail-immertion test			
45.dk	0,559±0,12	1,327±0,21	**0.046**
60.dk	0,590±0,12	1,241±0,17	**0.047**
75.dk	0,553±0,11,	1,281±0,24	0.058
90.dk	0,602±0,00	1,353±0,17	**0.026**

Log10 values were measured and evaluated with Student-T test

DISCUSSION - CONCLUSION: It has been stated that adjuvant morphine in spinal anesthesia applications in elderly people is successful in preventing postoperative pain, especially in lower extremity surgeries(2-3). The in-vitro stability of morphine and bupivacaine mixture has been proven to be 100% for 90 days even at 37 degrees(3). Results of an obstetric surgery trial demonstrated that intrathecal morphine is as effective as fentanyl for intraoperative analgesia and produces better postoperative analgesic quality than fentanyl(1). Our pilot study suggests that this may be due to Hm-guided morphine precipitation in aCSF, its maintained stability and storage effect, as in mice where pure morphine is applied. The present study approved by YUDREK, will be expanded with a total of 49 mice in 7 different groups.

Keywords: Artificial cerebrospinal fluid, Morphine, Straub phenomenon, Tail-flick test, Tail-immertion test

Pub No: O-051

Atypic Hemolytic Üremic Syndrome Due To Clostridium Difficile Infection: A Case Report

Serdar YEŞILTAŞ[1], Aylin Ceren ŞANLI[1], İsmail SÜMER[1]

[1]Bezmiâlem Vakıf Üniversitesi Hastanesi

INTRODUCTION - PURPOSE: HUS is a rare clinical picture with typical and atypical forms, characterized by non-immune hemolytic anemia, thrombocytopenia, and renal failure.Gastroenteritis and upper respiratory tract infection are the most common factors causing HUS. 90% of the cases are typical HUS cases that occur with O157:H7 E.coli strain in the digestive tract(2,3).AHUS is extremely rare.We present a case that we diagnosed as AHU after pseudomembranous colitis, successfully treated with plasmapheresis.Our case is one of the rare cases reported to have completely recovered after prolonged plasmapheresis.

CASE: A 76-year-old female patient applied to an external center with complaints of abdominal pain and bloody diarrhea.The patient was admitted to the infectious diseases service with a preliminary diagnosis of gastroenteritis.The patient, who had seizures, decreased consciousness, and had a GCS of 6 on admission to the ward, was admitted to our intensivecareunit by orotracheal intubation under emergency conditions.Midazolam infusion was started in the patient who had seizures.In cranial MRI, findings consistent with hypoxic ischemic injury were detected.Oral vancomycin and metronidazole treatment was started.The patient whose stool examination was positive for C.difficile toxinA.In the clinical course, anemia, thrombocytopenia, renal failure, pseudomembranous colitis, hypertension and seizures made the diagnosis of atypical hemolytic uremic syndrome.It was observed that the hypoxic areas of the control brain MRI of the patient, who underwent eleven courses of plasmapheresis treatment and whose conscious state improved after the treatment, regressed.After one month of hospitalization, the patient recovered completely and was discharged with initial mental status.

DISCUSSION - CONCLUSION: Our case represents a rare case of PMC-associated severe aHUS of this disease.Especially in patients with gastroenteritis who apply to the intensive care unit with hemolytic anemia, abys and thrombocytopenia, although atypical findings may be added, HUS should definitely be considered in the differential diagnosis.The available therapeutic options for AHU are plasma exchange and eculizumab with C5 monoclonal antibody(4).

Keywords: Hemolytic uremic syndrome, Pseudomembranous colitis, C.difficile

Pub No: O-052

Triphasic Response After Pituitary Surgery: A Case Report

Nurhan EREN[1]

[1]Erzincan Mengücek Gazi Training and Research Hospital

INTRODUCTION - PURPOSE: Sodium and fluid balance disorders might develop in patients which have underwent pituitary surgery.Water balance disorders can develop in biphasic or even triphasic pattern(1).While the triphasic response is an interesting concept,it is often difficult to manage.

CASE: 65-years-old male patient who had no additional diseases except pituitary adenoma was scheduled for operation by neurosurgery department.The patient underwent transsphenoidal surgery via general anesthesia,didn't develop any intraoperative complications and was taken to postoperative intensive care unit after surgery.Single dose of desmopressin(2µg-sc) was administered to patient that has developed CDI and whose sodium level was measured as 157mEq/L.Three days later,hyponatremia(120mEq/L)developed without any neurological symptoms.High urine osmolality and low serum osmolality were observed in follow-ups,hence patient was diagnosed with SIADH.After sodium level gradually increased to 132mEq/L on 10th postoperative day,fluid restriction and sodium chloride regimen was started.Patients' sodium level increased to 161mEq/L.3 days after being transferred to service,and he was admitted to ICU again.Patient was diagnosed with CDI and nasal desmopressin(10µg twice a day)was started,and an improvement in sodium levels(145mEq/L)was observed 2 days later.

DISCUSSION - CONCLUSION: First stage of triphasic response is development of CDI as a result of ADH deficiency.It is manifested by excessive thirst,polydipsia,polyuria,and diluted urine.Frequent monitoringof fluid intake,urine output and serum sodium,urine specific gravity and osmolality is required for immediate recognition of condition.In severe hypernatremia(>155mEq/L),desmopressin should be used.The second stage of triphasic response is transient SIADH,which develops 4-10 days after surgery and is characterized by hyponatremia.While mild hyponatremia can be managed with fluid restriction,severe or symptomatic hyponatremia may require aggressive treatment with fluid restriction,hypertonic saline,and/or vaptans.This is followed by the third stage of Triphasic response,which is characterized by the recurrence of the CDI,which may be permanent (2,3).Management is phase dependent and it is very important not to overtreat the first phase of DI,which can potentially cause severe hyponatremia during the next phase of SIADH.

Triphasic Response

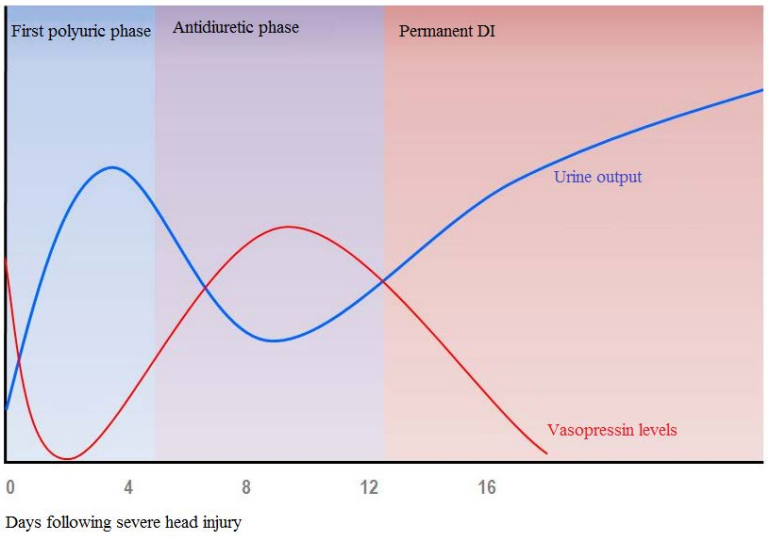

Keywords: Pituitary Surgery, triphasic response, diabetes insipidus (DI), inappropriate ADH syndrome (SIADH), central diabetes insipidus (CDI)

Pub No: O-053

Retrospective Assessment Of Analgesic Effect Of Erector Spinae Block After Breast Cancer Surgery

Ersin SÖNMEZ[1], Işın GÜNEŞ[2], Mustafa GÖK[3], Aliye ESMAOĞLU ÇORUH[2]

[1]Bünyan State Hospital, Anesthesiology and Reanimation
[2]Erciyes University Medicine Faculty, Anesthesiology and Reanimation
[3]Erciyes University Medicine Faculty, General Surgery

INTRODUCTION - PURPOSE: It was aimed to evaluate effects of ESPB on postoperative analgesic consumption, pain scores, and postoperative persistent pain in cases underwent breast cancer surgery.

MATERIALS AND METHODS: After ethic approval, files of 51 ASA I-II patients (aged 18-65 years) between were analyzed. 40 patients were included to study after applying exclusion criteria. ESPB group (n=20) included patients underwent block using 0.25% bupivacaine (25 mL) at T4 before surgery. Control group (n=20) included patient without ESPB. Morphine consumption via PCA device and VAS scores at recovery room and on hours 2, 6, 12, 18, 24 were recorded from anesthesia follow-up form. To assess severity and neuropathic component of pain on month 3 and 6, VAS and LANSS scores were recorded. Demographic and hemodynamic data, type and duration of surgery, intraoperative fentanyl consumption, rescue analgesic consumption, length of stay in recovery unite, incidence of PONV, patient satisfaction and oncologic treatment modalities were recorded.

RESULTS: There was no significant difference in demographic characteristics and perioperative hemodynamic data. Morphine consumption within first 24 hours was significantly higher in ESPB group. Static VAS scores assessed at rest were lower in ESPB group than control at all hour except 24th. Dynamic VAS scores assessed by upper extremity abduction were comparable between groups at all time points other than hours 12 and 18. Rescue analgesic consumption was significantly lower in ESPB group than controls. The patient satisfaction was higher in ESPB group. There was no significant difference in length of stay in recovery unit and incidence of nausea-vomiting. There was no significant difference in VAS and LANSS scores on month 3 and 6.

Morphine Consumption

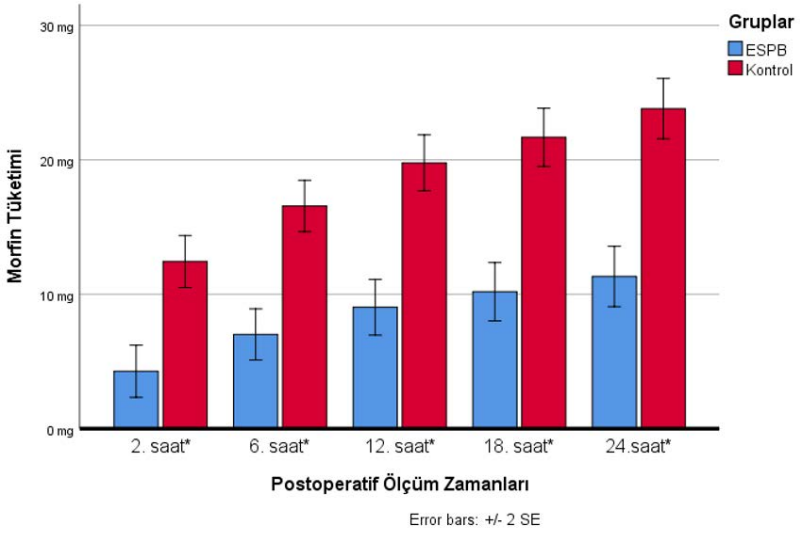

VAS Scores at rest

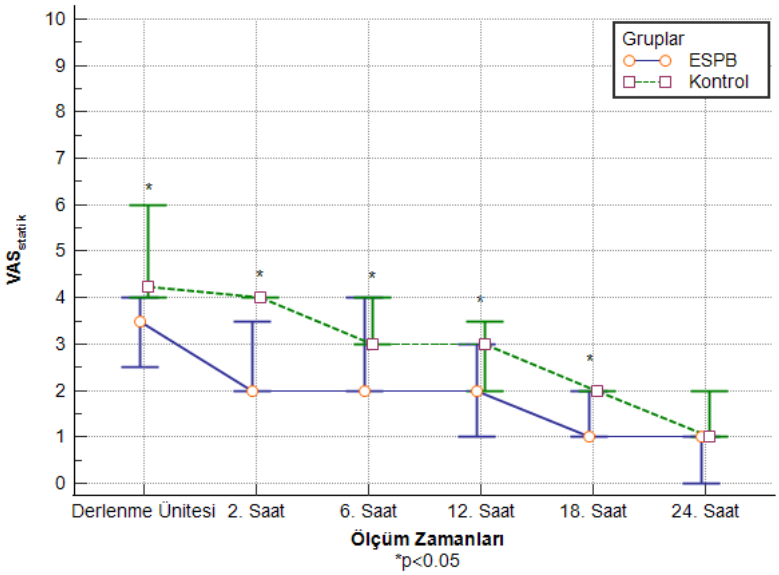

VAS Scores with arm abduction

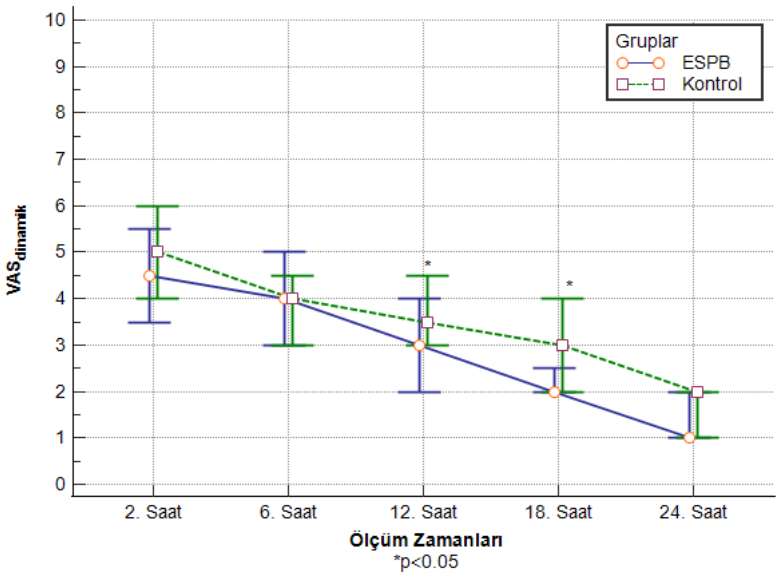

Comparison of Pain at 3. Month After Discharge

	ESPB (n=20)	**Control (n=20)**	**P value**
VAS	0 (0-2)	1 (1-3)	0,445
LANSS	5 (0-6)	5 (1,3-6)	0,678
Patients with any degree of pain	8 (%40)	11 (%55)	0,342
Patients with VAS≥3 pain	3 (%15)	6 (%30)	0,451

Comparison of Pain at 6. Month After Discharge

	ESPB (n=20)	**Control (n=20)**	P value
VAS	0 (0-0.8)	1 (0-2)	0,355
LANSS	0 (0-3.8)	2.5 (0-6)	0,142
Patients with any degree of pain	5 (%25)	8 (%40)	0,311
Patients with VAS≥3 pain	0 (%0)	3 (%15)	0,231

DISCUSSION - CONCLUSION: Reducing opioid consumption and pain scores ESPB can be used effectively as part of multimodal analgesia in breast cancer surgery. Similar incidence of PPBCS at 3. and 6.month suggests that ESPB may be ineffective in long term pain.

Keywords: breast surgery, acute postoperative pain, nerve block, Chronic postoperative pain, opioid analgesics

Pub No: O-054

The Effects of Prone Position on Optic Nerve Sheath Diameter and Intraocular Pressure in Elective Lumbar Disc Surgery

Resmi Hakan ADAS[1], Şule BATCIK[1]

[1]RECEP TAYYIP ERDOGAN UNIVERSITY

INTRODUCTION - PURPOSE: The prone position given to the patient in lumbar disc surgeries causes an increase in intracranial pressure. (1) Optic nerve sheath diameter (ONSD) can be used as a noninvasive sign of increased intracranial pressure. (2) Likewise, it has been reported that intraocular pressure (IOP) increases when intracranial pressure increases. (3) We aimed to evaluate the relationship between ONSD and IOP measurements taken in the prone position.

MATERIALS AND METHODS: 58 patients, whose Ethics committee approval and informed consent were obtained, aged between 18-65 years, ASA class I and II, who underwent elective lumbar disc surgery under general anesthesia, were included in this study. ONSD was measured by the linear probe of ultrasonography from 3mm behind the eyeball. IOP measured by the TonoPen XL device. Patients with neurological and ophthalmic pathology, pregnant, emergency intervention planned, BMImi >30 kg/m2, and need of vasopressors was excluded. The same general anesthesia procedure was performed for all patients. ONSD and IOP were measured three times; in the supine position before anesthesia, in the supine position at the 10th minute after anesthesia, and finally in the prone position at the 45th minute.

tonopen xl



tonopen is used for measuring intraocular pressure

method of measuring optic nerve sheath diameter

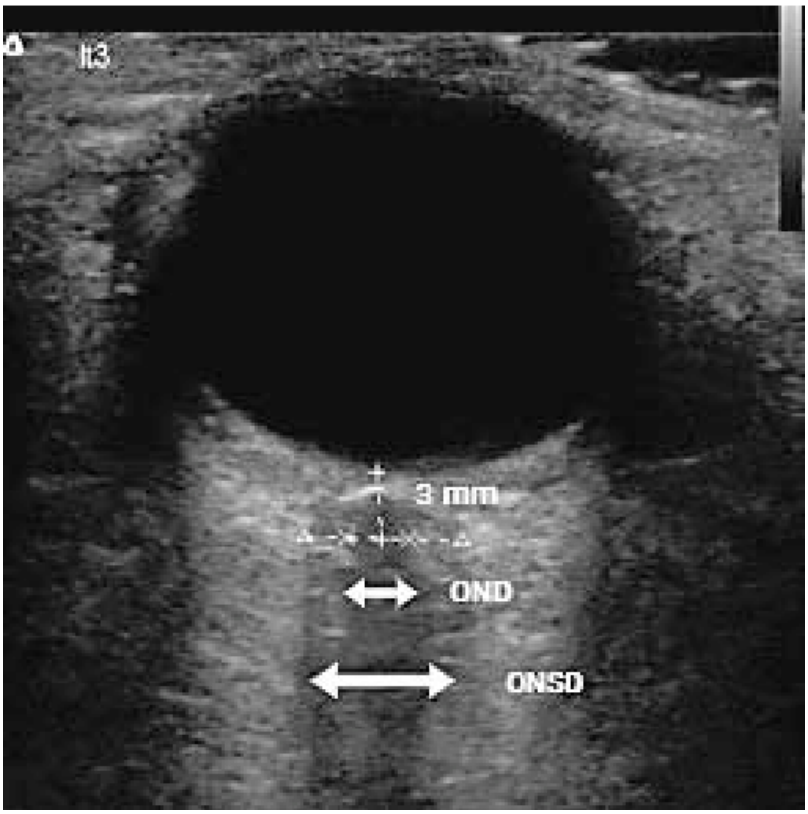

ONSD is measured from 3mm behind the ocular globe

RESULTS: 47.5% (n=28) of the participants were female and 93.2% (n=55) were from the ASA II group. The average age was 46.31±11.42/years, and their body mass index average was 27.13±2.93kg/m2. ONSD and IOP measurements were significantly higher in the prone position. However, no correlation was found between ONSD and IOP measurements. There was no statistically significant difference between the right and left eyes.

DISCUSSION - CONCLUSION: Similar to other studies, we observed that intraocular pressure and Optic nerve sheath diameter measurements increased in the prone position, but these were not correlated. (4-7) According to the results of our study, ONSD or IOP can be used in the diagnosis and follow-up of intracranial pressure increase syndrome.

Keywords: optic nerve sheath diameter, intraocular pressure, intracranial pressure, prone position

Pub No: O-055

Rhabdomyolysis As A Rare Complication Of COVID-19 : Case Report

Gökhan KILINÇ[1]

[1]Balıkesir Atatürk City Hospital

INTRODUCTION - PURPOSE: Complications such as thromboembolic symptoms, encephalitis, Guillain-Barré syndrome, acute kidney injury have been reported in COVID-19 patients. Rhabdomyolysis is a rare condition in COVID-19, potentially life-threatening. We present a case of rhabdomyolysis due to Covid-19 and followed in the intensive care unit.

CASE: A 22-year-old female patient presented to the emergency department with complaints of weakness in the lower extremities and widespread body pain. The patient had no chronic disease, drug and substance use history, herbal supplement use, recent alcohol use, trauma and substance use, travel or patient contact history. There was no family history of rhabdomyolysis, other muscle or metabolic disorders, kidney disease, or thyroid disease. Abdominal ultrasonography, brain computed tomography and brain diffusion magnetic resonance imaging examinations of the patient were normal. The patient's cardiological examination, echocardiography and thorax computed tomography were normal. The patient's COVID-19 polymerase chain reaction nasopharyngeal swab was positive. There was no urine output on the 3rd day of hospitalization and creatinine: 6.89 mg/dL, urea: 147 mg/dl, AST: 2345 U/L, ALT: 685 U/L, LDH: 3748 U/L, CK -MB: 2038 U/ L, blood urea nitrogen (BUN): 68.7 mg/dl. Hemodialysis was applied to the conscious, cooperative patient by inserting a dialysis catheter. GCS: 15, spontaneous respiration spo2: 96 (at room air) Pulse: 98 Ta: 127/68.In the following days, biochemistry indicators gradually returned to normal (Figure: 1,2,3) and the patient's complaints regressed. On the 44th day of hospitalization, creatinine values returned to normal in the controls (Table-1).

Figure 1: CK; Creatin Kinaz(reference:20- 180 U/L), Kreatinin(reference: 0.5-0.9 mg/dl)

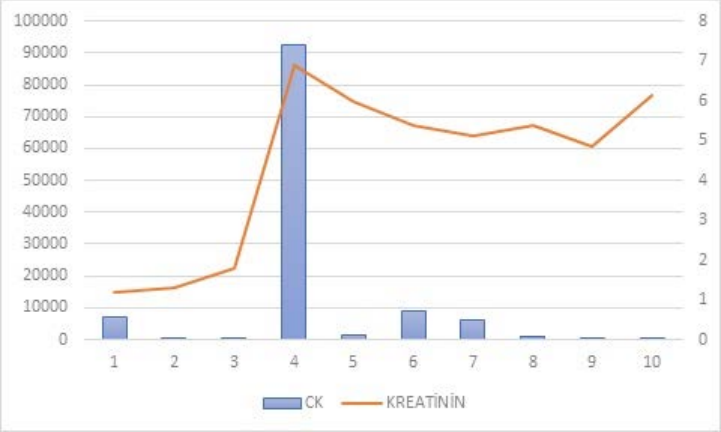

Figure 2 : AST; Aspartat Aminotransferaz (reference: 0- 32 U/L),ALT ; Alanin aminotransferaz(reference: 0- 33 U/L)

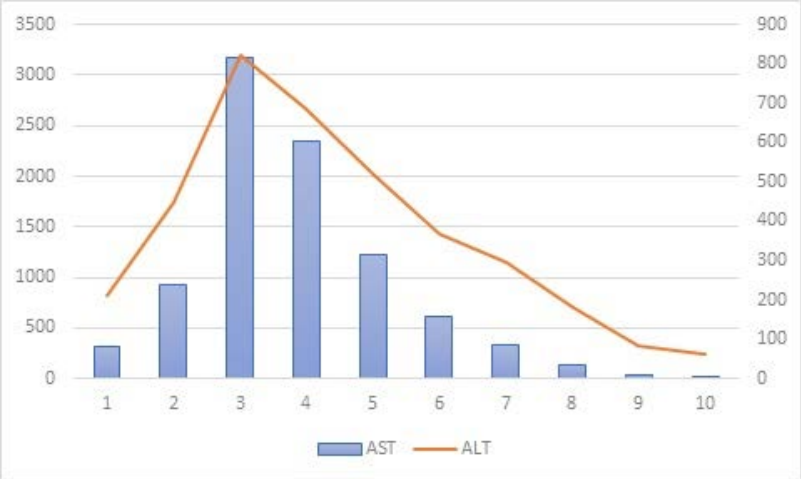

Figure-3 :LDH: Laktat dehidrogenaz (reference: 135-214 U/L), INR : International Normalized Ratio

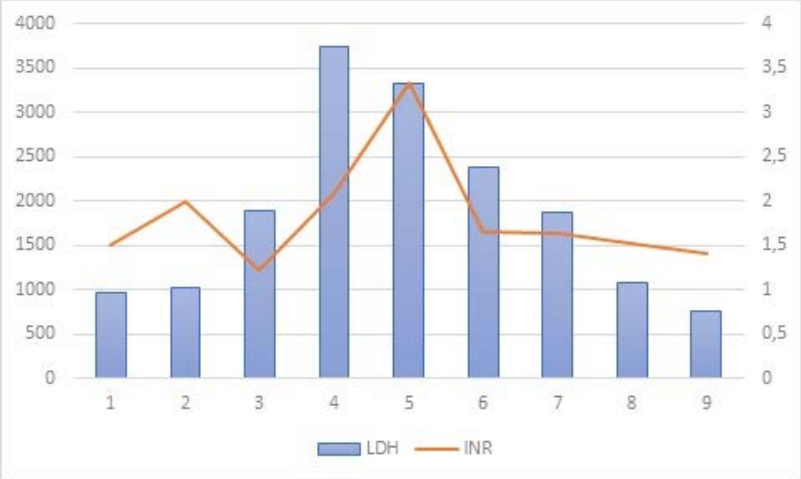

Table-1: Creatinine levels(mg/dl) from the moment of admission to the hospital

Days	1	3	5	7	9	11	13	15	17	19	21	23	25	27	44
Creatinin	1,2	1,2	5,99	5,1	5,4	6,12	6,47	7,06	6,66	5,24	5,01	3,11	1,79	1,67	0,8

DISCUSSION - CONCLUSION: Rhabdomyolysis is difficult to treat in COVID-19 patients. Aggressive fluid administration may worsen oxygenation, especially in patients with acute respiratory distress syndrome (ARDS). Bolus intravenous fluids can be given to patients with close clinical observation, continuous monitoring of oxygen saturation, and serial blood work for creatinine and CK. A small number of patients may require dialysis

Keywords: Covid-19, Rhabdomyolysis, Renal failure, İntensive care unit

Pub No: O-056

Our Airway Management In The Patient With A History Of Mandibula Excision And Multiple Surgery In The Neck Due To Fibrosarcoma

Salih Ayberk ÖZER[1]

[1]SBÜ Kocaeli Derince EAH

INTRODUCTION - PURPOSE: Difficult airway was defined as difficulty with face mask ventilation, difficulty with tracheal intubation, or both.(1) In this case, we planned to discuss our awake nasal intubation experience in a patient with cervical anatomical disorders in the light of the literature.

MATERIALS AND METHODS: A 44-year-old female patient has a history of multiple neck surgery (thyroidectomy, mandibulectomy, partial excision of the maxilla). Cholecystectomy is planned. In the preoperative evaluation, the mallampati score was 4 and the mouth opening was <1.5 cm. Cervical CT imaging revealed a 5.3 mm stenosis (Photo: 1). The patient was evaluated as possible difficult ventilation/intubation. Fiberoptic bronchoscopic awake nasal intubation was planned as the primary method in airway management. The patient was started on 2 mg midazolam and 50 mcg fentanyl bolus, remifentanil infusion (0.1 mcg/kg/min) for sedation. Upper airway local anesthesia was provided with 100 mg nebulized lidocaine. A pediatric fiberoptic bronchoscope with a 6.0mm intubation tube was advanced from the right nasal cavity to the carina. Since it did not progress from the area with subglottic stenosis, intubation was achieved by repeating the procedure with a 5.0 mm tube.

Before intubation



Sagittal ct image



Post intubation image



RESULTS: We believe that the awake nasal fiberoptic intubation method can be used safely in patients with anatomical disorders in the cervical region and limited mouth opening.

DISCUSSION - CONCLUSION: The use of supraglottic airway devices (SGAD) is one of the methods in patients who are expected to have a difficult airway. In our case, a mouth opening of <1.5 cm was considered as a difficulty in possible SGAD placement. Our patient was evaluated as a suitable candidate for awake intubation according to the DAS (Difficult Airway Society) difficult airway algorithm (2). Awake intubation is basically performed with fiberoptic bronchoscopy. The limited mouth opening in our case led us to nasal intubation with fiberoptic bronchoscopy.

Keywords: awake intubation, fiberoptic bronchoscopy

Pub No: O-057

A Case Of Benign Descending Necrotizing Mediastinitis

Elif Aybike AYYILDIZ[1], Ferhat ERENLER[2], Meltem TÜRKAY[3]

[1]İstanbul Medical Sciences University Kanuni Sultan Süleyman Research and Training Hospital
[2]Bakırköy Acıbadem Hospital
[3]Medipol University Bahçelievler Hospital

INTRODUCTION - PURPOSE: Descending necrotizing mediastinitis (DNM) is a rare but highly fatal condition. DNM is a rare infectious disease surrounds vital organs in the mediastinum. If not diagnosed in time and treated appropriately, it will cause fatal results. We aimed to present the case that we followed in the intensive care unit (ICU).

CASE: 30-year-old female patient applied to the emergency service after the root canal treatment, due to swelling on her face and a crackling sensation. She was diagnosed with mediastinitis after the thoracic and neck computed tomography (CT) imaging. She was admitted to the ICU for close follow-up. The patient was conscious and cooperative. Although she had obvious swelling on the right side of her face, she was hemodynamically stable. Crepitations were palpated from the right side of the neck to the shoulder region. She was evaluated by thoracic surgery, dental, ENT and infectious diseases department (IDD). The dental clinic recommended closure of the tooth and no surgical intervention. Daily thoracic CT was recommended. Antibiotherapy including vancomycin, clindamycin and meropenem was started by IDD. On the 2nd day, swelling and crepitation decreased. On control CT, emphysema in the subcutaneous tissue of the neck and between the intermuscular fascia and pneumomediastinum in the thorax continued. On the 3rd day, the swelling on her face continued to decrease, and the crepitation disappeared. A significant regression of pneumomediastinum was detected in thorax CT. She was transferred to the thoracic surgery clinic on the 6th day.

DISCUSSION - CONCLUSION: DNM, although rare, is a highly fatal condition in case of delayed diagnosis and treatment. The mortality is high as 40-50% and multidisciplinary approach needed. Treatment consists of antibiotics, surgical debridement and drainage. Our patient responded well to antibiotic therapy. There was no need for surgical intervention.

Keywords: mediastinis, pneumomediastinum, root canal treatment

Pub No: O-058

Posterior Reversible Encephalopathy Syndrome; 29 Weeks Pregnant: Case Report

Beril PİRİNA KARAKİRAZ[1], Tuba KUVVET YOLDAŞ[1], Semra KARAMAN[1]

[1]Ege Üniversitesi Tıp Fakültesi Hastanesi

INTRODUCTION - PURPOSE: Posterior reversible encephalopathy syndrome(PRES) characterized by neurological symptoms(headache,labile mental state,epilepsy,visual disorders)and edema typically in the occipitoparietal region of the brain is clinically and radiologically reversible disease.Early diagnosis and treatment of PRES is important against neurological sequels.Aim of this case is to present the anesthesia management in emergency cesarean section of a pregnant patient diagnosed with PRES.

CASE: The pregnant woman,who was 27years old,160cm,74kg,29 weeks and 3 days, applied to EUTF emergency service with headache, high blood pressure(170/90 mmHg) and lack of space-time orientation.During the follow-up of the obstetrics-gynecology service the patient, who was diagnosed with breech presentation and preeclampsia,had two generalized tonic-clonic seizures. Oxygen support was provided after SpO_2 was 78%.1/2 amp diazepam was applied to the patient.As a result of the detection of fetal bradycardia (90 beats/min) in the control USG,it was decided to have an emergency cesarean section.In the preoperative anesthetic examination, the consciousness was confused.Heart rate:123beats/min, NIBP:160/80mmHg,SpO_2:88% in room air. The patient with hypoplastic MDS did not use regular medication. Laboratory results were normal.In ABG pH:7.49,pO_2:55mmHg,pCO_2:25mmHg,SaO_2:91%.After preoxygenation, 350mg thiopental sodium and 75 mg rocuronium were administered,by rapid serial induction was achieved. Sevoflurane 1 MAC,80% 0_2,fentanyl(1mcg/kg) was used in the maintenance. Hemodynamics parameters were stable throughout the operation,which lasted 60min. At the end of the operation, she was extubated using sugammadex(2mg/kg). She was delivered to ICU with 0_2 support in non-cooperative.Control cranial MRI showed more prominent bilateral parietal cortical vasogenic edema on the right,thickening of the gyri, and increased signal in the FLAiR.When evaluated together with the clinic, the findings were found to be compatible with PRES.After 12 days of follow-up, she was discharged without complications.

DISCUSSION - CONCLUSION: Although there are many etiological causes, it should be kept in mind that PRES may develop when additional and unusual neurological symptoms occur in pregnant women with diagnosis of preeclampsia/eclampsia.

Keywords: Pregnancy, Preeclampsia, Posterior Reversible Encephalopathy Syndrome, Seizure

Pub No: O-059

Opioid-Free Anesthesia Under Upper and Lower Extremities Nerve Block Combined with General Anesthesia in Pediatric Orthopedic Surgery: A Case Series

Mehmet Sari[1], Seza Senturk[2]

[1]Özel Florya Cerrahi Tıp Merkezi
[2]Canakkale Onsekiz Mart University, Faculty of Medicine

INTRODUCTION - PURPOSE: Peripheral nerve blocks are increasingly trending to supplement perioperative analgesia in component of opioid free anesthesia pediatric patients. Opioid-free anesthesia (OFA) is a multimodal technique that eliminates the need for opioids. In adults, studies have shown that OFA reduces opioid-related adverse events. In children who undergoing orthopedic surgery, there are rare publications on opioid-free anesthesia with USG-guided upper and lower extremity blocks.In this study, we aimed to share our experience of opioid free anesthesia with USG guided lower and upper extremity nerve blocks and analgesia in our clinic.

MATERIALS AND METHODS: This study was performed in our clinic. This case series was comprised of 15 consecutive patients who underwent orthopedic surgery with USG-guided peripheral nerve block for extremities fracture in our clinic between January 1, 2020 and September 31, 2020. 11 anesthetic records contained the indication of a USG- guided pediatric peripheral nerve block in OFA. 4 patient excluded for missing date. Their post-op 0. hour and post-op 2. hour visual analog scale for pain intensity and family satisfaction were assessed. Data were collected using anesthesia follow-up forms . No abnormality was observed in perioperative hemodynamic parameters. Nerve block was routinely performed after induction in accordance with safe regional anesthesia procedures. After 20 minutes, incision was allowed. There were no deaths or complications.

RESULTS: In the present study performed on children orthopedic surgery, an opioid-free strategy using a combination of sevoflurane and USG- guided periferal nerve block offers effective and reliable anesthesia along with a stable intraoperative hemodynamic response, postoperative pain control and family satisfactions

Patients' outcomes

Age (Year)	Weight (kg)	Surgery	Block type	Drug concentration % / type	Postop 0. hour (VAS 0-10)	Postop 2. hour (VAS 0-10)	Parent Satisfaction (1-5)
11	41	Femur fracture	femoral +lcfn* block	0.25 bupivacaine	0	2	5

9	37	Radius-ulna distal fracture	infraklavikular block	0.25 bupivacaine	0	1	5
9	35	Tibia fracture	popliteal block	0.25 bupivacaine	1	1	4
11	42	Supracondiler fracture	infraklavikular block	0.25 bupivacaine	1	3	4
13	40	Supracondiler fracture	infraklavikular block	0.25 bupivacaine	0	0	5
9	37	Femur fracture	femoral +lcfn* block	0.25 bupivacaine	0	1	4
16	70	Femur fracture	femoral +lcfn* block	0.5 bupivacaine	0	0	5
9	35	Radius-ulna distal fracture	infraklavikular block	0.025 bupivacaine	0	0	5
8	29	Radius-ulna distal fracture	infraklavikular block	0.01 bupivacaine	0	1	5
12	40	Radius-ulna distal fracture	infraklavikular block	0.01 bupivacaine	0	2	3
12	43	Radius-ulna distal fracture	infraklavikular block	0.01 bupivacaine	0	0	5

DISCUSSION - CONCLUSION: These case series suggest that USG-guided peripheral nerve block application is an option that may be considered for opioid-free anesthesia in pediatric patients. Further randomized, controlled studies are needed to obtain conclusive evidence, its use OFA in pediatric patients.

Keywords: Opioid free anesthesia, Pediatric nerve block

Pub No: O-060

The Comparison Of Propofol, Propofol Remifentanil And Propofol Ketamine Combination's Effects On Electroconvulsive Treatment

Ali SARI[1], Kasım TUZCU[2]

[1]Abdulkadir Yüksel Devlet Hastanesi
[2]Lara Anadolu Hastanesi

INTRODUCTION - PURPOSE: Electroconvulsive therapy is a short-term procedure. For this reason, the anesthetics used should be short-acting and the patient should recover quickly. The duration of the seizure that occurs during ECT is important in the effectiveness of the treatment. Therefore, the drugs used should not shorten this period. In our study, we aimed to compare the effects of low-dose remifentanil or ketamine added to propofol during ECT on the increase in intraocular pressure, hemodynamic response and seizure duration during ECT.

MATERIALS AND METHODS: The study was carried out on a total of 30 patients, 9 male, who were treated with ECT in Mustafa Kemal University Faculty of Medicine, Department of Anesthesiology. In the study, the patients were divided into three groups; For muscle relaxation, 0.5 mg/kg succinylcholine was used in all groups. Grup1: 0.75 mg/kg propofol as an IV slow infusion in 15 seconds. Grup2: 0.75 mg/kg propofol+5 µcg/kg remifentanil combination as an IV slow infusion. Grup3: 0.75 mg/kg propofol+0.5 mg/kg ketamine combination as an IV slow infusion. Three sessions of ECT were applied to each patient. With crossmatching, the order of the sessions was equally distributed in all three groups. Seizure duration, hemodynamic response, recovery, apnea duration and intraocular pressure values were compared between the groups.

RESULTS: There was no significant difference between the groups when systolic and diastolic arterial pressure, intraocular pressure measurements and seizure duration were compared ($p > 0.05$). Group 1 was the fastest compiled in terms of recovery times ($p < 0.01$).

DISCUSSION - CONCLUSION: It was observed that when propofol was used at the minimum hypnotic dose during ECT, it did not shorten the seizure duration and provided rapid recovery. It is not statistically significant that ketamine is superior in terms of seizure duration in ECT, but our observation was that patients who did not have seizures had seizures with the ketamine propofol group.

Keywords: Electro Convulsive Treatment(ECT), Seizure Duration, Seizure Duration, Propofol, Ketamine

Pub No: O-061

Posterior Reversible Encefalopaty Syndrom (Pres) In Intensive Care Unit

Zuhal Çavuş[1]

[1]Gaziosmanpaşa EAH

INTRODUCTION - PURPOSE: PRES,which presents with seizure,headache,nausea and vomiting,mental status changes,visual loss, and focal motor loss,was first described in 1996(1).Etiology may be cerebral autoregulation disorder and endothelial dysfunction,related vasogenic cerebral edema(2).Causes include hypertensive encephalopathy,preeclampsia,eclampsia,immunosuppressive/cytotoxicdrugs,collagen vascular diseases,liver failure,massiveblood transfusion(3).This syndrome, which results in full recovery when diagnosed on time,should be kept in mind in the differential diagnosis.In this case report,we wanted to draw attention to PRES syndrome by describing our case in ICU.

CASE: A72-year-old female patient with a history of COPD and hypertension was charged to ICU with diagnosis of septic shcok.She was intubated due to the deepening of his acidosis and increased PCO2.İnotropic support and antibiotics were started.After 2 days therapy,inotropic support was discontinued and extubated.On the 4th day,generalizedseizure and unconsciousness developed following vision loss.The patient had recurrent seizures during the day,recovered with midazolam.In the diffusion magnetic resonance (MRI),minimal edema in the bilateral parietooccipital lobes and signal changes were observed.Levetiracetam was started in the patient who was thought to have PRES syndrome in the neurology consultation.In the diffusion MRI examination done 1 day later,the findings regressed. She did't have seizures,was discharged in 2days.

BT image of patient

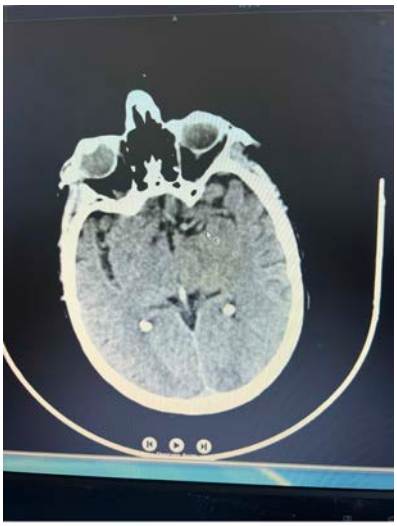

MRI image of case

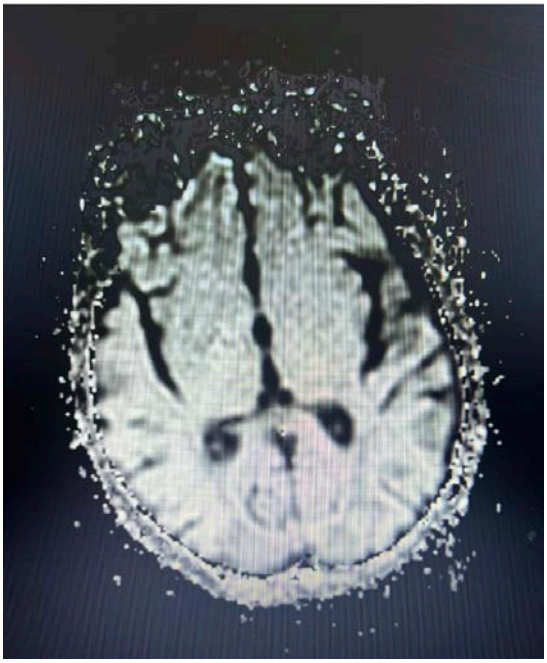

DISCUSSION - CONCLUSION: We presented PRES syndrome in a patient in ICUwith the diagnosis of septic shock.Due to non-specific symptoms,PREShas similar clinical features with differentconditions such as stroke, encephalitis,and venous thrombosis.Differential diagnosis should be made with stroke,encephalopathies,TIA and migraine.Our patient's symptoms were vision loss,epileptic seizures.The diagnostic imaging method in PRES is MRI.Symmetrical subcortical whitematter edema on MRI often accompanies brainstem and cerebellum involvement(5).Pathological imaging findings of PRES regress with treatment.It is possible to confirmPRES with repeated imaging.In our patient,regression in pathology was also observed on recurrent radiographs.In this case report,we presented PRES syndrome in ICU.We wanted to draw attention to this syndrome,which is more familiar to neurologists, we do not see frequently in ICU.

Keywords: PRES, INTENSİVE CARE UNİT, MRI

Pub No: O-062

Non-Cirotic Esophageal Variceal Bleeding: Factor V Leiden Mutation

Murat ÜNSEL[1], Hatice ASOĞLU RÜZGAR[1], Susan GÜNAYDIN GENCER[1], Güldem TURAN[1]

[1]Intensive Care / Anesthesiology and Reanimation Clinic Başakşehir Çam and Sakura State Hospital, İstanbul, Turkey

INTRODUCTION - PURPOSE: Portal vein thrombosis (PVT) is one of the causes of portal hypertension. Thrombophilic abnormalities may have a role in the development of PVT. Factor V Leiden (FVL) mutation in the hereditary domain is the most frequently questioned etiological factor in thrombophilic people (1-2).

CASE: A 42-year-old male patient who known had FVL heterozygous mutation and had a history of splenic vein thrombosis was admitted with esophageal variceal bleeding while using 20 mg rivaroxaban. Band ligation was performed on varicose veins with diffuse grade 3 bleeding in endoscopy. Splenic artery embolization was performed in the patient whose bleeding recurred. TIPS (Transjugular Intrahepatic Portosystemic Shunt) was performed when a thrombus was seen in the portal vein in doppler USG which was performed on the 15th day of hospitalization (Picture 1-2). The patient passed away on the 24th day of his hospitalization due to liver failure. During his follow-up,32 U of erythrocyte suspension was given to the patient.

Picture 1 Venaportagraphıc

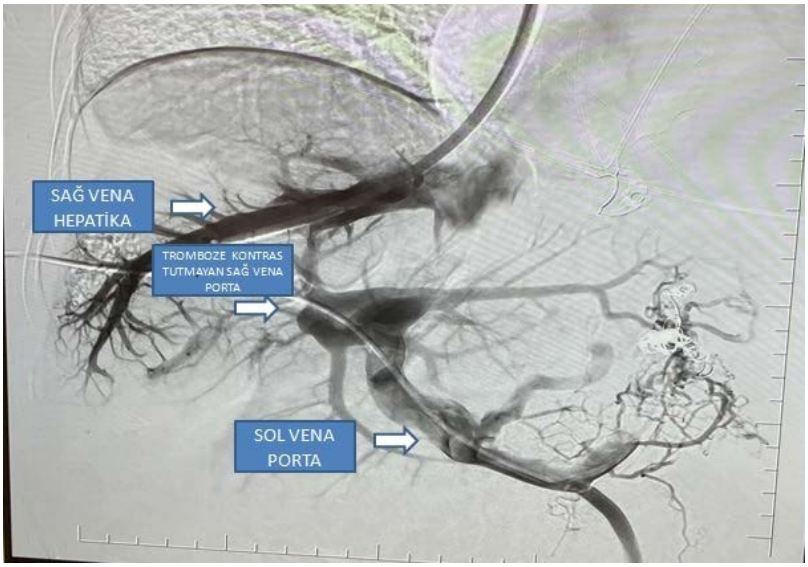

Picture 2 Dilatation

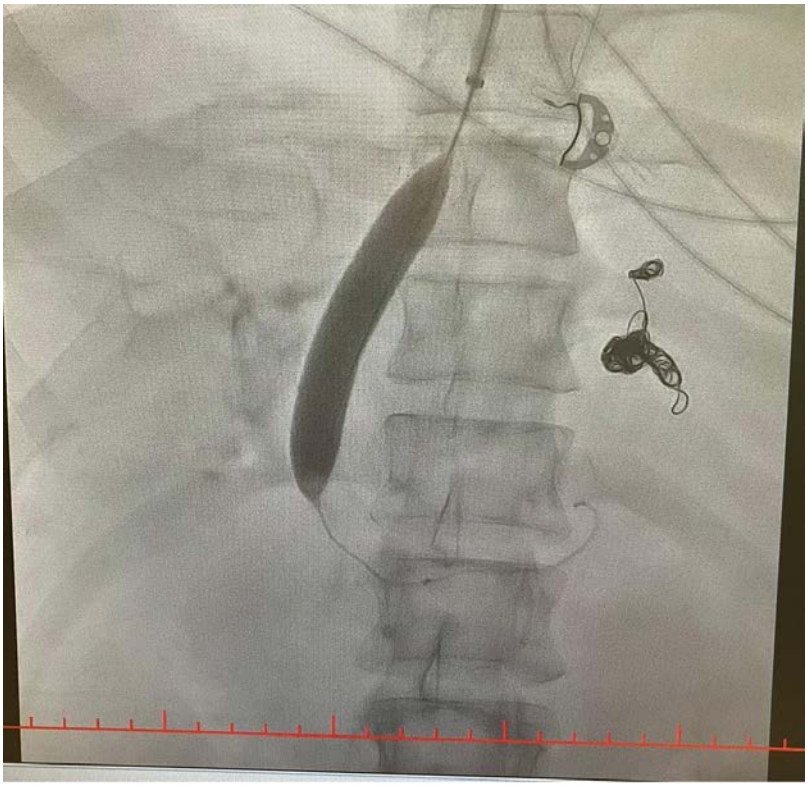

DISCUSSION - CONCLUSION: FVL mutation is the most common hereditary cause of unexplained venous thrombosis, its incidence is %4.8 in the general population, and the risk of thrombosis is 7 times higher in those with FVL heterozygous and 80 times in those with homozygous (3). Portal hypertension is also a common complication in chronic PVT and patients who have PVT present with esophageal variceal bleeding (OVB)(4). Our patient had OVB while using rivoraxaban, and despite medical treatment, endoscopic band ligation, arterial embolization and TIPS, the patient died due to liver failure. As a result, in patients with esophageal variceal bleeding due to thrombolytic diseases, it is difficult to treat cases between thrombosis and bleeding dilemma, and cases are usually lost due to complications secondary to thrombosis.

Keywords: Thrombophili, Factor V Leiden Mutation, Esophageal Variceal Bleeding

Pub No: O-063

A Rare Case : Elephantiasis Nostras Verrucosa

Murat ÜNSEL[1], Feyzullah KOLAY[1], Güldem TURAN[1]

[1]Intensive Care / Anesthesiology and Reanimation Clinic Başakşehir Çam and Sakura State Hospital, İstanbul, Turkey

INTRODUCTION - PURPOSE: Elephantiasis nostras verrucosa (ENV) is a rare form of chronic lymphedema.Neoplasm, trauma, radiation therapy, congestive heart failure, obesity, hypothyroidism, chronic venous stasis and various factors such as filarial infection can cause secondary lymphedema.

CASE: 48 years old female, obesity patient was diagnosed cervix ca and receive 2 times chemotherapy, 1 times radiotherapy. The patient presents to hospital with fever urinary incontinance and swelling on right leg. Deep vein thrombosıs was not detected radiologically in the patient who was treated with a prediagnosis of sepsis. The patient, whose general condition deteriorated on the 3rd day of her arrival, was admitted to İntensive Care Unıt as intubated with prediagnosis of sepsis .right leg measured 50 cm, left leg was 40 cm (above the patella). A lesion was detect that start from vulva and spreads to the inguinal region in the patient. A skin biopsy was taken from the patient who was consulted to dermatology, was diagnosed as evd.our patient died on the 24th day of follow up

DISCUSSION - CONCLUSION: ENV is rare chronic form of lymphedema. Diagnosis is made by anamnesis, skin changes and histopathology. Differential diagnosis was made with normal thyroid hormones (pretibial myxedema), no history of traveling to tropical countries (filariasis), unilateral(lymphedema), histopatology (chromoblastomycosis, lipodermatosclerosis and venous stasis dermatitis). The right leg had lichenification; a hardened, cobblestone-like lesions (Picture 1) and Kaposi-Stemmer sign (Failure to pinch the dorsal aspect of the skin at the base of the second toe) (Picture 2). Compression stocking, intermittent compression stocking, diuretics and systemic antibiotics may be request in the treatment of lymphostasis. Hyperkeratotic plaques can be treated with topical keratolytics or systemic retinoids. The prognosis of ENV depends on the severity of lymphedema, underlying diseases, and other contributing factors.

(Picture 1) Cobblestone-like lesions



Picture 2 Kaposi-Stemmer sign



Keywords: malignancy. obesity, lymphedema

Pub No: O-065

Intrathecal Catheter Insertion After Accidental Dural Puncture

Şeyma Sayıt[1], Ferhunde Dilek Subaşı[2]

[1]Istanbul Bahcelievler State Hospital
[2]Istanbul Emsey Hospital

INTRODUCTION - PURPOSE: Epidural anesthesia is one of the most commonly method in lower extremity orthopedic surgeries. A complication of this procedure is an accidental dural puncture(ADP) which can result in a post-dural puncture headache(PDPH) in patients. There is no clear consensus exists on how to best prevent severe headache from occurring after accidental dural puncture.

CASE: 55 years of age, female patient who has hypertension and is going to undergo left gonarthrosis operation was prapared for combined spinal-epidural anesthesia. 10ml %0,9 NaCl per kg was given to patient introvenously before the procedure. The patient is seated and then the subarachnoid space was accidentally entered in the first attempt at a depth of 6cm from the skin with the 18G Tuohy epidural needle using the loss of resistance syringe (filled up with saline) method from the L4-L5 spinal space. 0.5% hyperbaric bupivacaine was applied to the subarachnoid space and then epidural catheter was placed in the intrathecal space. The operation was completed without any problems. Catheter was never used peroperative and postoperative period. The epidural catheter placed in the spinal space was removed 24 hours after the operation. The patient had no headache in 2 weeks period postoperatively.

DISCUSSION - CONCLUSION: A therapeutic epidural blood patch(TEBP) is the most effective treatment option for patients after ADP and with unsuccessful conservative management such as hydration, caffeine, analgesic medication, and bed rest. In recent years; insertion of an intrathecal catheter that was left in place for several hours following ADP has gained popularity[1]. It has been suggested that placement of a spinal catheter through the perforation may provoke an inflammatory reaction that will seal the hole. Evidence to support this claim is conflicting[2]. In our case there is no need TEBP and no headache was observed after insertion of an intrathecal catheter.

Keywords: post-dural puncture headache, accidental dural puncture, intrathecal catheter

Pub No: O-066

The Factors Affecting Morbidity and Mortality in Hip Fractures

Esra Akdaş Tekin[1], Fethi Gültop[1]

[1]SBÜ,Prof Dr Cemil Taşçıoğlu City Hospital,Anesthesia and Reanimation Clinic

INTRODUCTION - PURPOSE: In the study, perioperative processes of patients who underwent surgery for hip fracture were analyzed retrospectively in terms of mortality and morbidity.

MATERIALS AND METHODS: The surviving patients were accepted as Group I (n=30), and the deceased patients as Group II (n=15). Groups, demographic data, ASA, APACHE II, GCS, co-morbidities, preoperative Hb, platelet, time/day between hip fracture and operation time, anesthesia method, intraoperative events (hypotension, hypertension, arrhythmia), amount of bleeding,the need for intensive care, the need for mechanical ventilation, the complications seen in the intensive care unit (bleeding, hypotension, arrhythmia, hypoxia) were recorded and the data were compared in terms of mortality.

RESULTS: No difference was found between the demographic data of the groups.(Table1) Spinal anesthesia was applied to all patients and they were followed up in the postoperative intensive care unit. Group II patients had higher APACHE II than Group II patients. While preoperative ASA and GCS scores were not associated with mortality, APACHE II was associated with mortality ($p<0.001$). There was no difference between the groups between intraoperative and postoperative complications ($p>0.05$)(Table 2).

Table 1

	Group I (n=30)	Group II (n=15)	p
Gender Male Female	6 14	9 6	0.671
Age	81.56±6.71	82.64±9.18	0.663
BMI	19.26±1.48	19.92±1.94	0.219
APACHE II	20.73±2.89	28.78±1.76	<0.001***
GCS	14.06±0.69	14.21±0.69	0.515
Preop Hb (gr/dL)	9.6±1.19	10±1.24	0.312
Preop PLT	100±13.77	97.5±13.40	0.575
Time to operation (day)	6.18±3.56	7.92±3.16	0.125
Amount of bleeding (ml)	618.33±356.82	792.85±316.74	0.125
Anesthesia type Spinal General	 30 _	 15 _	
Operation Time (hr)	2.36±0.55	2.35±0.49	0.957

Demographic data and operative details

Table 2

	Group I	Group II	p
Hypotension (n=)	3	2	
Hypotension time (min.)	16.46±5.32	14.42±4.53	0.223
Cardiac arrhythmia			
Cardiac arrhythmia time (min.)	3.36±1.49	3.42±1.65	0.902
Hypoxia			
Hypoxia time (min)	2.6±1.45	2.92±1.54	0.497
Intensive care (n=)	30	15	
Ventilator use >48h (n=)	3	3	
PONV (n=)	3	3	

Comparison of intraoperatif complications in terms of mortality

DISCUSSION - CONCLUSION: Hip fractures cause significant morbidity and are associated with increased mortality(1,2,3). As seen in our study, it has been shown that there is no relationship between the anesthesia method applied and mortality. It is known that the effect of patient factors on the results of surgery is more important(4,5). Intraoperative hypotension is common. However, the relationship between the duration of hypotension and mortality could not be demonstrated. Although it was determined that postoperative mortality was significantly increased in patients with preoperative renal dysfunction or failure and low hemoglobin value, no difference was found between the groups in the amount of preoperative hgb and intraoperative bleeding, in our study (5)The application of the preoperative APACHE II will guide the identification of risky patients and the optimization of perioperative patient management.

Keywords: hip fractures, surgery, anesthesia, mortality

Pub No: O-067

Neurology Screening of Nutritional Status of Patients Applying to the Adult Neurology Outpatient Clinic of a University Hospital

Ümit CENGİZ[1], Hamza GÜLTEKİN[1], Mehmet Uğur ÇEVİK[1]

[1]Dicle University Faculty of Medicine Neurology Clinic

INTRODUCTION - OBJECTIVE: Malnutrition; It is the situation in which body structure and functions are measurably adversely affected due to insufficient, unbalanced or excessive intake of energy, protein and other nutrients. In this study, we aimed to determine the frequency of malnutrition in patients with neurological diagnosis who applied to the neurology outpatient clinic.

MATERIALS AND METHODS: All patients over the age of 18 who applied to the neurology outpatient clinic were included in this study. NRS-2002 (Nutritional Risk Screening) test was applied to patients under 65 years of age, and MNA (Mini Nutritional Assessment) test was applied to patients aged 65 and over. Patients with an NRS score of 3 and above and an MNA score of less than 24 were considered at risk of malnutrition. Age, gender, marital status, number of diseases, smoking, drug use history, weight, height and current diseases of the patients were recorded.

RESULTS: The total number of patients included in our study was 519. The number of patients at risk of malnutrition was 41 (7.9%). Of the patients at risk, 19 (46.3%) were female and 22 (53.7%) were male. In all patients included in the study, 2.3% of those at risk of malnutrition had neurovascular disease, 2.4% had neurodegenerative disease, 2.8% had neuromuscular disease, and 1.1% had other neurological diseases.

DISCUSSION - CONCLUSION: The risk of malnutrition was found to be between 4.5% and 28.6% in patients who applied to the neurology outpatient clinic. We think that these neurological diseases, drugs used and other comorbid causes may pose a risk of malnutrition. Malnutrition is common in patients hospitalized in intensive care and service. However, outpatient outpatients may be overlooked. For this reason, we think that easy-to-use NRS-2002 and MNA tests will be useful in determining the risk of malnutrition in patients who apply to the outpatient clinic.

Key words : malnutrition , neurology , NRS-2002, MNA

References:

1- Selçuk, Zülfiye Gizem. Erişkin bakım yoğun ünitesinde yatan hastalarda beslenme durumlarının nütrisyonel risk kullanımları 2002 ve modifiye nütrik skor değerlendirilmesi kullanılarak. MS tezi. Balıkesir Üniversitesi Sağlık Bilimleri Enstitüsü, 2021.

2- Guaitoli, Patrícia Realino, Elise P. Jansma, and Henrica CW de Vet. "Nutrition screening tools: does one size fit all? A systematic review of screening tools for the hospital setting." *Clinical nutrition* 33.1 (2014): 39-58.

Pub No: O-068

The Key Role Of Fiberoptic Intubation In A Patient With Lockjaw

Hilmi AKDAĞ[1], Ahsen GÜR[1], Korgün ÖKMEN[1]

[1]University of Health Sciences, Bursa Yuksek Ihtisas Training & Research Hospital

INTRODUCTION - PURPOSE: In the treatment of head and neck region cancer, surgery, chemotherapy and radiotherapy are commonly used combined(1). Among these treatments, cervical contracture, temporomandibular joint disability and muscle damage may occur, especially due to radiotherapy. We aimed to present our experience in providing a safe airway by using difficult airway management techniques in a patient with a history of radiotherapy to the head and neck region.

CASE: 38-year-old male patient with a history of myelodysplastic syndrome and tongue cancer. After the development of panophthalmia in the right eye, he was taken to the operating room with an enucleation plan. On physical examination, it was seen that there was no mouth opening due to radiotherapy scars. The patient also had neck range of motion limitation. The patient stated that he could be fed liquid foods with a pipette for years. Preoperative difficult airway preparations were made. A loading dose of 1.5mg/kg dexmedetomidine was administered to the patient who was scheduled for awake intubation with a fiberoptic bronchoscope. 6o mg of lidocaine was given by inhaler, nasal topical anesthesia was also administered. Fiberoptic nasotracheal intubation was successfully performed.

DISCUSSION - CONCLUSION: In cases of expected difficult intubation, the recommended method in the guide of the American Society of Anesthesiologists (ASA) is awake intubation (2). Fiberoptic intubation remains the gold standard. Studies have shown that awake nasotracheal intubation fails in 1.8% of cases. In another study, the failure rate in awake intubation was 1% and the complication rate was 1.6% (3). In our case, considering the failure of nasotracheal intubation, the otolaryngology clinic was informed and emergency tracheostomy preparation was made. While nasal airway could be useful in ventilation, it could not be included in our difficult airway preparation because it was not available in our hospital.

Keywords: radiotherapy, head neck cancer, fiberoptic intubation, difficult airway

Pub No: O-069

Delayed Awakening From Anesthesia Due To Acute Epidural Hematoma After Posterior Fossa Tumor Surgery: A Case Report

Ceren Nur DUYGUN ŞAHİN[1], Adil Uğur YAVUZ[2], Ahmet BEŞİR[1]

[1]Karadeniz Technical University Faculty of Medicine Farabi Hospital, Anesthesiology and Reanimation Clinic
[2]Karadeniz Technical University Faculty of Medicine Farabi Hospital,Neurosurgery Clinic

INTRODUCTION - PURPOSE: Posterior Fossa tumors (PFT) are a brain tumor that can be seen at any age in the region where anatomically vital function structures are located(1). Acute epidural bleeding after PFT surgery is a rare condition(2,3). In this case, acute epidural surgery occurred in the early period after PFT surgery. We shared the prolonged recovery process due to hematoma .

CASE: 52-year-old patient with diagnosed breast cancer and diabetes was diagnosed with a 32x25 mm posterior fossa mass in the left cerebellar hemisphere in the imaging performed due to headache, dizziness, and difficulty in walking(Figure 1). Surgery was decided by neurosurgery. In the preoperative examination, Glasgow Coma Score(GCS) was 15, conscious, oriented, cooperative, pupillary evaluated as isochoric. Physical examination and laboratory tests were normal. Standard monitoring, temperature, TOF, BIS and invasive arterial blood pressure monitoring were performed. Total intravenous anesthesia was applied and the patient was placed in the prone position. Antiedema treatment was applied. His hemodynamics remained stable throughout the operation(180 min) . At the end of the case, after all drugs were reversed, he was extubated with spontaneous respiration. Modified Aldrete score could not go above 8, and all causes that could cause delayed recovery were excluded in the patient with a GCS of 11. He was transferred to the intensive care unit (ICU). On CT , epidural hemorrhage reaching 7 mm was detected in the right parioteoccipial region(Figure 2). Follow-up by neurosurgery was recommended. On the 2nd day of the ICU follow-up , it was seen that the bleeding had decreased in the control CT . After the patient was sent to the service, he was discharged with recovery(Figure 3).

Fig.1 Posterior fossa tumor in the patient's preoperative Computerized Tomography



Figure 2. The epidural bleeding area of the patient that developed in the early postoperative period



Figure 3: Computerized Tomography of the brain before discharge

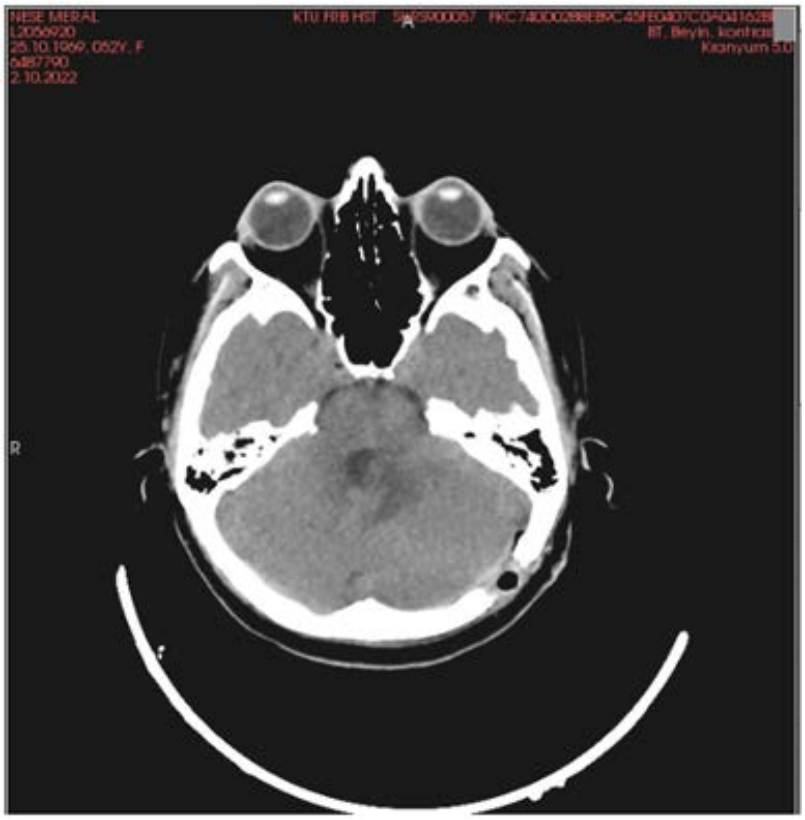

DISCUSSION - CONCLUSION: Epidural hematoma after PFT surgery is a rare complication(2,3). Especially in the early postoperative period, the possibility of epidural hematoma should be kept in mind among recovery problems.

Keywords: posterior fossa tumor, epidural bleeding, anesthesia

Pub No: O-070

Anesthesia Management İn Glucose-6 Phosphate Dehydrogenase Deficiency: Case Report

Abdurrahman TÜNAY[1], Şenay KIRGEZEN[1], Mehmet TOPTAŞ[1], Mensure ÇAKIRGÖZ[2]

[1]İstanbul Education and Research Hospital
[2]İzmir Katip Çelebi University Atatürk Education and Research Hospital

INTRODUCTION - PURPOSE: The most common enzyme deficiency Glucose-6 Phosphate Dehydrogenase (G6PD)(1) shows recessive passage depending on X,and it is much more common among female gender(2) . In case of G6PD deficiency, erythrocytes have oxidative stress an d they become unable to keep glutathione in the reduced state(3,4).The medication used during the peroperative period and surgical stress may cause hemolytic crisis. In this case ,we wanted to present our anesthesia management on a male patient aged 65 who has G6PD deficiency and is in need of a laparoscopic cholesystectomy operation.

CASE: Our patient's preoperative physical and test results were normal.Standard monitorization is done for the patient and he was then taken to the operation room.Anesthesia induction is done by intravenous (IV) 1mcg/kg fentanyl, 2mg/kg propofol, 0,6mg/kg rocuronium bromide..Anesthesia maintenance is done by %50 air %50 oxygen mixture and %2 sevoflurane. During the 55 minutes of the whole operation , no hemodynamic abnormalities occured. Then 2mg/kg IV sugammadex is applied , the patient is then extubated successfully and taken to the recovery room. He is at a stable condition both in hemodynamic and respiratory state. Then he was transferred to the general surgery service. Fort he postoperative pain treatment, we used 1mg/kg tramadol and 15mg/kg paracetamol IV. The service follow ups of the patient continued without any problems and he was discharged on a healthy state.

DISCUSSION - CONCLUSION: Fort he patients with G6PD enzyme deficiency who will be applied general anesthesia ;a detailed preoperative examination, reducing the level of stress which could be caused by the anesthesia, avoiding medication which may cause hemolytic crisis and frequent hemogram checks for early diagnosis of hemolysis has great and critical importance.Besides, taking the pain under control during the postoperative period is crucial to prevent surgical stress. We think that the anesthesia method we used is completely safe.

Keywords: G6PD, Anesthesia Management, Enzyme Deficiency

Pub No: O-071

Tooth Loss During Orotracheal Intubation: A Case Report

Havva KOCAYİĞİT[1], Fatih ŞAHİN[2]

[1]Sakarya University, Faculty of Medicine, Anesthesiology and Reanimation Departmant
[2]Sakarya Universty, Training and Research Hospital Anesthesiology and Reanimation Departmant

INTRODUCTION - PURPOSE: Perioperative dental injury is one of the anesthesia-related complications, and the overall incidence of dental injury is 0.059% (1,2). Most of these injuries occur during laryngeal mask application and orotracheal intubation (2).

CASE: The 64-year-old patient undergoing coronary bypass surgery was evaluated Mallampati-2 during the preoperative visit. There was no sign of a difficult airway. The patient, who had difficulty mask ventilation after induction, was quickly intubated. After laryngoscopy, it was observed that the upper incisor tooth fell out and bled from the tooth site. The patient was placed in trendelenburg to prevent its distal location. Afterward, the fiberoptic bronchoscope was advanced through the right nasal opening, and it was seen that the tooth was in the nasopharynx. C-arm fluoroscopy confirmed the tooth's location radiologically (Figure 1). Attempts were made to push into the oropharynx through the fiberoptic bronchoscope but failed. The consultant otolaryngologist removed the tooth in the nasopharynx with forceps.

Figure 1. X-ray image of the tooth indicated by the arrow

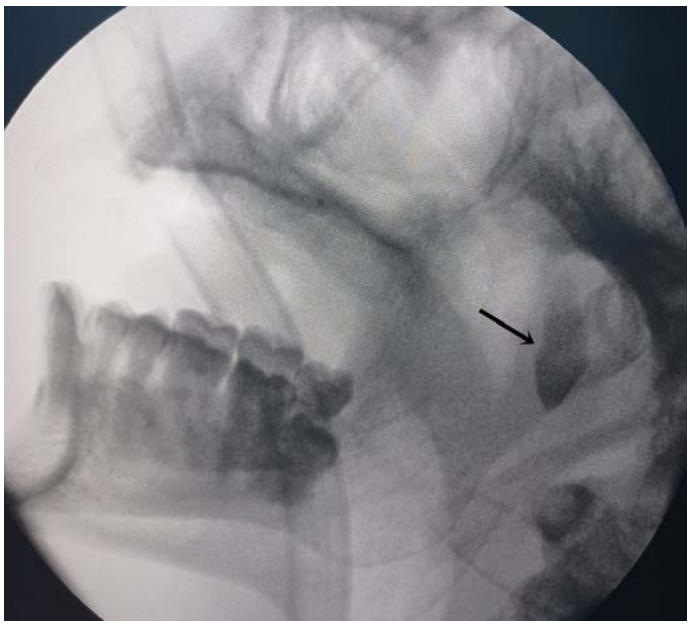

DISCUSSION - CONCLUSION: Perioperative tooth injury and loss are critical issues due to the possibility of developing pulmonary and gastrointestinal complications (3,4). Although case reports and studies have been published before, there is no clear intervention strategy for tooth loss. While Jiang et al. do not recommend a position change in order not to escape into the trachea and esophagus if a tooth is missing after laryngoscopy, they recommend X-ray imaging immediately for the tooth position (5). In a different publication, while the Trendelenburg position is recommended, it is also recommended to confirm the part of the tooth with fiberoptic bronchoscopy (6).As a result perioperative tooth loss should be recognized quickly, and possible complications should be prevented. If there is difficulty in removing the tooth by the anesthesiologist, we think it would be positive to evaluate and intervene with the otolaryngologist as a multidisciplinary.

Keywords: Toot loss, Intubation, Laryngoscopy, X-ray imaging

Pub No: O-072

SedLine EEG Monitoring in a Brain Injured Hanging Case

Gulcin Hilal Alay[1], Guldem Turan[1]

[1]University of Health Sciences, Basaksehir Cam and Sakura City Hospital Intensive Care Unit, Istanbul

INTRODUCTION - PURPOSE: The SedLine Sensor(Masimo Corporation; Irvine,CA,USA) is a device that has been used in recent years, both processing electroencephalogram(EEG) signals and determining a value defined as the Patient State Index(PSI) with these data, which numerically expresses the sedation depth. In this case report, we aimed to evaluate seizure activity in a patient with brain damage due to hanging.

CASE: A 30-year-old male patient was followed on mechanical ventilator due to hypoxic brain injury after suicidal hanging. The patient had myoclonic jerks. In order to understand whether these myoclonic jerks were epileptic activity, PSI value and 4-channel EEG were recorded with the SedLine sensor. Epileptic activity was detected during the recording. The patient was evaluated as status epilepticus and midazolam, propofol infusion, and antiepileptic therapy(valproic acid, topiramate, ebdantoin, phenytoin) were started. Antiepileptic treatment was increased until seizures were controlled. Sedation was tapered off. His seizures were controlled with quadruple antiepileptic therapy.

Epileptiform waves



Normal EEG waves

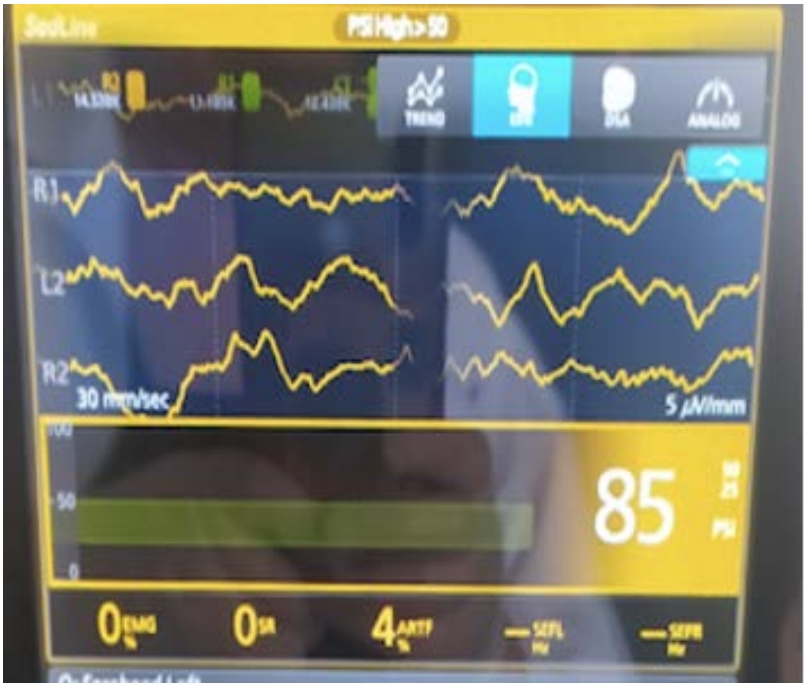

DISCUSSION - CONCLUSION: EEG signals processed with SedLine Brain Function Monitoring device (Masimo, Irvine,CA,USA) can be recorded. The key parameter displayed by SedLine is the Patient State Index(PSI), which has an index of depth of sedation ranging from 0 to 100. The deeply sedated patient with 0 isoelectric EEG in this index; 100 indicates a fully awake patient(1). In addition, the SedLine monitor displays the bilateral raw EEG trace, the bilateral density spectral array and the spectral edge frequency(SEF)(2), and the burst suppression rate(SR) by the device as a measure of signal quality. The percentage of detected artifacts, and electromyographic(EMG) activity can also be evaluated. The SedLine sensor is useful in detecting whether these movements are epileptic in patients who are followed up in intensive care for brain damage and myoclonic movements are observed. It is also a practical approach that can be used to detect the presence of non-convulsive statuses.

Keywords: Electroencephalogram, Hypoxic brain injury, Neuromonitoring

Pub No: O-073

Anesthesia Application During Magnetic Resonance Imaging In Patient With Angelman Syndrome (Happy Puppet).

Ayşe VAHAPOĞLU[1]

[1]SBÜ. GAZİOSMANPAŞA TRAINING AND RESEARCH HOSPITAL

INTRODUCTION - PURPOSE: Angelman syndrome(AS) is a neurogenetic disorder with a frequency of1/20,000-52,000characterized by a maternally inherited microdeletion of15q11-13 region.It manifests as mental retardation, delay in motor development, speech disorders, happy facial expression, large mouth, widely spaced teeth, wide-legged gait, sleep disorders, and epileptic seizures.In our study, we aimed to present a case with AS who underwent magnetic resonance imaging(MRI) under sedation.

CASE: A 9year-old male patient, suffering from seizures since the age of 2,taking two antiepileptic drugs, unable to sit or stand without support, unable to use his hands for personal hygiene, and diagnosed with AS and epilepsy, was to receive an MRI scan under anesthesia for the diagnosis of scoliosis.Safe airway, adequate sedation, and rapid recovery were achieved with0.025mg/kg midazolam and1mg/kg bolus,25µg/kg/min intravenous propofol infusion for sedation under oxygen mask.The 30minute MRI examination was performed without problems.

Frontal bossing, happy puppet image, phenotypic feature of Angelman Syndrome



DISCUSSION - CONCLUSION: The MRI unit is an area of application for the anesthesiologist that has different characteristics resulting from the environment, the patient, and the procedure, and in which there is an increasing need.In patients with AS, the deletion site is associated with synthesis of GABA-A receptors.Therefore, the response to anesthetic drugs is unpredictable.Sudden cardiac arrest due to vagal hypertonicity, the possible risk of difficult intubation, and unstoppable vomiting are the main problems with the use of general anesthesia.Airway safety and rapid recovery can be achieved with propofol anesthesia, and it can be used safely in pediatric patients in the MRI unit by protecting spontaneous breathing with oxygen via a mask.The fact that it has few side effects and the onset and termination of its effects are short increases the frequency of its use.Propofol has been shown to have anticonvulsant effects and is beneficial in status epilepticus.Selection of anesthetic technique and agents during MRI and knowledge of patient and procedural characteristics are important for a successful procedure.

Keywords: Angelman Syndrome, Magnetic resonance imaging, Anesthesia

Pub No: O-074

Peri and postoperative management of an iatrogenic tracheobronchial rupture patient

Burcu Ulugölge[1], Hüseyin Özkarakaş[1], Zeki Tuncel Tekgül[1]

[1]SBÜ İzmir Bozyaka training and research Hospital

INTRODUCTION - PURPOSE: Post intubation tracheobronchial rupture (TBR) is a rare but feared complication.We aimed to present a patient with a severe iatrogenic TBR.

CASE: A 48-year-old female patient with a venticuloperitoneal shunt who was operated for an intracranial mass was brought to the emergency department due to poor general condition and was found that she had a cardiac arrest. CPR started and the patient was intubated with #7endotracheal tube. Spontaneous circulation returned after 5min. of CPR. Thorax CT revealed that the tube was in the right bronchus. The patient's tube was withdrawn, but due to the development of severe subcutaneous emphysema, thorax CT was performed again, and the thoracic surgeon was consulted. Thoracic surgery admitted the patient to emergency surgery with the diagnosis of TBR. When the patient was taken into operation, extensive subcutaneous emphysema and pneumomediastinum were present. To provide adequate ventilation, the endotracheal tube was advanced to the right bronchus and single right lung ventilation was provided. Right thoracotomy was performed to repair the rupture, and the cuff of the tube was observed in the mediastinum. After TBR was provided by the thoracic surgery team, the endotracheal tube was fixed to 18cm from the lip margin. During the follow-up of the patient, emphysema was completely regressed.

ciltaltı amfizem



tomografi



DISCUSSION - CONCLUSION: Tracheal injury during intubation is a very rare complication. It has been shown that women are more frequently exposed to TBR due to shorter trachea compared to men. Intubation under stress and emergency conditions is an important risk factor for damage (1).In tracheal injuries, early surgical repair is the best treatment option for lesions larger than 2 cm with severe subcutaneous emphysema and/or respiratory failure. In conclusion, choosing the appropriate tube, proper placement of the tube, and following the guidelines is important.

Keywords: tracheal rupture, emphysema, respiratory failure

Pub No: O-076

Intravesical BCG immunotherapy complicated by severe tuberculosis sepsis: A Case Report

Meltem Ceylan[1], Nilgün Kavrut Öztürk[1]

[1]SBU Antalya Training and Research Hospital, Departmant of Anesthesiology and Reanimation

INTRODUCTION - PURPOSE: Bacillus Calmette-Guérin(BCG) is applied prophylactically to treat bladder transitional epithelial cell carcinomas and reduce recurrence, interrelated to the application may occur many local and systemic complications. We aim to report a case who developed severe tuberculous sepsis after the sixth intravesical BCG immunotherapy.

CASE: A 56-year-old male patient with known bladder cancer comorbidity was admitted to the ICU with massive hematuria, fever, dyspnea, and weakness. The patient stated that his symptoms started after the sixth BCG immunotherapy in the urology service and worsened progressively. On admission ın the ICU, vital signs were as follows heart rate 133s/min, respiratory rate 32/min, and blood pressure 110/65mmHg. The physical examination findings were normal. Laboratory results are shown in Table1 and Chest CT imaging in Figure1. Urine and deep tracheal aspirate TBC-PCR tests were positive.The arterial blood gas analysis was measured at pH:7.36, PO2:55mmHg, PCO2:30mmHg, and SpO2:93%. The patient, whose breathing worsened despite high-flow oxygen nasal cannula(HFNC) support, was intubated electively and applied pressure-controlled ventilation with midazolam, fentanyl, and rocuronium infusion. Continue renal replacement, cytokine apheresis, and medical treatment (methylprednisolone at 250 mg daily for five days, anti-tuberculosis drugs, fresh-frozen plasma, and fibrinogen concentrate) were applied. On the 11th day after admission to ICU, the patient died due to severe tuberculosis sepsis complicated by MODS.

Figure 1 shows the patient had in both lungs, especially in the periphery minimal ground glass density, focal consolidations, and pleural effusion



Table 1

	Normal Range		Normal Range
Hemoglobin Level, *g/dL*	12.0 (13.5-18)	CRP level, *mg/L*	216.5 (0-5)
White Blood Cell,*103/mm3*	7.3 (4-10.5)	Procalcitonin, *ng/ml*	7 (0-2)
Neutrophil Count, *103/mm3*	6.64 (1.82-7.42)	LDH, *U/L*	611 (<248)
Lymphocyte Count, *103/mm3*	0.48 (0.85-3)	D-Dimer Level, *µg/L*	2375 (0-242)
Platelet Count, *103/mm3*	178 (150-450)	Amylase, *U/L*	203 (22-80)
Ammonia, *µg/dL*	184.6(27-90)	Lipase, *U/L*	578 (<67)
Aspartate Transaminase, *IU/L*	153 (10-50)	Fibrinogen, *mg/dL*	158 (200-400)
Alanine Transaminase, *IU/L*	158 (0-50)	Ferritin, *µg/L*	1176 (23-336,2)

Laboratory findings on admission to the Intensive Care Unit

DISCUSSION - CONCLUSION: BCG shows its effect by stimulating the immune system in the bladder. The stimulated immune system recognizes and destroys cancer cells. In Literature, while minor complications such as cystitis, dysuria, hematuria, and fever are frequent in BCG treatment, systemic complications(<5%) such as arthralgia, arthritis, granulomatous pneumonia/hepatitis, pancytopenia, or BCG sepsis(0.4%) are rarely observed.Systemic complications have thought to be caused by the hematogenous spread of bacteria after traumatic catheterization-associated transitional epithelial injury or immuno-allergic reactions.As knowledge about BCG immunotherapy enhances, its complications will be able to be diagnosed and treated earlier.

Keywords: Bcgimmunotherapy, severe tuberculous sepsis

Pub No: O-077

Investigation Of Hospitalization Infection Status In Hospitalized Patients In The Last 1 Month

Aylin PARMAKSIZ[1]

[1]BAKIRKÖY DR. SADİ KONUK EAH

INTRODUCTION - PURPOSE: Procalcitonin is a precursor peptide whose blood value is increased in bacterial infections.While the reference limit of PCT is below 0.5 µg/L in healthy individuals, it has been reported to increase up to 1000 µg/L in sepsis and severe infections.(1,2)In this study; Correlation between serum procalcitonin (PCT) levels at admission and cultures taken at hospitalization was investigated.

MATERIALS AND METHODS: This study in Murat Dilmener Emergency Hospital ICU September-2022 all patients older than 18 years of age who were followed up in the intensive care ICU whose culture and procalcitonin were checked at the time of hospitalization were included.

RESULTS: Of 48 patients, 16 were female and 32 were male.38 of them were admitted from the ward, 1 of them from the external intensive care unit, and 9 of them from the emergency. Admission diagnoses were acute respiratory failure in 24 patients, general condition disorder in 18 patients and altered consciousness in 6 patients. The average number of intensive examination hospitalization days of the patients was 12.1875. 14 of the patients continue to be hospitalized. 22 of them died and 12 of them were discharged to the service.There were 20 patients whose procalcitonin level was below 0.5 during hospitalization. Although procalcitonin was negative in 14 of these patients, growth was observed in the hospitalization cultures.In total, growth was observed in 27 patients in the hospitalization culture. 7 tracheal aspirate cultures, 9 urine cultures, 20 blood cultures, and 13 patients had growth in more than one site.

relationship between procalcitonin and reproductive site

	blood	tracheal aspirate	urinary
procalcitonin negatif	8	5	5
procalcitonin pozitif	12	2	4

DISCUSSION - CONCLUSION: A negative procalcitonin result does not rule out bacterial infection. Procalcitonin antibiotic therapy should not be considered as the only criterion for initiating intensive care admissions. Antibiotic treatment should be decided by considering other acute phase reactants, white blood cell values and imaging, and cultures should be sent from each patient at the time of hospitalization.

Keywords: procalcitonin, bacterial infection

Pub No: O-078

Follow-up and Discharge of a Pregnant Woman with Posterior Reversible Encephalopathy Syndrome (PRES) in the Intensive Care Unit

Kamuran ULUÇ[1]

[1]Intensive Care Clinic, University of Health Sciences Turkey, Prof.Dr. Cemil Taşçıoğlu City Hospital, Istanbul, Turkey

INTRODUCTION - PURPOSE: Posterior reversible encephalopathy syndrome(PRES) is a syndrome that is accompanied by headache, variable mental status, epilepsy, visual disturbances.The known causes of the syndrome include hypertensive encephalopathy, preeclampsia, eclampsia, HELPP syndrome, postpartum period following decapitation(1).In this case report, we tried to explain the diagnosis, treatment and approach in a case of PRES that was followed up in intensive care.

CASE: A 34-year-old patient was admitted to an emergency cesarean section operation with spinal anesthesia with a diagnosis of preeclampsia. The baby was delivered healthy. The patient with high intraoperative blood pressure was admitted to intensive care for close follow-up.The preoperative blood pressure in the intensive care unit continued to rise. Upon detection of blood pressure as 230/120 mmHg, nitroglycerin infusion of 0.2 µg/kg/min was started. The patient with hypertensive course developed sudden loss of consciousness and generalized tonic-clonic seizure after 14 hours. He was put on midazolam and intubated when his breathing became superficial. Intra Venous (IV) magnesium sulfate (MgSO4) treatment was continued for 24 hours in the preoperative period. Intravenous infusion of esmolol and IV levetiracetam (2000 mg loading and 2x500 mg maintenance) were performed. Cranial diffusion was evaluated as a compatible appearance with MRI PRESS(Figure 1).The patient, whose vitals were stable, was transferred to the service after 3 days.

Figure 1: Hyperintense signal changes in FLAIR and T2A sequence in brain MRI examination

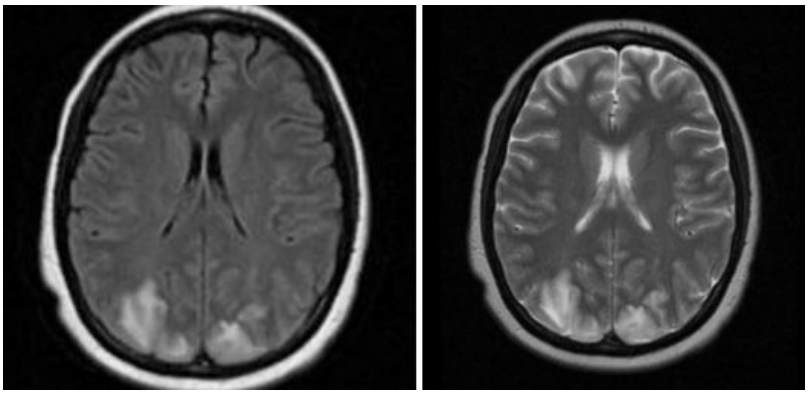

DISCUSSION - CONCLUSION: Preeclampsia is among the rare causes of PRES. Especially in pregnant women with hypertension and proteinuria, seizures should be considered. It mostly occurs in the second or third trimester of pregnancy,but it can also develop in the postpartum period in 5% of the cases(2).In cases where rapid diagnosis and treatment is made, patients recover completely within a few weeks. Otherwise, the clinical situation may progress to ischemia, massive infarction or even death. PRES is a radiological and clinically reversible diagnosis, and permanent damage can be prevented with early diagnosis and treatment(3).

Keywords: Posterior Reversible Encephalopathy Syndrome(PRES), Preeclampsia, Intensive care unit

Pub No: O-079

Dexmedetomidine Induced Polyuria in the Intensive Care Unit: a-case report

Nurcan KUTLUER KARACA[1]

[1]Erzincan Binali Yıldırım University Faculty of Medicine

INTRODUCTION - PURPOSE: Dexmedetomidine is a sedative with a highly selective alpha-2 receptor agonist, commonly used for sedation, anxiolysis, and analgesia. This report presents the case of polyuria in a critically ill patient who was sedated with dexmedetomidine, was intubated due to severe chronic obstructive pulmonary disease, and did not tolerate noninvasive mechanical ventilation.

CASE: A 59-year-old man (height:190 cm; weight:95 kg) with a history of chronic obstructive pulmonary disease, coronary artery disease, and atrial fibrillation was admitted to the medical ICU with acute-on-chronic hypercapnic respiratory failure secondary to exacerbation of chronic obstructive pulmonary disease requiring ventilatory support. The patient received a dexmedetomidine infusion at 0.2-0.5 mcg/kg/h after noninvasive mechanical ventilation due to increasing delirium. On the third day of hospitalization, the patient was intubated due to severe hypercarbia and decreased level of consciousness. Intravenous midazolam infusion was initiated, and dexmedetomidine was stopped. On the ninth day of hospitalization, dexmedetomidine infusion was started at 1 mcg/kg/h. He developed abrupt onset of polyuria with an increase in urine output from 80-100 mL/h to 300-500 mL/h, totaling approximately 4.2 L. The patient's serum Osm was within the normal limits (295 mOsm/kg). However, the urine Osm was 123 mOsm/kg on the first day of polyuria. Dexmedetomidine was discontinued, and the urine output eventually decreased slowly to 50-100 mL/h after 5-6 h. The subsequent laboratory analysis after discontinuation of dexmedetomidine demonstrated increased urine Osm to 354 mOsm/kg.

DISCUSSION - CONCLUSION: Polyuria is an uncommon but significant side effect of dexmedetomidine. As the use of dexmedetomidine continues to increase in ICUs, it should be a differential diagnosis in polyuria, and careful urine output monitoring is necessary. However, the exact mechanism remains unclear. Further clinical studies are needed on answering the question regarding the pathophysiology of dexmedetomidine-causing polyuria.

Keywords: Case report, Dexmedetomidine, Diabetes insipidus, Polyuria

Pub No: O-080

Our Experience In a Can't Intubate- Can't Oxygenate (CICO) Case

Fethi GÜLTOP[1], Esra AKDAŞ TEKIN[1]

[1]PROF.DR. CEMIL TAŞÇIOĞLU CITY HOSPITAL

INTRODUCTION - PURPOSE: We will share our experience in an unusual Can't Intubate-Can't Oxygenate (CICO) situationand emphasize the importance preparedness for such a situation and the importance of team collaboration.

CASE: 49-year-old male, previously diagnosed with a neck tumor and refused to be operated on. He presented to Emergency department with severe dyspnea and tachypnea. The patient was immediately taken to the operating room for emergency tracheostomy by the ENT team without the possibility of conducting any investigations.Patient's neck was stiff and significantly enlarged with palpation(Figure-1,2), and consequently, the CTM was not palpable. Patient was severely hypoxemic on arrival (SpO2=%75). RSI was initiated but it was not possible to oxygenate the patient by any means (two person mask or SAD). Intubation was attempted but epiglottis was not visible. As intubation failed a CICO situation was declared. Surgical tracheostomy by the surgeon was attempted in accordance with DAS-UK protocols(1). An incision was made at the midline, but tumor tissue was encountered and due to tissue stiffness, dissection was unsuccessful. Anesthesia team took-over and needle aspiration from the left side of the neck was attempted as a last rescue effort, while CPR was initiated as patient was arrested. When air was aspirated, deep dissection was performed by keeping the needle as guide. After the trachea was encountered, it was perforated with a scalpel and endotracheal tube was placed(Figure-2). Following successful intubation, ROSC was achieved, and the surgery was completed. Patient was taken to the ICU. Later, CT scans showed the trachea was shifted to the left(Figure-3).

Figure-1



Figure-2



Figure-3

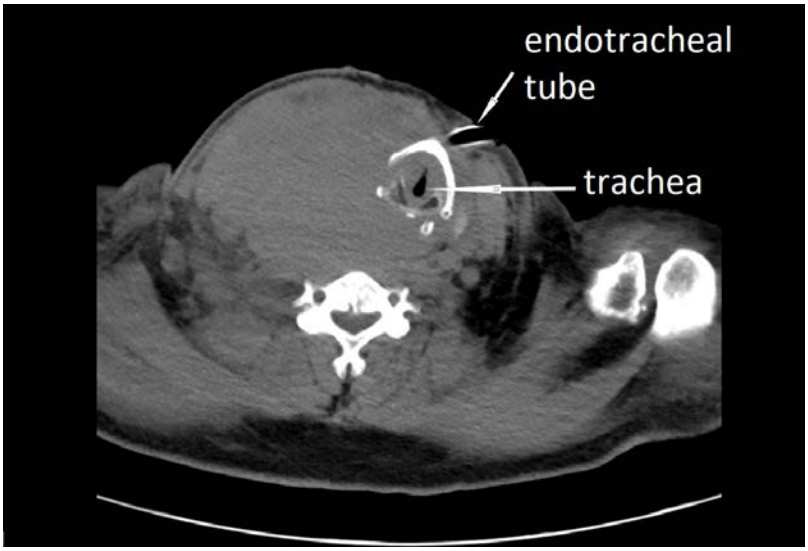

DISCUSSION - CONCLUSION: This emergency case shows the importance of readiness and multidisciplinary collaboration for difficult airway management. In our opinion, this might be achieved by multidisciplinary simulations, availability of training and equipment for more than one eFONA technique and prior allocation of roles for difficult airway scenarios.

Keywords: CICO, Equipment, Difficult Tracheostomy

Pub No: O-081

Flumazenil As An Antidote For Alprazolam Overdose: A Case Report

Esra ÇANKAYA[1]

[1]Trabzon Sürmene State Hospital

INTRODUCTION - PURPOSE: Alprazolam is a triazolobenzodiazepine used in patients with anxiety and panic disorders. In this case, we aimed to examine treatment management of alprazolam overdose.

CASE: A 21-year-old female patient diagnosed with anxiety and bipolar disorder was brought to emergency service by her family in 30 minutes because she took 15 mg of alprazolam and 12,5 mg of olanzapine. At hospital admission, she has glasgow coma scale (GCS):10, hypotension and bradycardia. After the administration of activated charcoal in emergency service, she was admitted to the ICU. 1 mg of flumazenil and fluid was given. After flumazenil administration, she has GCS:13. In the follow-up, 1 mg of flumazenil was given again to the patient who developed hypercarbia and non-invasive ventilation was applied. At the end of 48h, the patient was discharged with full recovery.

DISCUSSION - CONCLUSION: High doses of benzodiazepines are associated with increased morbidity and mortality. In several case reports; patients had impaired consciousness or cardiac arrest, had central nervous system (CNS) depression and respiratory acidosis, however vital signs were within normal range. The dose of alprazolam received by our patient was above the therapeutic dose. She had CNS depression, hypotension, bradycardia, and respiratory acidosis, but her ECG was normal. We applied flumazenil as an antidote to our patient and we observed a dramatic improvement in CNS findings and hemodynamic parameters, but due to short duration of action of flumazenil, we had to give it in intermittent doses. As a result; CNS symptoms and cardiac effects can be seen in alprazolam overdoses. The severity of this effect may vary depending on the dose taken, the time the drug is absorbed from the gastrointestinal tract, whether early intervention is made and the patient's sensitivity to the drug. Early intervention is very important to prevent serious side effects.

Keywords: Alprazolam, Flumazenil, ICU, Overdose

Pub No: O-082

Percutaneous Endoscopic Gastrostomy Experience in a Tertiary Intensive Care Unit

İsmail Çalıkoğlu[1], Yasin Nalbantlar[1], Erdal Karaköse[1], Uğur Topal[1], Sercan Yüksel[1], Erdal Ercan[1], Zafer Teke[1], Burcu İleri Fikri[2], Hasan Bektaş[1]

[1]Başakşehir Çam&Sakura City Hospital, Department of Surgery, İstanbul, Turkey
[2]Başakşehir Çam&Sakura City Hospital, Intensive Care Unit, İstanbul, Turkey

INTRODUCTION - PURPOSE: Percutaneous endoscopic gastrostomy (PEG) is one of the alternative methods used for nutrition in patients whose gastrointestinal system functions are maintained(1). In this study, it was aimed to present our (PEG) experience in the intensive care unit(ICU).

MATERIALS AND METHODS: Between August 2020 and October 2022, patients who underwent PEG in the adult ICU were retrospectively analyzed.

RESULTS: A total of 121 (F/M: 57/66) patients underwent PEG. The mean age of the patients was 63.6±3.1(18-92). Indications for ICU were cerebrovascular accident (CVA) in 30(24.8%), respiratory distress in 27(22.3%), poor general condition in 22(18.2%) and COVID-19 in 19(15.7%) patients. Of the patients, 58(47.9%) had hypertension, 56(46.2%) had CVA, 34(28.1%) had diabetes mellitus and 11(9.1%) had cancer history. PEG placement was performed on an average of 41.5±4.4 (5-133) days in the intensive care unit. On the day of PEG insertion, the median values of Glasgow and APACHE II scores were 7(3-15), and 10(0-48), respectively. There were no endoscopic pathological findings in 104 patients, but gastritis in 11 patients, and tracheo-esophageal fistula in 3 patients. 62(51.2%) of the patients died an average of 43.5% (0-238) days after PEG insertion. The number of patients who died in the first 30 days was 22, only one perforation detected. PEG replacement was performed in 7 patients due to leakage at the edge of the PEG, and melena was observed in 1 patient, which did not require additional intervention.

DISCUSSION - CONCLUSION: Enteral feeding should be started as early as possible in the ICU. For this purpose, bedside PEG is an important and useful tool with a low complication rate and easy accessibility(2).

Keywords: percutaneous endoscopic gastrostomy, PEG, Endoscopy, ICU patients, complication

Pub No: O-083

Anesthesia Management in the Patient with Andermann Syndrome

Ufuk KARBAŞ[1], Ahmet AKSU[1]

[1]Fırat University Faculty of Medicine, Department of Anesthesiology and Reanimation

INTRODUCTION - PURPOSE: Andermann Syndrome(AS) is an extremely rare, early-onset autosomal recessive disease associated with complete or partial agenesis of the corpus callosum. AS includes clinical features such as developmental delay,severe progressive sensori-motor neuropathy with areflexia, corpus callosum agenesis, amyotrophy, hypotonia, cognitive dysfunction, psychosis, and dysmorphic features(1).We aimed to share our anesthesia experience in the patient with AS.

CASE: Preanesthetic evaluation of a 13-year-old male patient with a weight of 40 kilograms, who was planned to have an inguinal hernia operation by the pediatric surgery clinic, was performed.In the anamnesis taken from his parents, it was learned that the patient was diagnosed with AS when he was 4 years old, at the hospital they applied to because of delayed walking(Picture1).Difficult airway finding wasn't detected in the patient.Severe scoliosis and prominent neuropathic changes in the body were detected in the mentally retarded patient(Picture2).The patient's American Society of Anesthesiologists(ASA) physical condition class ASA III was evaluated.The patient was placed on the operating table with a heating blanket(Picture3). In the induction phase, 3 mg/kg propofol and 1 mcg/kg fentanyl were administered intravenously.After the induction, the patient was placed with a 3 no laryngeal mask airway (LMA).In the maintenance of anesthesia, 3% sevoflurane in 50% O2/ 50% dry air mixture was used.Anesthesia machine was set to be etCO2 30-35mmHg.The patient was given 600 mg of paracetamol as an analgesic.After surgery, LMA was removed and the patient was taken to the recovery unit.

Picture-1

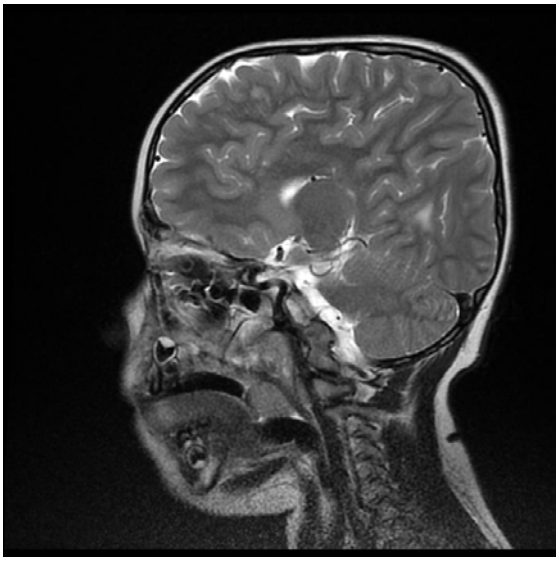

Brain MRI Image of the Patient

Picture-2



Picture-3



Front-side view of the patient on the operating table

DISCUSSION - CONCLUSION: AS is important because it contains risks that may cause anxiety in anesthesiologists such as airway difficulties, respiratory problems, gastric reflux and myopathy(2).Temperature monitoring, adequate ventilation, aspiration and prevention of seizures and pain management play a key role in the perioperative management of patients with AS(3).We didn't encounter any negative situation after we prepared the optimal conditions in the perioperative management of our patient.

Keywords: Corpus Callosum Agenesis, Mental Retardation, Difficult Airway, Andermann Syndrome

Pub No: O-084

Our Approach to Massive Thrombus in the Right Atrium: A Case Report

Asiye DEMİREL[1], Hamide Ayben KORKMAZ[1], Tuğba ONUR[1], Korgün ÖKMEN[1]

[1]University of Health Sciences, Bursa Yüksek İhtisas Training and Research Hospital

INTRODUCTION - PURPOSE: Presence of thrombus in the right atrium is a high risk for pulmonary embolism, early intervention is important. Thrombolytic therapy, catheter embolectomy or surgery are options (1). We aimed to present a case with tachicardia, dyspnea, hypotension and mobile, snake-like, massive thrombus on Transthoracic Echocardiography (TTE).

CASE: 36 years male patient; had a history of pulmonary embolism 7 times and deep vein thrombosis and venous insufficiency after vena cava filter 2 years ago. He has not taken rivaroxaban treatment for 2 days and was admitted to our hospital with thrombolytic therapy and echocardiography because of the image consistent with bilateral pulmonary embolism in the Computed Tomography. The patient was given 100mg tPA intravenously over 2 hours. When chest pain started, TTE was performed and a 1.5x5 cm mass image of a hyperechogenic, mobile, thrombus-compatible mass prolapsed into the right ventricle in diastole was observed in the right atrium. Right heart cavities were wide, left heart function and diameters were normal, pericardial effusion was observed adjacent to the left ventricular posterior wall. Transpulmonary Arterial Pressure was 38 mmHg. He was operated at the 16th hour of his hospitalization. A 7x2 cm organized thrombus was removed from the right atrium with right atriotomy accompanied by cardiopulmonary bypass (Figure 1). Pulmonary arteriotomy was not performed. With high-dose inotrope after surgery the patient was extubated at the 5th hour and transferred to the service in room air on the 3rd day.

Organized Thrombus



DISCUSSION - CONCLUSION: Intracavitary masses such as thrombus, vegetation, and tumor in the right heart cavities are very rare, and these cases are related to patients with pulmonary embolism (2). Thrombus in the right atrium are often, very mobile, serpenginous and filiform, has similar features in our case. Early surgical planning and correct anesthesia strategies can reduce mortality in patients with massive pulmonary embolism and thrombus.

Keywords: Pulmonary Embolism, Transthoracic Echocardiography, Surgery, Right Atrium, Thrombus

Pub No: O-085

Hemothorax During Central Vein Catheter Placement

Hilal Yavuzel[1], Yakup Savan[2], Tülin Satılmış[1], Osman Ekinci[2]

[1]İstanbul Dr. Siyami Ersek Göğüs Kalp ve Damar Cerrahisi Eğitim Ve Araştırma Hastanesi, Anesthesiology and Reanimation
[2]İstanbul Haydarpaşa Numune Eğitim ve Araştırma Hastanesi, Anesthesiology and Reanimation

INTRODUCTION - PURPOSE: Central venous catheters (CVC) are frequently used for many functions, including administering intravenous medications, blood products and parenteral nutrition. We present a case of hemothorax that developed during jugular venous catheterization. The purpose of this case was to present one of the most serious complication of CVC.

CASE: A 49-year-old woman with operated breast cancer underwent video-assisted thoracic surgery (VATS) for pleural biopsy in the right lateral decubitis position. Preoperative her vital signs were normal. After anestesia induction and intubation, 7,5 F catheter was placed into the left jugular vein. Serohemorrhagic fluid was observed by aspiration of the end of the catheter. It was concluded that extravascular placement of the catheter. The catheter was removed after informing the surgical team. Then left femoral vein was preferred for CVC. During that period, when the patient's blood pressure decreased and blood test showed hemoglobin level decreased, noradrenaline infusion and erytrocyte suspension replacement were started. After then, in the right lateral decubitus position, coagulum and serohemorrhagic fluid were seen in the thorax by surgeons during VATS and the incision was widened and open surgery was performed. It was observed that the bleeding originated from the subclavian artery. Necessary intervention performed and the surgery was completed.

Coagulum and Serohemorrhagic Fluid

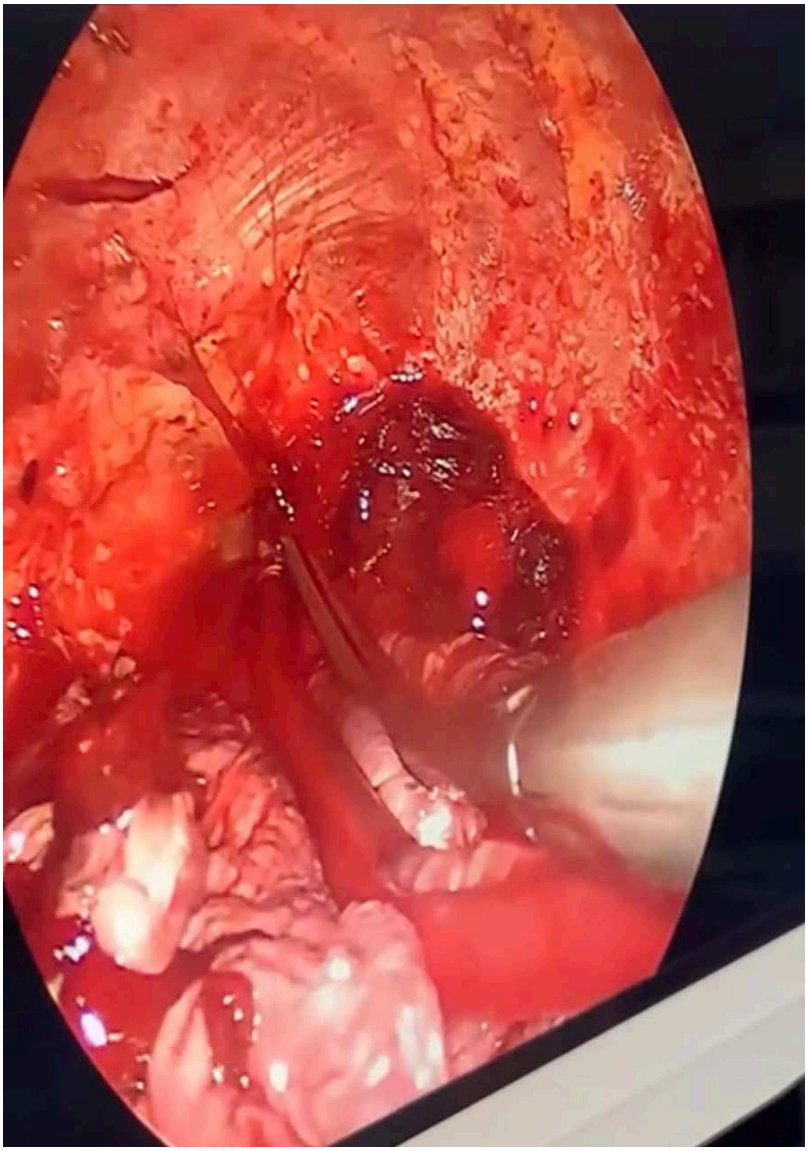

DISCUSSION - CONCLUSION: The most common complications of the insertion of the catheter are arterial puncture, pneumothorax, arrhythmia, air embolism and vascular injury. In this present case, we considered that accidental perforation of artery developed by dilator or guide wire. Accidental perforation of blood vessels often results in catastrophe. In this our case, thoracoscopic surgery allowed rapid diagnosis and intervention. The experience of the practitioner and the use of the radiological methods are important in preventing these complications.

Keywords: Hemothorax, Central venous catheterization, Subclavian artery, Complication, Video-assisted thoracoscopic surgery

Pub No: O-086

Brainstem Anesthesia due to retrobulbar block injection:A case report

Bilge Olgun Keleş[1], Hakan Koç[2]

[1]Giresun University Medicine Faculty,Anesthesia and Reanimation
[2]Giresun University Medicine Faculty,Ophthalmology

INTRODUCTION - PURPOSE: Retrobulbar block (RBB) is an anesthetic technique used for ocular anesthesia and akinesia before ophthalmic surgery. A rare and dangerous complication of this block; brainstem anesthesia (BSA) is caused by the direct penetration of the injected anesthetic agent into the subarachnoid space or spreading to the central nervous system(1).

CASE: A 72-year-old-female patient was given a retrobulbar block with 3 mL lidocaine HCL, to the right eye for cataract surgery. Immediately after the injection, the patient developed confusion, low blood pressure, difficulty breathing and unconsciousness. Her breathing was supported by a mask.Later,nystagmus,twitching,tremors in the arms, convulsant behaviors, and hypertension were observed. We thought that was BSA. There wasn't any improvement after 15 minutes then (ILE) intravenous lipid emulsion treatment was decided.20% lipid solution was given as 1 mg/kg bolus for 5 minutes and then infusion was started at 15 ml/kg/hour. After the bolus, all symptoms began to improve gradually. At the end of infusion, nearly 45 minutes, she was totally normal. The operation was delayed she was sent to her service.

DISCUSSION - CONCLUSION: Local anesthetic Systemic Toxicity (LAST) may also develop after RBB and can be confused with BSA. In the literature, symptoms in BSA cases have began within 2-10 minutes, and the clinic of them resolves within 15-60 minutes with symptomatic treatment(2,3).In LAST, patients underwent ILE for cardiotoxicity and it was observed that their neurological symptoms improved rapidly (3,4,5,6,7).Since we couldn’t see any improvement after 15-20 minutes in our patient, we decided to give ILE and got an immediate response.It isn’t easy to distinguish whether the situation is LAST or BSA after RBB, and we think that giving ILE is an appropriate treatment method for both. The important issue is that the surgeon should be alert to the complications of local anesthesia and quickly apply the necessary treatment together with the anesthesiologist.

Keywords: retrobulbar block, brainsteam anesthesia, Local Anesthesia Systemic Toxicity, Intravenous Lipid Emulsion

Pub No: O-087

Tension Pneumocephalus Following Lumbar Spine Surgery

ONUR OKUR[1]

[1]Prof.Dr. Cemil Taşcıoğlu Şehir Hastanesi

INTRODUCTION - PURPOSE: Tension pneumocephalus is a extremely serious and rare complication of posterior spine surgery. Here, we report a case of symptomatic tension pneumocephalus in following posterior decompression surgery, and its management in the ICU.

CASE: Sixty-year old female patient with no known history of comorbidities and a history of previous spinal stenosis surgery was scheduled for L5-S1 posterior decompression. The patient was applied invasive and non invasive monitors, in order to, closely monitor hemodynamic status. The operation started following the induction of general anesthesia and lasted for 7 hours. Patient lost an estimated 2000mls of blood volume(hemoglobin 89g/dl). Towards the end of the surgery a mild metabolic acidosis(pH:7.28) with an increase in lactate levels(5.8mmol/L) was noted which was attributed to blood loss. No further problems were encountered. Patient was successfully extubated after the surgery. She was moved to the HDU, awake and concious, for close monitoring and due to the increased amount of blood loss. Patient deteriorated in hours, her GCS levels progressively fell(12), lactate levels(11.43mmol/L) further increased while HCO3 levels(4mmol/L) and pH(7.0) plummeted. Patient started having generalized tonic clonic seizures approximately four hours after surgery. Seizures were treated with 3mgs of midazolam, patient was intubated and brain CT images(Figure-1,2 and 3) were obtained which showed diffuse air images in both frontotemporal areas, falx cerebri, extraaxial CSF areas and cortical sulci. Patient's negative suction drains were removed after which point she started to recover. In the following 24 hours she was extubated and transferred to wards 3 days later without any neurological sequela.

Figure-1



Diffuse Pneumocephalus in coronal section CT images

DISCUSSION - CONCLUSION: Our case emphasizes the importance of having a high level of suspicion in similar cases where polyaxial screws are used, as the surgical team may not always notice dural puncture. Early recognition is crucial and negative pressure drains should be removed as soon as a diagnosis is made.

Keywords: Pneumocephalus, spinal stenosis, decompression, lactate

Pub No: O-088

Difficult Airway Management in a Patient with Rubinstein-Taybi Syndrome

Buket Aslan[1], Yelda Balık[1], Sefa Gökden[1], Osman Ekinci[1]

[1]İstanbul Haydarpaşa Numune Eğitim ve Araştırma Hastanesi

INTRODUCTION - PURPOSE: Rubinstein-Taybi syndrome (RTS) is a disorder with characteristic craniofacial, ocular and cardiac anomalies, wide fingers and toes. The most important challenge for anesthesia applications in RTS is difficult intubation, which is observed depending on craniofacial defects. We present a case about difficult airway management in a patient whose RTS diagnosis has not been confirmed yet.

CASE: A 7-month-old, 5800gr, 65cm girl was taken to the operating room for eye examination. She has a history of premature birth, polyhydramnios, feeding with a nasogastric tube, also has frequent hospitalizations due to episodes of hypoglycemia and aspiration pneumonia. She received general anesthesia for congenital glaucoma operation at the age of 4 months and there were no complications. Physical examination revealed micrognathia, hypertrophy of both thumbs, bilateral exophthalmos, and hypotonia. Mallampati could not be evaluated, neck movements were found to be normal. Preoperative vitals are within normal limits. For sedation, 10 mcg fentanyl and 50 mg pentothal were administered intravenously, then ventilation was commenced with a mask. Airway spasm developed after 10 minutes. 5 mg methylprednisolone and 3 mg rocuronium were administered intravenously. Direct laryngoscopy with Macintosh blade revealed Cormack-Lehane grade IV, therefore she couldn't intubate. Airway security was ensured with the number 1.5 i-gel supraglottic airway, then she was taken to an intensive care unit(ICU). As the arterial blood gas revealed pco2:90mmHg, a different practitioner placed a 3,5 number cuffed endotracheal tube with a Miller blade and stylet. After intubation, the pCO2 decreased to 50mmHg. She was referred to an advanced pediatric ICU for further examination and treatment.

DISCUSSION - CONCLUSION: Difficult airway becomes a major problem in terms of anesthesia management in patients with RTS due to their abnormal anatomical structures. Therefore, detailed evaluation before anesthesia, postoperative intensive care place arrangement, preparation for difficult airway are required in syndromic patients such as RTS.

Keywords: Airway management, Rubinstein–Taybi syndrome, Difficult airway, Pediatric anesthesia

Pub No: O-089

The Effects Of Peroperative Magnesium Sulfate Infusion On Intraoperative Anaesthetic Requirements And Postoperative Pain In Lumbar Surgery

Aysel SALKAYA[1], Sibel OBA[1], Leyla KILINC[1], Hacer Sebnem TÜRK[1]

[1]SISLI HAMIDIYE ETFAL EAH

INTRODUCTION - PURPOSE: The aim of this randomised controlled double-blind study, is to examine the results of peroperative low-dose magnesium sulfate (MgSO4) use on intraoperative anesthetic requirements and postoperative pain in lumbar surgery cases.

MATERIALS AND METHODS: Seventy adult patients in the ASA1-2 group who will undergo spinal surgery were included in the study. The patients were randomly divided into 2 groups. After intubation, an infusion of MgSO4 (10 mg/kg/h) in 100 ml of isotonic saline was started in the Mg group and an infusion of 100 ml of isotonic saline (10mg/kg/h) was started in the control group. Hemodynamic variables, amount of remifentanil consumed during the operation, extubation time were recorded. In the post-anesthesia care room, at the baseline, 5,10,15 and 30 minutes, agitation-sedation and pain were evaluated with Richmond Agitation-Sedation Scale (RASS) and the Visual Analogue Scale (VAS).After the patient was transferred to the postoperative room, patient-controlled analgesia PCA was prepared for postoperative pain management. Intensity of pain was evaluated with VAS at 2, 4, 6 and 24 hours postoperatively. Total opioid consumption in the first 4 and 24 hours, additional analgesic need, postoperative nausea and vomiting (PONV), tremor, hypotension, bradycardia were recorded.

RESULTS: There was a statistically significant difference in the post-anesthesia care room (PACU) RASS ratios at the baseline (T0) of the groups ($p=0.001$). Post-Op VAS Score was found to be statistically significantly lower in Group M in 6 and 24 hours (T3 and T4) ($p=0.015$ $p=0.009$). The need for post-op additional analgesics in Group M was statistically significantly lower than in Group C ($p<0.001$). The postoperative Mg level of Group M was statistically significantly higher than Group C ($p<0.001$)

DISCUSSION - CONCLUSION: The current study indicates that during lumbar surgery, preoperative 10mg/kg/h MgSO4 infusion, could reduce early post-op agitation and analgesic requirements up to 24 hours postoperatively

Keywords: Magnesium sulfate, pain, Visual Analogue Score, lumbar surgery

Pub No: O-090

Development of Spontaneous Pneumothorax, Pneumomediastinum and Subcutaneous Emphysema in COVID-19 Patients Followed in the ICU: A Retrospective Study

Gülçin PATMANO[1]

[1]Kayseri City Hospital

INTRODUCTION - PURPOSE: Widespread alveolar damage and pulmonary fibrosis are reported in Covid ARDS. Recent studies indicate that barotrauma-related events are at a higher rate in Covid-19 ARDS than in ARDS secondary to other etiologies. The occurrence of pneumomediastinum/subcutaneous emphysema is also rare in non-CoV-ARDS, but it is reported to be more common in Covid ARDS. Our aim is to highlight the cases of spontaneous pneumothorax (SPX), pneumomediastinum (SPM) and subcutaneous emphysema (SE) in COVID-19 patients followed in intensive care unit (ICU) and to investigate possible predisposing risk factors.

MATERIALS AND METHODS: Covid-19 patients hospitalized in Kayseri City Hospital and followed in ICU between January 2021 and November 2022 were analysed retrospectively.Among the patients who developed SPX and SPM, patients with laboratory-confirmed COVID-19 were included in the study. Demographic, clinical, laboratory and imaging data of patients with SPX, SPM, SE were collected. Iatrogenic cases were excluded from the study.

RESULTS: SPX, SPM, SE were detected in 102 (3.04%) of 3352 patients admitted to the COVID ICU. Demographic data of these patients are shown in Table 1. ICU mortality was 47.5% in 3352 patients with COVID ICU, and 97.05% in SPX, SPM, SE patients. The clinical evaluation of the patients is shown in Table 2. Tube thoracostomy was applied to all of the patients, and there were no patients who underwent surgical intervention.

Table 1. Demographic data of patients

Variables	n=102 (%)
Age	68,3±15,3
Sex (female)	42 (%41,1)
APACHE II	15,7±8,3
pregnancy	2 (%1,9)
Comorbidities	
Hypertension	32 (%31,3)
Diabetes mellitus	45 (%44,1)
COPD	18 (%17,6)
Malignity	3 (%2,94)
Chronic renal failure	3 (%2,94)
Others (muscle diseases, alzheimer's, parkinson)	5 (%4,90)
Disease chart	
SPX	73 (%71,5)
SPM	4 (%3,9)
SPX+SE	23 (%22,5)
SPM+SE	2 (%1,9)

COPD: Chronic Obstructive Pulmonary Disease, SPX: Spontaneus Pneumotorax, SPM: Spontaneous Pneumomediastinum, SE:Subcutaneus Emphysema

Table 2. Clinical features of patients

Variables	n=102 (%)
CT assessment	
Typical	82 (%80,3)
Atypical	19 (%18,6)
Uncertain	1 (%0,9)
ARDS Grade	
Mild (P/F 200-300)	0
Moderate (P/F 100-200)	62 (%60,7)
Severe (P/F <100)	40 (%39
ICU hospitalization day	23,2±20,5
In-hospital mortality	3 (%97,05)
Mortality after thoracostomy (days)	8,5±6,3

DISCUSSION - CONCLUSION: COVID-19 patients have increased lung parenchymal fragility and respiratory effort secondary to the inflammatory response. This is an important predisposing factor for barotrauma. It is very important for clinicians to know barotrauma risk factors well and to apply lung protective ventilation parameters to patients in managing this clinical condition.Further studies are needed to increase clinician awareness and determine predictive risk factors for SPX and SPM.

Keywords: Covid - 19, ARDS, pneumomediastinum, subcutaneous emphysema, pneumotorax

Pub No: O-091

Anaesthetic Management of Myasthenia Gravis in Aortic Valve Replacement

Yunus Emre KARTAL[1], Azime BULUT[1]

[1]Giresun University

INTRODUCTION - PURPOSE: Myasthenia Graves (MG) is an autoimmune disease resulting in muscle weakness;usually autoantibodies against acetylcholine receptors (1). Most important clinical findings are muscle weakness, ptosis and dysphagia (2). In this report, we aimed to present the anesthetic management of a patient with MG who underwent to aortic valve replacement

CASE: A 57-year-old woman with no history of operation was diagnosed with MG after ptosis in the right eye 4 years ago. She was prescribed pyridostigmine 180 mg per day,dexametasone 20 mg per day and azothioprine. Aortic valve stenosis (0,8cm2) was diagnosed in her echocardiography after a serious dyspnea attack. Valve surgery was planned for the patient. The patient received her routine medications on the morning of surgery. She did not have any complaint of muscle weakness, ptosis or dysphagia. In the operating room,after standard intraoperative monitoring, radial artery was inserted. General anesthesia was induced with midazolam (0,1mcg/kg), fentanyl (4mcg/kg), propofol (1mg/kg) and rocuronium (0,6mg/kg). A catheter was inserted in the right internal jugular vein. Anesthesia was maintained with sevoflurane and remifentanyl infusion. Lungs were ventilated with an air-oxygen mixture. Cardiopulmonary by-pass perfusion lasted for 108 minutes and during this period 0,05mg/kg midazolam and 0,3mg/kg rocuronium were administered three times intermittently and remifentanyl infusion was continued. Weaning from CPB was carried out unevenfully and the patient was transferred to the intensive care unit. We couldn't use any neuromuscular monitorization. After 4 hours, the patient weaned from the ventilator uneventfully. She was transferred to the ward on the second day of ICU admission and discharged on the 7th day of hospitalization.

DISCUSSION - CONCLUSION: Respiratory failure is the most common complication in MG patients. It could be controlled with titrating muscle relaxants. We think that preoperative control of MG is more important than choice of muscle relaxants.

Keywords: myasthenia gravis, aortic valve replacement

Pub No: O-092

Comparison Of The Effects Of Erector Spinae Plane Block and Caudal Block On Postoperative Analgesia And Stress Response In Pediatric Patients Undergoing Inguinal Hernia Surgery

Özge UYANIKOĞLU[1], Ayşe Surhan ÇINAR[1], Mustafa ALTINAY[1], Sibel OBA[1]

[1]Şişli Hamidiye Etfal Eğitim ve Araştırma Hastanesi

INTRODUCTION - PURPOSE: We aimed to compare the effects of erector spinae plane block (ESPB) and caudal block on postoperative analgesia and stress response in pediatric patients undergoing inguinal hernia surgery.

MATERIALS AND METHODS: After ethics committee approval, 62 patients aged between 1-6 years, with ASA score I-II, who were going to undergo inguinal hernia surgery, were included in the prospective, randomized and single-blind study. Following general anesthesia under monitoring, USG-guided blocks (ESPB and caudal) were applied to the patients with 0.5 mL kg-1 0.25% bupivacaine. The heart rate(HR), mean arterial pressure (MAP) and SPO2 values of patients were recorded before anesthesia induction, pre-block, 10 minutes after the block and within 15-minute intervals during the operation. The prolactin and cortisol levels of the patients were sent preoperatively and at the postoperative 40th minute. Analgesia time, the total amount of analgesics in 24 hours, number of times analgesics given and complications were recorded. HR, MAP and FLACC scores were recorded at postoperative 30 minutes, 1st, 2nd, 3rd, 4th, 8th, 12th and 24th hours. When the FLACC value is 4 and above, 15 mg kg-1 intravenous paracetamol in the first 4 hours postoperatively; 10 mg kg-1 oral suspension paracetamol was given to those who were discharged home.

RESULTS: There was no statistically significant difference between the two groups in terms of demographic data; duration of operation, anesthesia, analgesia; total amount of analgesics, number of times analgesics given, SPO2 and complications. In Group E, postoperative prolactin values were statistically significantly higher than preoperative values. In the comparison between groups, the increase in postoperative prolactin levels was higher in Group E than in Group C. In both groups, postoperative cortisol values were found to be significantly higher than preoperative values.

DISCUSSION - CONCLUSION: ESPB applied in pediatric patients who underwent inguinal hernia surgery was similar to caudal block on postoperative analgesia and stress response.

Keywords: Pediatric regional anesthesia, Erector spina plane block, Caudal block, Surgical stress hormone

Pub No: O-093

A Case Of Dental Prosthesis Aspiration As A Complication Of Endotracheal Intubation

Selvinaz YÜKSEL TANRIVERDİ[1], Aylin ÖZAYDIN[1], İlknur Hatice AKBUDAK[1], Aslı METE YILDIZ[1], Hülya SUNGURTEKİN[1]

[1]Pamukkale University, Department of Anesthesia and Reanimation

INTRODUCTION - PURPOSE: Dental injury during laryngoscopy is one of the most common complaints against anesthesiologists and the risk of dental injury during intubation is high (1).This type of injury usually occurs when the maxillary incisors are used as abutments during direct laryngoscopy.Anesthesia-induced dental trauma studies have a range between 0.02% to 0.7% (2,3) but may have an incidence of %12,1 when patients have loose teeth (4).

CASE: A 53 years old woman with hypertension and hypothyroidism, evaluated as ASA-2, MP-3, was taken to the operating room for modified radical mastectomy. After intubation, the anterior upper dental prosthesis was found to be in the oropharynx, but it could not be removed. Appropriate ventilation of the patient was continued. Considering tracheal aspiration, bronchoscopy was performed on the patient and the dental prosthesis was seen between the membranous trachea and the intubation tube and dropped again while trying to remove it with bronchoscopy. Laryngoscopy was performed for the possibility of remaining in the upper airway and it was seen in the nasopharynx. The dental prosthesis was successfully removed from the mouth by an otolaryngologist.

Dental prosthesis



The image of the denture in the nasopharynx

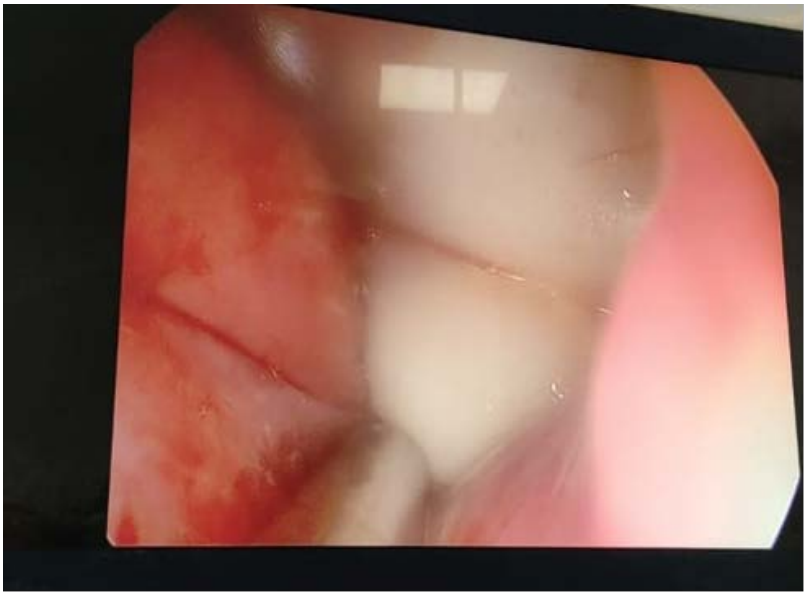

DISCUSSION - CONCLUSION: The main risk factors for tooth damage during anesthesia related endotracheal intubation are; dental pathology or the presence of dental prostheses, abnormal jaw structure and tooth alignment (1). Anesthesiologists who encountered preanesthetic tooth trauma reported incidents where the tooth and bridge parts were displaced and fell into the oral cavity. In this emergency, laryngoscopy, bronchoscopy, and esophagoscopy are usually required to prevent accidental tracheal aspiration and lung infection (4,5).Detection of loose teeth, crowns or dental caries with appropriate preoperative oral examination in elective surgeries may prevent perioperative dental complications. Preoperative evaluation of the patient by the dentist, when deemed necessary, may reduce the risk of complications.

Keywords: Dental prosthesis, aspiration, intubation complication

Pub No: O-094

Traumatic Massive Bleeding: A Double-Edged Knife

İpek Yakın Düzyol[1], Zeynep Aslan Yağlı[2], Çağrı Düzyol[2]

[1]Health Sciences University Kocaeli Derince Training and Research Hospital Anesthesiology and Reanimation
[2]Health Sciences University Kocaeli Derince Training and Research Hospital Cardiovascular Surgery

INTRODUCTION - PURPOSE: Introduction Correction of hemostasis parameters and replacement of blood loss are extremely important in hemorrhagic shock, besides surgical repair. Fibrinogen is the first and essential endogenous component of hemostasis to reach critically low levels during bleeding; therefore, human recombinant fibrinogen has been used. (1,2)Purpose This presentation aimed to draw attention to possible complications following blood transfusion and use of medical agents for massive bleeding.

CASE: A 44 years-old male was admitted with hemorrhagic shock after a gunshot injury on the left groin. He had sinusal tachycardia (165 bpm), hypotension (60/30 mmHg despite inotropic support) and his arterial blood gas analysis showed acidosis with pH: 6.95, base deficit -16 mmol/l, lactate 14 mmol/l, and hemoglobin level ≤ 5 g /dl, preoperatively. Femoral artery and vein repairs were performed by Cardiovascular Surgery with ASA-VE risk. Intraoperative massive bleeding was managed with administration of erythrocyte suspension (10 units), fresh frozen plasma (10units), tranexamic acid (20 mg/kg), and human fibrinogen concentrate (Haemocomplettan P/Riastap, CSL Behring, Marburg, Germany-1000 mg). Following control of bleeding, the patient was taken to intensive care unit with arterial pressure of 90/45 mmHg under high dose inotropic support. Due to acute ischemia occurred on ipsilateral extremity on the 4th postoperative hour, he was reoperated for successful femoral artery thrombectomy.

DISCUSSION - CONCLUSION: Discussion The absence of thrombosis following successful thrombectomy reoperation suggests that arterial thrombosis might have developed due to medical agents such as tranexamic acid and fibrinogen, rather than mechanical-vascular causes. Although it is recommended as a prospectus information to use these agents with caution against thrombosis risk, we did not come across such a study in our literature review.Conclusion Besides rapid control of bleeding, we believe that close follow-up for the risk of thrombosis is vitally important in patients with traumatic massive bleeding.

Keywords: Massive transfusion, Thrombosis, Concentrated Human Fibrinogen

Pub No: O-095

Intercontinental Journey Of An Individual Without Ileus: A Case Report Of Cocaine Intoxication Caused By Rectal Ingestion

Damla ÖZMEN DÖNMEZLER[1], Dicle BIRTANE[2]

[1]Dr Abdulkadir Yüksel Devlet Hastanesi
[2]Ağrı Dr. Yaşar Er Yılmaz Doğubeyazıt İlçe Devlet Hastanesi

INTRODUCTION - PURPOSE: Cocaine is a local anaesthetic agent with high addictive potential,which can cause stimulation of the sympathetic nervous system by inhibiting catecholamine re-uptake at the sympathetic junction.Cocaine can cause conditions such as myocardial infarction,hypertension, arrhythmias, pulmonary oedema due to sudden increase in pulmonary pressure,pneumothorax due to the induction of vasospasm and thrombosis.In our case report,we aimed to present a patient with suspected chronic use and long-term acute intoxication due to ileus.

CASE: A 66-year-old,55 kg,male,foreign national patient with no known comorbidities was brought to the emergency room by 112 from the airport due to widespread abdominal pain.Air-fluid level was not observed in the abdominal tomography,but multiple regularly circumscribed objects were observed in the small intestine and the patient was immediately taken to the operation decision.In the evaluation of the patient in the operating room, his general condition was poor, his consciousness was lethargic, non-oriented, non-cooperative,GCS =7,deep hypotensive and tachycardia,SpO2 = 85, and 38°C.The patient was administered to IV hydration with 5 mg of ephedrine and rapid serial orotracheal intubation was performed.Midazolam 0.02 mg/kg IV and ketamine 1 mg/kg IV were administered during induction.Dexmedetomidine infusion was started for maintenance.Two litres of cold and isolayte IV hydration was administered. At the end of the operation the patient was taken to the postoperative intensive care unit. He was extubated on the 1st day of the postoperative follow-up

Blood analysis

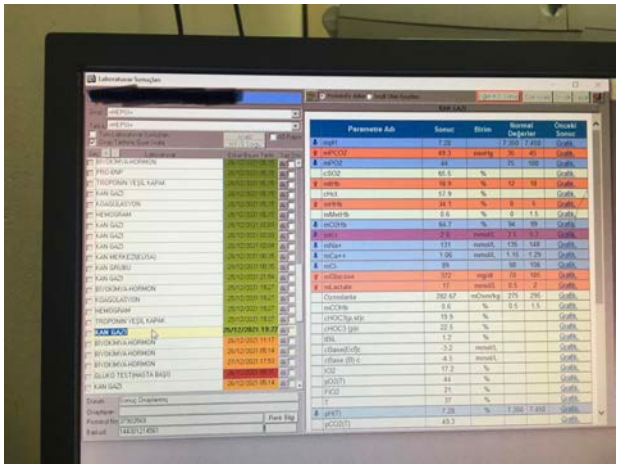

Abdominal BT

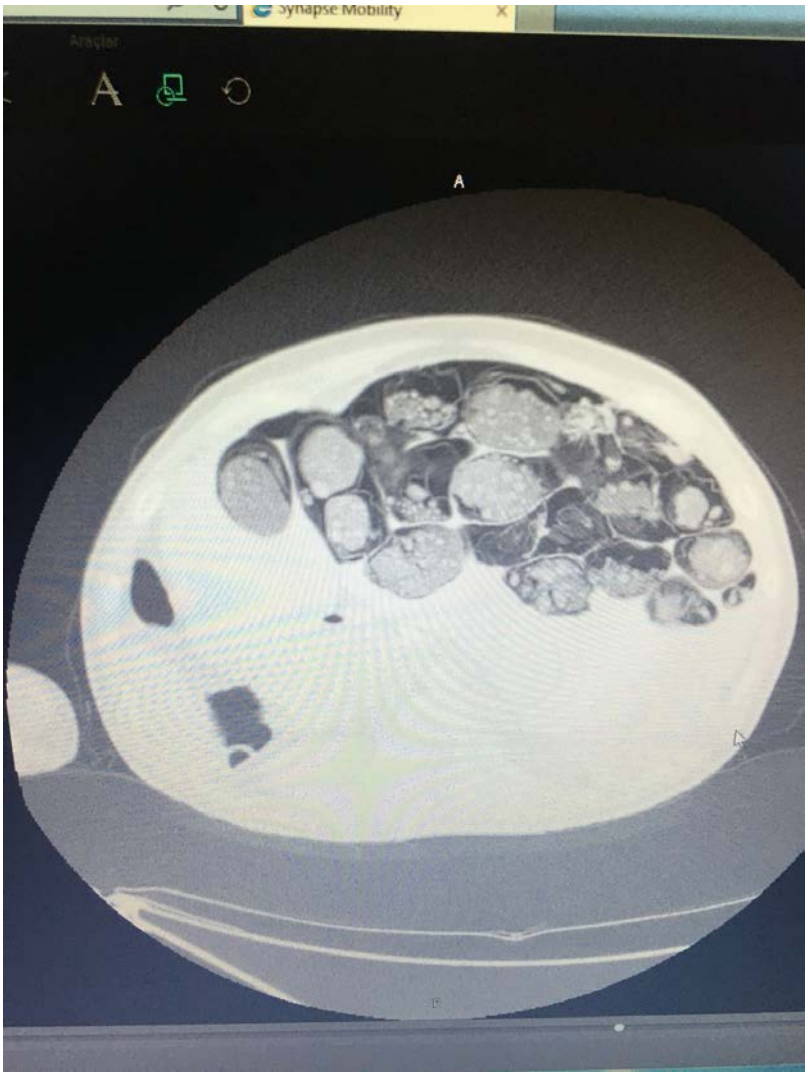

Cocaine pocket

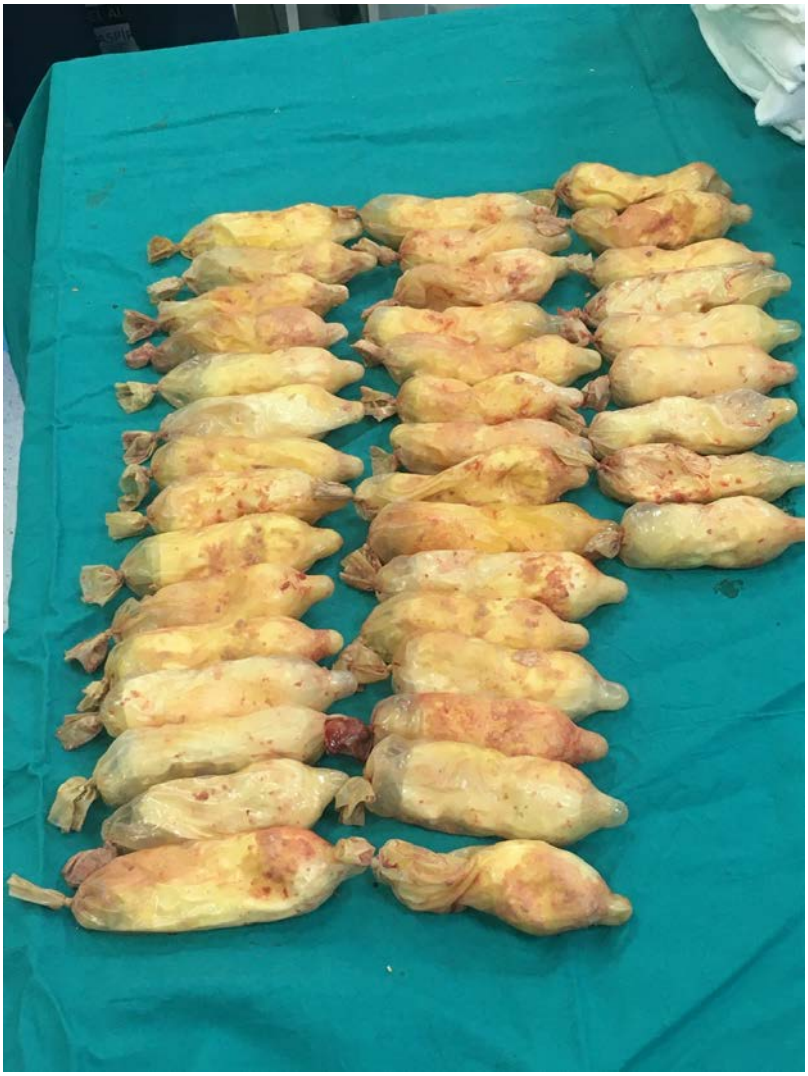

DISCUSSION - CONCLUSION: Benzodiazepine was used in the induction of anaesthesia because it suppresses the activation of the sympathetic system and reduces the cardiovascular effects of cocaine.In severe cocaine intoxications,hypotension may also be seen due to sodium channel blockade.In order to reduce the risk of rhabdomyolysis,cold balanced intravenous fluid was given rapidly to the hyperthermic patient with hypotension and whose lactate was 17 mmol/L.Since cocaine intoxication cases are cardiovascular and metabolically unstable,medication selection and fluid management should be done very carefully.

Keywords: Cocaine, İntoxication, Nonopioid anesthesia, İleus

Pub No: O-096

Awake Craniotomy In A Trauma Patient

Ahmet Tuğrul ŞAHIN[1], Olcayto UYSAL[1], Yasin TAŞKIN[2]

[1]Department of Anesthesiology and Reanimation, Tokat State Hospital
[2]Department of Neurosurgery, Tokat State Hospital

INTRODUCTION - PURPOSE: Awake craniotomy is first described in epilepsy surgery and since then this technique is used for operations as tumor excision, brain biopsy, ventriculostomy, deep brain stimulation (1). One of the main advantage of this technique is to prevent the risks and complications of general anesthesia (GA) (2). Here we aimed to present a patient undergone depressed skull fracture operation via scalp block.

CASE: A 82 years old male patient who had a blunt travma, applied to emergency department with a headache complaint. Computerized tomography (CT) was requested and depressed skull fracture was observed in the right parietal bone. Emergency operation was planned. In preoperative assessment, it was noticed that patient has stage 3 chronic obstructive pulmonary disease (COPD) and using an oxygen concentrator at home. Considering the underlying pulmonary disease may cause the need for mechanical ventilation support and prolonged stay in intensive care unit (ICU) in the postoperative period, awake craniotomy technique was decided for anesthesia management. Unilateral scalp block was performed by injecting 25 cc of %0.25 bupivacaine. Light sedation was carried out via remifentanyl infusion during the operation. The procedure took 50 minutes and no intraoperative complication was observed. The patient was sent to ICU in the postoperative period for 12 hours and thereafter discharged to the surgical ward. After 48 hours follow-up in surgical ward without a complication, patient was discharged with recommendations.

DISCUSSION - CONCLUSION: In conclusion we think that the awake craniotomy technique can be used safely in high-risk patients, as it makes positive impact to patient management by reducing the complications that may develop in the intra and postoperative period, as well as reducing the length of hospital stay and ensuring cost-effective management.

Keywords: Depressed skull fracture, Awake craniotomy, Head injury

Pub No: O-097

Apnea Testing In A Patient Who Underwent ECMO After Congenital Heart Surgery: A Case Report

Nurgul YURTSEVEN[1], Yener AKSOY[1]

[1]DR. SİYAMİ ERSEK THORACİC AND CARDİOVASCULAR SURGERY EDUCATION RESEARCH HOSPITAL.

INTRODUCTION - PURPOSE: Extracorporeal membrane oxygenation (ECMO) is used for patients who have respiratory or cardiac failure and are unable to sustain their life with conventional methods. (1)ECMO has its own risks including neurologic injury leading to brain death(BD). Determination of BD needs apne testing(AT) but it is difficult to perform in patients receiving ECMO support. (2) In this case, the application of AT was evaluated to diagnose BD in a patient followed up with ECMO.

CASE: A six-month-old baby who was treated with ECMO due to cardiogenic shock after congenital heart surgery, was admitted to intensive care unit (ICU). He had clinical signs of BD including Glasgow scale of three with no light reflexes. ECMO settings were pump flow of 2.1ml/dk, and sweep gas (SG) rate of 2lt/dk. He has volume control setting on mechanical ventilation(MV) with 8 ml/kg and respiratory rate of 39/min along with PEEP of 5 and FiO2 of 21%. Fio2 of MV and ECMO have been increased to 100% to prevent hypoxemia. A baseline arterial blood gas had been taken after ten minutes of preoxygenation , and revealed pH: 7.39 paCO2: 43 paO2:168 SaO2:99.4. He was disconnected from MV and inserted a cannula into orotracheal tube with 3lt/min. ECMO SG was decreased to 0.1lt/dk to induce hypercapnia. The five-minute blood gas revealed ph: 7.21 paCO2: 55 paO2: 230 SaO2 : 99.3 and at ten-minutes ph: 7.19 paCO2: 74.5 paO2: 113 SaO2: 98.2. She had positive AT without hemodynamic instability with no intracerebral filling in computed tomography angiography.

DISCUSSION - CONCLUSION: In order to obtain brain death confirmation , neurological examination including AT should be completed which difficult due to CO2 removal of ECMO membrane. Decreasing SG to zero leads hypoxemia and hemodynamic instability due to ECMO. (3) Decreasing SG flow to 0.1lt/dk with increasing FiO2 to 1.0 helped to perform safety AT.

Keywords: APNEA TEST, BRAİN DEATH, EXTRACORPOREAL MEMBRANE OXYGENATİON, ECMO

Pub No: O-098

Anesthesia Management on Adenotonsillectomy Operation for Patient with Biotinidase Deficiency: Case report

Abdurrahman Tünay[1], Özlem Ateşal[1], Mehmet Toptaş[1]

[1]İstanbul Education and Research Hospital

INTRODUCTION - PURPOSE: Biotinidase Deficiency(BD),an autosomal recessive inheritance disease,leads to a disease picture with and different clinical and laboratory findings such as dermatological symptoms,neurological symptoms and organic aciduria(1).The incidence of BE in our country is approximately 8 times the world average, due to the prevalence of consanguineous marriages (2). Untreated BE case may present with different neurological,dermatological indications;Convulsions, hypotonia,hearing problems, optic atrophy,ataxia hair loss, kin problems,respiratory problems can be seen(3).We aimed to present that with a careful pre-operative anesthesia management the symptoms that occur during the disease can be carried out uneventfully.

CASE: Our patient 11 years old male,was regularly receiving biotin treatment with the diagnosis of BD.The patient with normal physical examination and laboratory tests results, was operated in our hospital for adenotonsillectomy operation.Standard monitorization is done for the patient.Anesthesia induction is done by intravenous (IV) 1mcg/kg fentanyl, 2mg/kg propofol, 0,6mg/kg rocuronium bromide.Anesthesia was maintained with 50% air,+ 50% O2 and 2% sevoflurane.No hemodynamic abnormality was observed in the perioperative period.The patient was administered 2mg/kg sugammadex at the end of the 35 minute lasting operation, extubated without any problems, and was discharged to the service as he was stable in terms of hemodynamics and respiration in the recovery room.

DISCUSSION - CONCLUSION: These cases should be handled with a detailed pre-operative anesthetic evaluation and pre-operation preparations should be made against the possibility of difficult airway and difficult intubation.In these cases, neuromuscular blocking agents should be avoided as much as possible due to the possibility of hypotonia. However when necessary, steroid-based neuromuscular blockers can be used because their effects can be reversed with sugammadex.In our case, we used rocuronium and reversed its effect with sugammadex without any problem.Cases who use oral biotin therapy regularly and those who do not receive treatment should undergo a careful preoperative physical examination and anesthesia management should be planned in advance.

Keywords: Biotinidase Deficiency, Anesthesia Management, BD Deficiency

Pub No: O-099

The Use of Amantadine in Traumatic Brain Injury

Kamuran Uluç[1]

[1]Intensive Care Clinic, University of Health Sciences Turkey, Prof.Dr. Cemil Taşçıoğlu City Hospital, Istanbul, Turkey

INTRODUCTION - PURPOSE: Traumatic brain injury (TBI) is a common cause of death among the young population. Serious comorbidities are observed in 10-15% of patients and they are discharged with a vegetative life(1).Amantadine is a dopaminergic agent with N-methyl-D-aspartate antagonist property. Dopaminergic agents are successfully used for influenza prophylaxis, complementary treatment of psychiatric diseases, Parkinson's Disease treatment and in the treatment of consciousness disorders (2).

CASE: The patients we received in our intensive care unit. Case 1: A 19-year-old male patient had epidural hemorrhage after a traffic accident and was operated by neurosurgery and followed up in intensive care with the intubated Glasgow Coma Scale(GCS):5 and 30.the day was discharged. Case 2: A 36-year-old female patient underwent surgery by neurosurgery as a result of the formation of a subdural hematoma as a result of a blow to the head during a fight. GCS:6 was followed up in intensive care as 37.the day was discharged(Table 1). In two of our cases, amantadine sulfate treatment was started as an infusion of 200 mg/day intravenously for 6 hours within the first 1 hour. After 10 days of intravenous treatment, the oral form was switched to 100 mg/day and the treatment was reduced to 20 days.

Table 1 : The course of patients

	Age	***Reason for admission to intensive care unit***	***APACHE II***	***GCS 1.day***	***GCS 5.day***	***GCS 10.day***	***FOUR 1.day***	***FOUR 5.day***	***FOUR 10.day***	***Duration of stay in intensive care***	***Result***
Case 1	19	Traffic accident	17	5	7	11	4	8	14	30	Discharged
Case 2	36	Blow to the head	21	6	9	10	7	10	13	37	Discharged

DISCUSSION - CONCLUSION: TBI is a serious problem that affects millions of people every year. It is a clinical condition with high mortality and morbidity(3). In patients with TBI, damage occurs directly to the tissue and brain metabolism due to the effect of trauma.

Treatment should be started immediately in such patients, as early initiation of the drug will accelerate the patient's neurological recovery. Amantadine therapy can be used as an adjunct to standard therapy, as it accelerates and increases recovery in coma patients.We used the GCS and the Full Outline of Unresponsiveness (FOUR) scale.The FOUR scale reflects the neurological status better in intubated patients(4).

Keywords: Amantadine, Intensive Care Unit, Glasgow Coma Scale (GCS), Full Outline of Unresponsiveness (FOUR) scale, Traumatic Brain Injury

Pub No: O-100

Incomplete Heparin Reversal in Open Heart Surgery: A Case Report

Ayşe Neslihan BALKAYA[1], Damla Bozan GÜLER[1], Buket ÖZYAPRAK[1], Filiz ATA[1], Ümran KARACA[1], Canan YILMAZ[1]

[1]SBÜ Bursa Yüksek Ihtisas Education and Research Hospital

INTRODUCTION - PURPOSE: Heparin is an anticoagulant agent used in cardiopulmonary bypass (CPB) and is neutralized with protamine sulfate rapidy. We aimed to present a case of Incomplete Heparin Reversal (IHR) whose ACT did not return to baseline level after CPB and our applications to normalize the ACT value.

CASE: A 67-year-old male patient with hypertension, hyperlipidemia and coronary artery disease planned for CABG surgery. During the perioperative monitoring patient's baseline ACT value was 146 second (sec). ACT value was measured as 466 sec after 300 U/kg IV heparin was administered before CPB. CPB was applied for 55 min with 32°C hypothermia. After CPB, the patient's hemodynamic parameters were stable, and 300 U/kg IV protamine sulfate was administered for neutralization. Control ACT value was 475 sec and ACT value did not reach to the baseline value with additional protamine sulfate (150 U/kg). After control ACT value was 480 sec, Fresh Frozen Plasma (2 U) and tranexamic acid 10 mg/kg were given and this case was considered as IHR (Table 1). In the ICU, 1000 cc of bleeding from the drains occurred in the 2nd hour and patient was hypotensive so he was taken to bleeding revision surgery. Major bleeding focus was not detected in revision surgery and fibrinogen 1gr was given. ACT value was reached to baseline level at 5th hour (Table 2). Patient was discharged to ward at the 52nd hour postoperatively.

Table 2: Postoperative Anticoagulation Neutralization Treatments and ACT Values in ICU

	Theraphy	ACT (sec)
5. min	Protamine sulfate 150 Ü/kg + Fibrinogen 1 gr	512
30. min	Protamine sulfate 150 Ü/kg + FFP 2 Ü + Fibrinogen 1 gr	352
2. hour	Revision surgery	
3. hour	Cryoprecipitate 3 Ü	292
5. hour	Whole Blood Solution 1 Ü	155

ACT: Activated coagulation time, FFP: fresh frozen Plasma, , sec: second, min: minute

Table 1: Intraoperative Anticoagulation Neutralization Treatments and ACT Values

	Theraphy	ACT (sec)
After CPB 10. min	Protamine sulfate 300 Ü/kg	475
After CPB 15. min	Protamine sulfate 150 Ü/kg	480
After CPB 30. min	FFP 2 Ü +Tranexamic acid 10 mgr/kg	496

CPB: Cardiopulmonary bypass, ACT: Activated coagulation time, FFP: fresh frozen Plasma, sec: second, min: minute

DISCUSSION - CONCLUSION: IHR and heparin rebound phenomenon can be encountered after cardiac surgery with CPB (1). It is stated that protamine infusion up to the 6th hour postoperatively may also be beneficial in these cases (2). In our case, intermittent protamine sulfate was administered. As in our case, fresh frozen plasma, tranexamic acid, fibrinogen, cryoprecipitate and whole blood solution treatment for coagulopathy treatment were also beneficial in the incomplete heparin reversal situations.

Keywords: Incomplete heparin reversal; Cardiopulmonary bypass; Activated coagulation time; Protamine sulfate.

Pub No: O-101

Effect of Palliative Care Clinics on Quality of Life and Survival after Cardiopulmonary Resuscitation: Evaluation of Ten Cases

Sibel OZCAN[1], Muhammet ACAR[1], İsmail DEMIREL[2]

[1]Univeristy of Firat, School of Medicine, Department of Anesthesiology and Reanimation
[2]University of Firat, School of Medicine, Department of Anesthesiology and Reanimation, Intensive Care Unit

INTRODUCTION - PURPOSE: In patients whose spontaneous circulation returns after cardiac arrest (CA), returning to normal life without neurological deficits requires effective post-resuscitation care. Although post-resuscitation care begins where spontaneous circulation returns, it requires follow-up and treatment in intensive care units (ICU) (1). In this study, CA patients followed in palliative care clinic (PCC) after discharge from the ICU were evaluated.

CASE: A total of 10 patients, 3 women and 7 men, with a mean age of 64.5 years (min: 32, max: 91) who were discharged from the ICU after CA and followed up in the PCC were evaluated. Five patients were in-hospital CA and the others were out-of-hospital CA. The reason for the arrest of the patients was cardiac in 6 people, cerebral in 2 patients, uterine atony in 1 person, and Covid-19 in 1 person. Emergency percutaneous coronary intervention was performed in 4 of the CA cases and balloon + stent treatment was applied to 3 patients with stenosis, while normal coronary anatomy was found in 1 patient. The mean resuscitation time in patients was 11.5 minutes, mechanical ventilation time was 27.3 days, and the length of stay (LOS) in the ICU was 35.2 days. Four of the patients had tracheostomy and one of these patients was decannulated in PCC. The LOS of the patients in the PCC was 42.8 (min:2, max:130) days. Seizures due to hypoxic ischemic encephalopathy were observed in 5 of the patients. Four of the patients died in PCC, 2 were transferred to another center, and 4 were discharged to home.

DISCUSSION - CONCLUSION: Palliative care clinics are important in providing the necessary rehabilitation for patients to return to their pre-arrest life after resuscitation.

Keywords: post resucitation care, palliative care clinic, cardiac arrest

Pub No: O-102

Postopretatıve Subcutaneous Emphysema in a Patient with Plevral Bıopsy Surgery: A Case Report

Ali GENÇ[1], Tuğba KARAMAN[2]

[1]Tokat Turhal State Hospital
[2]Tokat Gaziosmanpaşa University

INTRODUCTION - PURPOSE: Subcutaneous emphysema (SCE) most commonly occurs in the chest and neck (1). Crepitation and radiologic imaging are important for diagnosis (1, 2). Here, we will present a case of diffuse skin emphysema after video-assisted thoracic surgery (VATS) and pleural biopsy.

CASE: The 70-year-old patient had chronic obstructive pulmonary disease. The patient's vital signs were normal. After induction of anesthesia, intubation with a double-lumen endotracheal tube was performed, and the patient was transferred to the operating room after the position of the tube was confirmed. The case lasted approximately 3 hours. The patient was extubated and admitted to the intensive care unit. The patient developed an extensive SCE. The patient, who lost consciousness and developed dipsnea, was intubated. The chest tube was controlled, a subcutaneous skin incision and a subcutaneous catheter were placed, and compression massage was performed. The patient was extubated on postoperative day 3. The chest tube was removed on the 4th postoperative day. The patient, whose general condition was good, was admitted to the hospital on the 5th postoperative day.

Postoperative subcutaneous emphysema



DISCUSSION - CONCLUSION: SCE is usually mild to moderate in severity, and treatment of the predisposing factors is often sufficient (3, 4). However, severe SCE can also lead to respiratory failure and death (5, 6). An SCE may be associated with trauma, pneumothorax, infection, malignancy, or surgery (1). SCE in lung surgery is often due to air leakage from the fistula (3). Severe SCE may require endotracheal intubation and insertion of a chest tube (3). Subcutaneous incisions, subcutaneous catheters, and compression massages are beneficial (7). In patients with a chest drain, SCE usually indicates a problem with the drain, which may be obstructed or misplaced (8). If SCE increases, surgical repair of the fistula should be considered.

Keywords: Subcutaneous Emphysema, Pulmonary Surgical Procedures, Airway Management

Pub No: O-103

Is General Anesthesia Only Avaliable Option For Breast Surgery?

Nezir YILMAZ[1]

[1]Adıyaman Training and Research Hospital

INTRODUCTION - PURPOSE: The most frequent malignancy in elderly women is breast cancer. Despite the prevalence of conservative therapies, surgical intervention is frequently necessary. Breast cancer procedures typically employ general anesthetic, although this has been linked to high postoperative pain levels, nausea, and extended hospital stays (1). According to reports, regional anesthetic techniques can be utilized safely on this patient population because they have minimal effect on hemodynamics, respiration and have lower postoperative complication rates (2,3).According to the literature, these individuals with minimal hemodynamic instability can safely use segmental thoracic spinal anesthetic (2,4,5). Regional anaesthetic options that can be utilized for this including spinal anesthesia as well as combinations of antethoracic fascial plane block, erector spina block, thoracic paravertebral block, and thoracic epidural anesthesia techniques (3,6,7,8). The objective of these case reports was to present breast surgery procedures that had been successfully performed under regional anesthetic techniques.

CASE: Case 1: Breast-conserving surgery and axillary dissection was scheduled for a 58-year-old female patient with DM, HT, CAD, and asthma. The patients underwent a parasternal + PECS II + serratus plane block (Figure 1). The procedure lasted approximately an hour. Case 2: An axillary dissection and breast conserving surgery were scheduled for a 56-year-old female patient. The patient, who had difficult airway history, received spinal anesthesia at T5–6. (Figure 2). The procedure lasted nearly 50 minutes.Case 3: An excisional breast biopsy was scheduled for a 33-year-old female patient. The patient, T4 paravertebral block and PECS II block. The procedure lasted for around 30 minutes.

Figure 1



Parasternal + Pecs II + Serratus anterior plane block

Figure 2



Segmental thorasic spinal anesthesia

DISCUSSION - CONCLUSION: Regional anesthesia techniques have advantages over general anesthesia in terms of pain, side effects, and hospital stay. They can also be used safely in situations involving breast surgery where general anesthesia may pose a risk.

Keywords: Regional anesthesia, breast surgery, fascial plane block

Pub No: O-104

Anesthesia Management In Spontaneous Splenic Artery Rupture

Rabia GÜLSÜM AYDIN[1], Tarkan MINGIR[1], Taylan KIRDAN[1]

[1]prof. dr. cemil taşcıoğlu şehir hastanesi

INTRODUCTION - PURPOSE: Splenic artery aneurysms are rare clinical conditions that are usually asymptomatic however carry the risk of rupture and fatal bleeding.The probability of rupture varies between 2-9%.

CASE: A 23-year-old female patient with no remarkable history presented with acute abdomen.The contrast-enhanced abdominal computer tomography showed splenic artery rupture.Physical examination findings included confusion,weak pulse, cold and pale skin.Vital signs showed pulse: 140beats/min bp:40/20mmhg S02:90 respiratory rate of 30 per minute.Induction was performed with 50mg ketamine and 60mg Rocuronium and Intubation was succesful.An arterial line and a central jugular catheter was inserted, peripheral vascular access was granted with 16-18 gauge needles.Complete blood count, blood group, cross-match, blood gas and coagulation tests were done.Initial blood gas showed ph:7.03 p02:70 hc03:9 lactate:9.7 hb:2.3g/dl. Fluid resuscitation was performed and included replacement therapy with 1 gr fibrinogen, 2 amps of calcium gluconate,1gr of tranexamic acid. 0.8 mcg/kg/min neuroadrenaline infusion was initiated in the hypotensive patient.During the surgery a total of 3500cc crystalloid,1000cc colloid,4 units of erythrocyte suspension,2 units of fresh frozen plasma,1 unit of platelet suspension replacement was done. Patient lost approximately 3 liters of blood after the start of the surgery and 1000cc urine output was recorded.Patient was admitted to the ICU,intubated receiving ventilatory support and low-dose neuroadrenaline(0.1mcg/kg/min) infusion.Another 1gr of fibrinogen was given to the patient in the ICU after admission.Blood gas illustrated ph:7.42 pc02:36 p02:164 lactate:3.04 hco3:23.3 hb:9g/dl for the hemodynamically stable patient in ICU follow-up, controlled extubation was planned and performed successfully after the patient regained consciousness on the same day and on the next day the patient was transferred to the general surgery unit

DISCUSSION - CONCLUSION: Minimal fluid resuscitation in the management of patients with critical bleeding requiring massive transfusion,rapid surgical control of bleeding will increase the chances of successful anesthesia management

Keywords: bleeding, splenic artery aneurysms

Pub No: O-105

Anesthesia Management For A Patient With West Syndrome

Mehmet SARI[1], Faruk ÇIÇEKCI[2]

[1]Özel Florya Cerrahi Tıp Merkezi
[2]Selçuk Üniversitesi Tıp Fakültesi Hastanesi

INTRODUCTION - PURPOSE: West syndrome (WS) is a rare malignant epileptic syndromes in early childhood characterized by thetriad of growth retardation, infantile spasm and electroencephalography (EEG) abnormality.(1)However, it is the most common type of epileptic encephalopathy(2). Airway management due to developmental reasons, the possibility of aspiration pneumonia, antiepileptic drugs and vascular access may make anesthesia management more difficult. In this case report, we aim to present anesthesia management in a patient with WS who was planned to have gastrostomy.

CASE: A 9-month-old male patient was operated for gastrostomy. Dozens of seizure activities were observed in intensive care follow-ups. Partial trisomy of the 19th chromosome was detected in the genetic examination, for West syndrome (WS). The patient was consulted with pediatrics subspecialty, and a multidisciplinary preoperative evaluation was made. Mallampati score was III. Family informed consent was obtained for the patients parents. All alternative airway devices were kept ready in the OR in case of difficult intubation due to micrognathia. After the patient was preoxygenated with 100% O2 for 3 minutes, induction was made. Then, endotracheal intubation was performed with a 5mm ID endotracheal tube without any problems. Anesthesia maintenance is sevoflurane. Ventilation was provided with EtCO2 of 30-40 mmHg. The patient, who did not have any intraoperative problems, was taken to the pediatric intensive care unit at the end of the surgery.

patient picture



micrognatia

DISCUSSION - CONCLUSION: It should be considered that West syndrome requires a multidisciplinary approach in preoperative preparation and the patient may have difficulties in terms of difficult intubation and peripheral vascular access. The drugs used by these patients and their side-effect profile should be considered.We think that good anesthesia management will be achieved by providing a good depth of anesthesia and analgesia during the surgery and avoiding situations that will lower the convulsion threshold such as hypoxia and hypocarbia.

Keywords: West Syndrome, Infantile spasm, Anesthesia management

Pub No: O-106

Peng Block In Patient With Hip Prosthesis Planned: A Case Report

Ali GENÇ[1], Ahmet Tuğrul ŞAHİN[2]

[1]Tokat Turhal State Hospital
[2]Tokat State Hospital

INTRODUCTION - PURPOSE: Hip fractures can lead to a serious increase in mortality and morbidity rates, especially in the elderly (1, 2). In the coming years, hip fractures are expected to increase with the aging of the population (1). Peripheral nerve blocks are an effective method for perioperative pain control. Here, we present a case in which pericapsular nerve block (PENG) and hip replacement surgery were performed with spinal anesthesia.

CASE: The 82-year-old patient, who was scheduled for hip replacement due to a hip fracture, suffered from hypertension. The patient's vital signs were normal. The patient was blocked with 30 ml of 0.25% bupivacaine under ultrasound guidance at PENG. After spinal anaesthesia, the patient was transferred to the operating room. The procedure lasted approximately 2 hours. The patient, whose general condition was good, was sent for service. Apart from paracetamol, which was routinely administered in the first 24 hours after surgery, he did not require analgesics. The patient, who was mobilised at the 10th postoperative hour without complications, was discharged on the 2nd postoperative day.

DISCUSSION - CONCLUSION: Peripheral nerve blocks provide effective pain control, increase patient satisfaction, allow early discharge, and reduce costs (2, 3). The benefits of fascia iliac compartment block, femoral nerve block, and PENG block in hip surgery have been demonstrated (1, 2). PENG block was defined in 2018 to block the articular branches of the femoral nerve, obturator nerve, and accessory obturator nerve (4). PENG block provides pain control without motor blockade (5, 6). PENG block has been shown to reduce postoperative opioid consumption and provide benefits during mobilization and early ambulation (1, 2, 4). In addition, PENG block reduces pain during positioning for spinal anesthesia (1).In conclusion, PENG -block is one of the basic building blocks of perioperative multimodal analgesia for hip surgery.

Keywords: Hip fractures, Analgesia, Nerve block

Pub No: O-107

Do Different Urine Colors Mean Different Things?: A Case Report

Murad KAYA[1], Pınar KÜÇÜKDEMIRCI KAYA [1], Remzi İŞÇIMEN [1]

[1]Bursa Uludag University Faculty of Medicine/ Department of Anesthesiology and Reanimation/ Intensive Care Unit

INTRODUCTION - PURPOSE: Purple urine bag sydrome (PUBS) is a rare syndrome which is welding by urinary tract infections (UTIs)1. PUBS is the result of UTIs with specific bacteria that produce sulphatases and phosphatases which lead to produce blue (indigo) and red (indurubin) pigments2.

CASE: 71-year-old women admitted to intensive-care-unit (ICU) due to multiple-organ-failure via septic shock on the 15th day of her treatment in the chest-diseases clinic for respiratory failure and pneumonia. She had history of asthma, diabetes mellitus, hypertension and, relatively mild renal-failure, with eGFR of 50 mL/min/1.55m2. Her lactate level 16 mmol/L, c-reactive-protein(CRP) value 102mg/L and procalcitonin level 0.67 ng/mL were observed on admission. non-invasive-ventilation was started due to respiratory-failure. She received treatment with fluid resuscitation and norepinephrine to maintain mean blood pressure above 65 mmHg. Without waiting for the culture results, the reason was accepted as pneumonia and antimicrobial therapy was started immediately. Under this treatment the patient could be successfully stabilized, norepinephrine stopped on 2nd day and a lactate level of 4 mmol/ L was observed. Although CRP and procalcitonin level continued to increase during next 3 days. On the 3th day of admission to ICU, patient's urine collection bag colored a purple discolouration (figure1) with clear urine on urethral catheter. Considering that the cause of the patient's sepsis could be UTI, she was immediately consulted with the infectious-diseases clinic and meropenem was added to her antibiotic therapy. Procalcitonin and CRP values decreased to normal range at the 72nd hour of meropenem treatment. She was discharged on 8th ICU-day. The article was prepared by obtaining the consent of patient's husband.

PUBS



DISCUSSION - CONCLUSION: Current guidelines recommend empiric antibiotics3 based on initial history, that may result in inappropriate therapies for patients. However, it may possible to start appropriate therapy before culture results, even by detecting to urine color changes.

Keywords: Purple urine bag sydrome (PUBS), septic schock, empiric antibiotics

Pub No: O-108

Seizure Management After Oxytocine Administration In Ceseran Section

DR Eda ALTUNBAĞ[1], DR Furkan KAYA[1], DR Sedat SAYLAN[1]

[1]KARADENIZ TECHNICAL UNIVERSITY HEALTH APPLICATION AND RESEARCH CENTER FARABI HOSPITAL,DEPARTMENTOF ANESTHESIOLOGY AND REANIMATION

INTRODUCTION - PURPOSE: Oxytocin is a polypeptide hormone produced in the paraventricular nucleus of the hypothalamus and secreted by the posterior pituitary gland, used uterotonically in the induction of normal labor and cesarean section operations. It is widely used to prevent postpartum hemorrhage by increasing the contraction of the uterus. (1,2)

CASE: Physical examination and laboratory values of a 33-year-old female patient with a history of asthma and hypothyroidism, were normal. She was considered in ASA 2 risk class. Spinal anesthesia was applied to the patient by administering 2 ml of 0.5% heavy bupivacaine through the L3-4 interval. The patient, whose hemodynamics was stable after spinal anesthesia, was administered 25 IU oxytocin infusion upon the recommendation of the obstetrician after the evacuation of the baby. During the infusion, focal convulsions were observed and her GCS decreased. Oxygen saturation, respiratory rate and blood pressure were normal but tachycardia was observed. A bolus of 2 mg of midazolam was administered, 50 mg of pentothal was added when the seizure continued. Her seizures stopped. The patient was transferred to the ICU for close follow-up. The patient, who did not have seizures in the postoperative 24-hour period, was transferred to the Obstetrics and Gynecology Service after close follow-up.

DISCUSSION - CONCLUSION: Overstimulation with oxytocin may result in tetanic contraction, fetal hypoxia, or uterine rupture. Also, parenteral doses, especially when administered as a single rapid injection, may cause cardiovascular effects including tachycardia, hypotension and electrocardiographic changes, as in our patient. It also increases water reabsorption with its vasopressin-like effect. High doses may cause water intoxication, hyponatremia, and convulsions. (3) In conclusion, care should be taken about the side effects of oxytocin used during cesarean section, iv bolus doses should be avoided, and it should be administered carefully by taking necessary precautions in patients with a history of seizures.

Keywords: oxytocin, cesarean section, seizure, convulsion, spinal anesthesia

Pub No: O-109

Pulmonary Edema After General Anesthesia

Leman ACUN DELEN[1]

[1]Malatya Eğitim Araştırma Hastanesi

INTRODUCTION - PURPOSE: Negative pressure pulmonary edema is a complication that may develop after acute upper airway obstruction or secondary to relief of chronic upper airway obstruction (1). Forced inspiratory effort caused by acute upper respiratory tract obstruction during any period of anesthesia applications increases negative intrathoracic pressure and triggers physiopathological events resulting in pulmonary edema (2). Early diagnosis and treatment is very important in the postoperative period. (3)

MATERIALS AND METHODS: The development of pulmonary edema during the extubation period in a 27-year-old patient

RESULTS: Our patient is a 27-year-old female patient, 162 cm tall and weighing .85 kg; when the diagnosis of acute appendicitis was diagnosed, she was operated under general anesthesia as an emergency. Induction and intubation were performed in a standard way. Severe laryngospasm developed within a few minutes in the patient who did not encounter any problems while being extubated. Positive pressure ventilation with 1.0 FiO2, 1.5 mg/kg prednisolone, 1 amp aminocardol, 2 ampoules of furosemide, ventolin inhaler treatment was given to the patient whose SpO2 fell below 75%. The chest X-ray taken under emergency conditions showed an image supporting pulmonary edema. Since pulmonary edema in the patient responded rapidly with medical treatment, respiratory support was not needed other than nasal mask and oxygen support. He was externed to the ward after 24 hours in the postoperative period.

DISCUSSION - CONCLUSION: Negative pressure pulmonary edema has been classified into 2 types, each with similar clinical manifestations but different etiologies. Type 1 has been reported to be caused by infections such as epiglottitis or croup, foreign body effect, subglottic edema developing after post-extubation, laryngospasm developing after post-extubation, as well as hanging suffocation and anatomical anomalies (4). Type 2 is encountered in the postoperative period after intubation in asthmatic or obstructive sleep apnea syndrome patients with chronic airway obstruction(5)

Keywords: Negative pressure pulmonary edema, laryngospasm, general anesthesia

Pub No: O-110

Is There A Relationship Between The First Successful Endotracheal Intubation Attempt And The Final Exam Scores In Anesthesia Technician Students?

Aysen BAYSAN[1], Erhan OZYURT[1]

[1]University of Health Sciences Antalya Training and Research Hospital

INTRODUCTION - PURPOSE: Endotracheal intubation (ETI) practice is fundamental in anesthesia practice. In Sudan, ETI attempting after mannequin practice is almost impossible for healthcare providers. In this study, we aimed to research if there is a relationship between final exam scores and the first successful ETE attempt in anesthesia technician trainees.

MATERIALS AND METHODS: This retrospective study was conducted in the Health Sciences University Sudan Nyala Vocational School of Health Services anesthesia technician program during the second semester of the 2021-2022 academic year. The students took Turkish, English, anatomy, physiology, pharmacology and medical terminology lectures the prior year. Then, students were verbally given basic anesthesiology and ETI lectures in Turkish and then advised to watch three predetermined sites both Turkish and English language on the web. ETI practice planned on the ASA I-II, Mallampati score 1-2 patients. Students' first direct laryngoscopy performance checked by the same lecturer and let the students do ETI by checking auscultation. Success scores were recorded.

RESULTS: 41 out of 65 students met the inclusion criteria. 29 (% 70.7) students were successful in ETI. We could not detect a difference between intubation success and final exam results ($p > 0.05$).

Table 1 The relationship between the success of intubation and given lectures' final exam results

Lectures	Intubation (+) n= 29 (%70.7)	Intubation (-) n= 12 (% 29.3)	P value
Anesthesia applications	66.2 ± 10.3	67.3 ± 9.2	0.752
Anesthesia devices	60.9 ± 14.3	58.7 ± 14.7	0.661
English	67.2 ± 12.9	66 ± 12.2	0.789
Turkish	61.6 ± 13.2	61.8 ± 11.5	0.962
Anatomy	71.1 ± 12.4	71.4 ± 13.6	0.949
Physiology	57.4 ± 10.7	56.3 ± 11.3	0.765
Pharmacology	62 ± 14.1	57.5 ± 15.1	0.365
Medical terminology	75.7 ± 14	72.4 ± 17.2	0.541

DISCUSSION - CONCLUSION: Most African countries like Sudan didn't have adequate education facilities for student education. Therefore performing the first ETI on the patient is essential in student education. In this study, we did not find a significant difference between the exam scores of the lecturers given and the initial ETI success of the students.

Keywords: endotracheal intubation, education, Anesthesia technicians

Pub No: O-111

CAN SARS-Cov2 VACCINE (SINOVAC) CAUSE DERMATOMYOSITIS?

Nermin BALTA BAŞI[1], İbrahim TURNA[1], Seyhan METIN[1], Sultan ACAR SEVINÇ[1], Ayşe SURHAN ÇINAR[1], Sibel OBA[1]

[1]Sisli Hamidiye Etfal Training and Research Hospital

INTRODUCTION - PURPOSE: Vaccination procedures for SARS-CoV-2 have been started worldwide after pandemic. There is not enough data on the side effects of vaccines. There are not enough cases of dermatomyositis (DM) reported after COVID-19 vaccination in the literature. Acutely emerging dermatomyositis; It may be due to various malignancies, especially gastrointestinal tumors[1]. Clinic side effects of dermatomyositis can be seen after COVID-19 vaccination, and/or tumor cases may occur with different clinics due to delayed diagnosis after the pandemic.

CASE: A 63-year-old female patient has no known additional disease and no history of drug use. The patient received 2 doses of Sinovac vaccine between February and March 2021. Widespread muscle weakness and skin manifestations occurred within about a week. The patient was admitted to the internal medicine service on 13 March 2021. The treatment was started with the diagnosis of dermatomyositis. With ground glass opacity areas in the lung on PET CT, COVID-19 was detected in the patient and was transferred to the COVID service (09 April 2021). COVID-19 treatment was started. When the PCR is (-), patient was transferred to the internal medicine service. As a result of the DM etiology investigations, a tumor was found in the cecum. The patient underwent right hemicolectomy operation due to cecum tumor on 01 September 2021. General anesthesia was applied by inserting an epidural catheter through the L1-2 space. Postoperative analgesia was provided with epidural patient-controlled analgesia. There was no problem in terms of anesthesia management peroperatively.

DISCUSSION - CONCLUSION: It is predicted that viruses and vaccines trigger autoimmune inflammatory myopathies together with environmental factors. In the literature, DM cases have been found after Influenza A(H1N1), Tetanus, HBV, BCG vaccinations[2] . Dermatomyositis is usually of tumor origin. The fact that DM emerged in our case in the early post-vaccine period may have shortened the patient's diagnosis of tumor.

Keywords: COVID-19, Sinovac vaccine, Dermatomyositis, Tumor

Pub No: O-112

Should Encephalopathy Grade 3 Patients Be Intubated?

Ilhan OCAK[1]

[1]Basaksehir Cam and Sakura City Hospital,Istanbul,Turkey

INTRODUCTION - PURPOSE: It is accepted that high ammonia levels in acute and chronic liver failures cause hepatic encephalopathy. It is stated in the literature and algorithms that patients with encephalopathy 3 and above should be intubated1,2,3.In our study, we applied non-invasive mechanical ventilation (NIMV) instead of intubation to patients with grade 3 hepatic encephalopathy who were diagnosed with liver failure in our tertiary intensive care unit.We followed his complications.

MATERIALS AND METHODS: We retrospectively analyzed the records of the patients who were followed up in the Organ Transplantation and Hepato-pancreato-Bilier Surgery Intensive Care Unit of Başakşehir Çam and Sakura City Hospital between July 2021 and July 2022. Seventeen of these patients had hepatic encephalopathy between grades I and IV due to acute or chronic liver failure.Non-invasive mechanical ventilation (NIMV) was applied to 9 patients with encephalopathy grade III in this group.Table 1 presents the NIMV values.Artificial liver support treatment was also continued for these patients.Acute physiology and chronic health evaluation (APACHE II), West Haven Classification and Glasgow Coma Score (GCS) were used.

Table 1. Non-invasive Mechanical Ventilator values

Table 1. Non-invasive Mechanical Ventilator values.	
NIMV parameter.	Mean(Range)
PEEP (cmH2O)	8(6-10)
Psupport(cmH2O)	14(10-16)
Fio2	0,40 (0,35-0,55)
NIMV duration(days)	6(4-9)
Spo2(%)	99(97-100)

PEEP: Positive End-Expiratory Pressure, Psupport: Support pressure, FiO2:Fraction of inspired oxygen, NIMV: Non-Invasive Mechanical Ventilation, SpO2: Peripheral oxygen saturation

RESULTS: 17 patients consisted of 6 women and 11 men. The mean age was 51 (35-64).Oxygen support at 2-4 lt/min was provided to 8 patients in this group with encephalopathy I-II.NIMV was applied to 9 patients with encephalopathy grade III.Encephalopathy, which was grade III, of 2 patients in the NIMV group was grade IV. Orotracheal intubation was performed.There was recovery in 5 patients who underwent NIMV. They were taken to the service.Two patients had liver transplantation.There were no respiratory complications in the follow-up of these patients.

DISCUSSION - CONCLUSION: Intubation of patients with encephalopathy above grade III is widely used in accordance with the literature and algorithms. In this retrospective study, we came to the conclusion that patients with encephalopathy garade III can be administered NIMV, under appropriate environment and intensive monitoring, instead of being intubated.

Keywords: Hepatic Encephalopathy, Liver Failure, Non-Invasive Mechanical Ventilation

Pub No: O-113

Gender Distribution Of Editorial Board Members In Critical Care Journals: Assessment Of Gender Parity

Mehmet Nuri YAKAR[1], Rıza Kaan KÖŞKER[2], Emel İBIŞOĞLU[2], Fevzi KARA[2], Volkan HANCI[1]

[1]Division of Intensive Care, Department of Anaesthesiology and Reanimation, Faculty of Medicine, Dokuz Eylul University, İzmir, Turkey
[2]Department of Anaesthesiology and Reanimation, Faculty of Medicine, Dokuz Eylul University, İzmir, Turkey

INTRODUCTION - PURPOSE: Gender disparity is a crucial problem in medicine and has been debated more than ever in recent years (1-6). However, gender diversity on editorial boards of critical care journals remains unclear. This cross-sectional study aims to analyze the gender distribution of editorial board members of critical care journals and reveal the independent factors related to gender diversity.

MATERIALS AND METHODS: The study was approved by the local ethics committee (Date:31.08.2022 and number:2022/28-07). Editorial board members of the critical care journals indexing in Web of Science, Science Citation Index-Expanded core collection were enrolled in the study. Participants' genders were defined according to first names/pictures obtained from journals' websites between 01 and 30 September 2022. Publisher properties and journal metrics were also recorded. Chi-square, Fisher exact, Mann–Whitney U tests, and Spearman's correlation coefficient were used for the analysis. Independent factors related to gender diversity were revealed by using logistic regression analysis.

Figure 1. Flowchart of the study



RESULTS: Women's representation on editorial boards and among editors-in-chief were 23.6% and 11.1%, respectively. The United States of America (odds ratio [OR], 0.04, 95% confidence interval [CI], 0.01–0.15, p < 0.001) and Netherlands (OR, 0.04, 95% CI, 0.01–0.16, p < 0.001) as publisher's countries, an IF > 5 (OR, 0.25, 95% CI, 0.17–0.38, p < 0.001), publication duration < 30 years (OR, 0.09, 95% CI, 0.06–0.12, p < 0.001), multidisciplinary perspective of editorial policy (OR, 0.46, 95% CI, 0.32–0.65, p < 0.001), journals categorized in critical care medicine and nursing (OR, 0.38, 95% CI, 0.22–0.66, p < 0.001), and being a section editor (OR, 0.49, 95% CI, 0.32–0.74, p = 0.001) were associated with gender parity. Europe as a journal continent (OR, 36.71, 95% CI, 8.39–160.53, p < 0.001) was related to gender disparity.

Table 1. The catalog info, publication properties, and metrics of the journals

Journals	Country		Language	CCQ	IF	IF (5-year)	H-index	H-index* (Z-year)	First publication	Publication counts†	
	Journal	Publisher								PubMed	WoS
Journal of Trauma Nursing	USA	USA	English	Q4	1.010	1.433	20	3	1994	1041	581
Australian Critical Care	Australia	USA	English	Q3	2.737	3.096	35	9	1992	1165	1510
American Journal of Critical Care	USA	USA	English	Q4	2.280	3.330	73	10	1991	2555	1786
Intensive Care Medicine	USA	USA	English	Q1	17.440	19.180	-	40	1980	12004	23232
Medicina Intensiva	Spain	Spain	Spanish	Q3	2.491	2.302	29	9	1973	1924	1807
Chest	USA	Netherlands	English	Q1	9.410	10.131	-	32	1970	36712	54208
American Journal of Respiratory and Critical Care Medicine	USA	USA	English	Q1	21.405	19.393	-	37	1917	17839	96507
Journal of Neurotrauma	USA	USA	English	Q1	5.269	5.452	-	14	1988	5361	12933
Critical Care Medicine	USA	USA	English	Q1	7.598	8.416	-	27	1973	22832	48821
Neurocritical Care	USA	USA	English	Q3	3.210	3.502	78	10	2004	2873	2879
Anasthesiologie & Intensivemedizin Notfallmedizin Schmerztherapi	Germany	Germany	German	Q4	0.698	0.442	22	2	1966	3467	3368
Pediatric Critical Care Medicine	USA	USA	English	Q2	3.624	4.090	83	12	2000	5156	4429
Respiratory Care	USA	USA	English	Q3	2.258	2.763	74	9	1971	5059	3992
Journal of Trauma and Acute Care Surgery	USA	USA	English	Q3	3.313	3.824	89	13	1961	4876	5177
Resuscitation	Ireland	Ireland	English	Q1	5.262	6.192	141	24	1972	9058	8926
Critical Care	UK	UK	English	Q1	9.097	9.372	141	40	1997	8448	8633
Critical Care Nurse	USA	USA	English	Q4	1.708	2.493	41	6	1980	3237	2857
Shock	USA	USA	English	Q2	3.454	3.826	-	15	1994	5458	12587
Journal of Critical Care	USA	USA	English	Q2	3.425	3.759	91	15	1986	4303	4553
Burns	UK	UK	English	Q3	2.744	3.240	105	9	1989	6941	7358
Anasthesiologie & Intensivemedizin	Germany	Germany	German	Q4	1.000	0.940	22	4	1960	-	3415
Current Opinion in Critical Care	USA	USA	English	Q2	3.687	3.642	77	9	1995	2113	1671
Journal of Intensive Care Medicine	USA	USA	English	Q2	3.510	3.257	36	13	1986	1643	1341
Therapeutic Hypothermia and Temperature Management	USA	USA	English	Q4	1.286	1.474	18	4	2011	468	581
Seminars in Respiratory and Critical Care Medicine	USA	USA	English	Q3	3.119	3.534	66	6	1994	1638	2055
Injury-International Journal of the Care of Injured	UK	UK	English	Q3	2.586	3.077	-	15	1969	12794	12245
Annals of Intensive Care	Germany	USA	English	Q1	6.925	6.068	67	20	2011	1215	1217
Journal of Intensive Care	UK	UK	English	Q2	3.954	4.620	45	13	2013	640	642

Abbveriations: IF, impact factor; CCQ, cataloging and classification quarterly; WoS, Web of Science; USA, United States of America; UK, United Kingdom. *Calculated for the journals with less than ten thousand publications on the day of September 12, 2022. †Recorded on the day of September 12, 2022.

Table 2. Gender distribution in the journals' editorial boards and of editor-in-chiefs

Journals	Editorial board		Editor-in-chief		
	Women (n=422)	Men (n=1368)	Number (n=36)	Women (n=4)	Men (n=32)
Journal of Trauma Nursing	12 (92.3)	1 (7.7)	1	1	0
Australian Critical Care	27 (77.1)	8 (22.9)	1	1	0
American Journal of Critical Care	19 (67.9)	9 (32.1)	2	1	1
Intensive Care Medicine	7 (43.7)	9 (56.3)	1	0	1
Medicina Intensiva	3 (42.9)	4 (57.1)	1	0	1
Chest	58 (36.3)	102 (63.8)	1	0	1
American Journal of Respiratory and Critical Care Medicine	16 (34.8)	30 (65.2)	1	0	1
Journal of Neurotrauma	20 (29.0)	49 (71.0)	1	0	1
Critical Care Medicine	35 (28.2)	89 (71.8)	1	0	1
Neurocritical Care	17 (27.9)	44 (72.1)	1	0	1
Anasthesiologie & Intensivemedizin Notfallmedizin Schmerztherapi	4 (26.7)	11 (73.7)	1	1	0
Pediatric Critical Care Medicine	26 (25.5)	76 (74.5)	1	0	1
Respiratory Care	14 (24.6)	43 (75.4)	1	0	1
Journal of Trauma and Acute Care Surgery	31 (23.3)	102 (76.7)	1	0	1
Resuscitation	16 (21.9)	57 (78.1)	1	0	1
Critical Care	15 (19.5)	62 (80.5)	1	0	1
Critical Care Nurse	15 (19.5)	62 (80.5)	1	0	1
Shock	23 (17.4)	109 (82.6)	1	0	1
Journal of Critical Care	11 (17.2)	53 (82.8)	1	0	1
Burns	12 (16.0)	63 (84.0)	1	0	1
Anasthesiologie & Intensivemedizin	4 (14.8)	23 (85.2)	7	0	7
Current Opinion in Critical Care	4 (14.3)	24 (85.7)	1	0	1
Journal of Intensive Care Medicine	5 (13.2)	33 (86.8)	1	0	1
Therapeutic Hypothermia and Temperature Management	7 (11.7)	53 (88.3)	1	0	1
Seminars in Respiratory and Critical Care Medicine	3 (10.7)	25 (89.3)	2	0	2
Injury-International Journal of the Care of Injured	9 (8.6)	96 (91.4)	1	0	1
Annals of Intensive Care	6 (8.2)	67 (91.8)	1	0	1
Journal of Intensive Care	3 (4.5)	64 (95.5)	1	0	1

All values are expressed as numbers (percentages)

Table 3. Factors related to gender distribution in editorial boards of the journals

Journal metrics and publication properties	All (n=1790)	Gender distribution: Women (n=422)	Gender distribution: Men (n=1368)	*p* value
The role of editor				
Editor in chef	36 (2.0)	4 (0.9)	32 (2.3)	0.11
Associate editor	264 (14.7)	62 (14.7)	202 (14.8)	1.00
Section editor	166 (9.3)	50 (11.8)	116 (8.5)	**0.043**
Editorial board member	1324 (74.0)	306 (72.5)	1018 (74.4)	0.35
Publisher's country				
United States of America	1184 (66.1)	298 (70.6)	886 (64.8)	**0.029**
United Kingdom	324 (18.1)	39 (9.2)	285 (20.8)	**< 0.001**
Netherlands	160 (8.9)	58 (13.7)	102 (7.5)	**< 0.001**
Ireland	73 (4.1)	16 (3.8)	57 (4.2)	0.89
Germany	42 (2.3)	8 (1.9)	34 (2.5)	0.58
Spain	7 (0.4)	3 (0.7)	4 (0.3)	0.37
Journal's country				
United States of America	1236 (69.1)	323 (76.5)	913 (66.7)	**< 0.001**
United Kingdom	324 (18.1)	39 (9.2)	285 (20.8)	**< 0.001**
Germany	115 (6.4)	14 (3.3)	101 (7.4)	**0.002**
Ireland	73 (4.1)	16 (3.8)	57 (4.2)	0.89
Australia	35 (2.0)	27 (6.4)	8 (0.6)	**< 0.001**
Spain	7 (0.4)	3 (0.7)	4 (0.3)	0.37
Publisher's continent				
America	1184 (66.1)	298 (70.6)	886 (64.8)	**0.029**
Europe	606 (33.9)	124 (29.4)	482 (35.2)	**0.029**
Journal's continent				
America	1236 (69.1)	323 (76.5)	913 (66.7)	**< 0.001**
Europe	523 (29.0)	72 (17.1)	447 (32.7)	**< 0.001**
Australia	35 (2.0)	27 (6.4)	8 (0.6)	**< 0.001**
Primary language				
English	1741 (97.3)	411 (97.4)	1330 (97.2)	1.00
German	42 (2.3)	8 (1.9)	34 (2.5)	0.58
Spanish	7 (0.4)	3 (0.7)	4 (0.3)	0.37
Impact factor (2021)	3.45 (2.74-6.93)	3.48 (2.74-7.60)	3.45 (2.74-6.93)	0.16
5-year impact factor	3.83 (3.24-6.19)	3.83 (3.24-8.42)	3.83 (3.24-6.19)	**0.041**
Impact factor > 5	638 (35.6)	173 (41.0)	465 (34.0)	**0.010**
Publication count			..	
Web of Science	5177 (2857-12587)	6268 (2879-48821)	5177 (2857-12587)	**0.014**
PubMed	5156 (3237-12004)	5361 (2873-17839)	5156 (3237-9058)	0.09
H-index	78 (45-91)	78 (41-89)	78 (45-91)	0.15
2-year H-index	14 (10-24)	14 (10-27)	14 (10-24)	0.63
Publication duration, years	33 (24-50)	33 (27-50)	33 (24-50)	**0.015**
Publication duration < 30 years	414 (23.1)	186 (44.1)	228 (16.7)	**< 0.001**
CCQ				

Q1	638 (35.6)	173 (41.0)	465 (34.0)	**0.010**
Q2	431 (24.1)	72 (17.1)	359 (26.2)	**< 0.001**
Q3	501 (28.0)	116 (27.5)	385 (28.1)	0.85
Q4	220 (12.3)	61 (14.5)	159 (11.6)	0.13

All values are expressed as number (percentages) or median (interquartile range).
Abbveriations: CCQ, cataloging and classification quarterly

Table 4. Journals' categories and properties of linked organizations

Journals' categories and properties of linked organizations	**All (n=1790)**	**Gender distribution**		
		Women (n=422)	**Men (n=1368)**	***p* value**
Web of Science Coverage Category				
Critical Care Medicine	554 (30.9)	96 (22.7)	458 (33.5)	**< 0.001**
Critical Care Medicine, and Respiratory System	291 (16.3)	91 (21.6)	200 (14.6)	**0.001**
Critical Care Medicine, and Nursing	153 (8.5)	73 (17.3)	80 (5.8)	**< 0.001**
Critical Care Medicine, and Surgery	133 (7.4)	31 (7.3)	102 (7.5)	1.00
Critical Care Medicine, Peripheral Vascular Diseases, Surgery, and Hematology	132 (7.4)	23 (5.5)	109 (8.0)	0.09
Critical Care Medicine, Emergency Medicine, Orthopedics, and Surgery	105 (5.9)	9 (2.1)	96 (7.0)	**< 0.001**
Critical Care Medicine, and Pediatrics	102 (5.7)	26 (6.2)	76 (5.6)	0.63
Critical Care Medicine, Surgery, and Dermatology	75 (4.2)	12 (2.8)	63 (4.6)	0.13
Critical Care Medicine, and Emergency Medicine	73 (4.1)	16 (3.8)	57 (4.2)	0.89
Critical Care Medicine, Neurosciences, and Clinical Neurology	69 (3.9)	20 (4.7)	49 (3.6)	0.31
Critical Care Medicine, and Clinical Neurology	61 (3.4)	17 (4.0)	44 (3.2)	0.44
Critical Care Medicine, and Anesthesiology	42 (2.3)	8 (1.9)	34 (2.5)	0.58
Disciplinarity				
Uni-disciplinary	554 (30.9)	96 (22.7)	458 (33.5)	**< 0.001**
Multidisciplinary	1236 (69.1)	326 (77.3)	910 (66.5)	**< 0.001**
Journal's linked organization				
Independent	231 (12.9)	34 (8.1)	197 (14.4)	**< 0.001**
Society	1364 (76.2)	303 (71.8)	1061 (77.6)	**< 0.001**
For physicians	1246 (69.6)	257 (60.9)	989 (72.3)	**< 0.001**
For nurses	118 (6.6)	46 (10.9)	72 (5.3)	**0.001**
Educational organization	222 (12.4)	89 (21.1)	133 (9.7)	**< 0.001**
For physicians	187 (10.4)	62 (14.7)	125 (9.1)	**0.007**
For nurses	35 (2.0)	27 (6.4)	8 (0.6)	**< 0.001**
National	703 (39.3)	193 (45.7)	510 (37.3)	**0.002**
Regional	111 (6.2)	510 (37.3)	81 (5.9)	0.42
International	745 (41.6)	165 (39.1)	580 (42.4)	0.24

All values are expressed as number (percentages) or median (interquartile range).

Table 5. Logistic regression analysis for independent factors related to gender diversity on editorial boards of critical care journals

Factors related to gender diversity	OR (95% CI)	*p* value
Publisher country		
USA	0.04 (0.01–0.15)	**< 0.001**
Netherlands	0.04 (0.01–0.16)	**< 0.001**
UK	1.64 (0.78–3.43)	0.19
2021 - Impact factor > 5	0.25 (0.17–0.38)	**< 0.001**
Publication duration < 30 years	0.09 (0.06–0.12)	**< 0.001**
Multidisciplinary perspective of editorial policy	0.46 (0.32–0.65)	**< 0.001**
Categorized in Critical Care Medicine and Nursing	0.38 (0.22–0.66)	**< 0.001**
Being a section editor	0.49 (0.32–0.74)	**0.001**
Journal continent		
Europe	36.71 (8.39–160.53)	**< 0.001**
Journal country		
Australia	0.49 (0.18–1.35)	0.17
Germany	0.81 (0.27–2.41)	0.71
Cataloging and Classification Quarterly		
Q2	1.04 (0.71–1.52)	0.81
Journals linked to a national organization	1.02 (0.72–1.46)	0.90

Abbreviations: OR, odds ratio; USA, United States of America; UK, United Kingdom.

DISCUSSION - CONCLUSION: Further efforts are needed to expand diversity policies to foster fair conditions for all persons in critical care medicine.

Keywords: Gender, gender disparities, parity, critical care, intensive care

Pub No: O-114

Comparison Of Parenteral Fentanyl And Morphine Infusion Treatment In Chronic Cancer Pain Management

Nigar KANGARLI[1]

[1]SBU Haydarpaşa EAH

INTRODUCTION - PURPOSE: Ladder step treatment is used in hospitalized patients with moderate and severe pain symptoms. The third step includes powerful opioid agents, which in our case are morphine and fentanyl. The primary purpose of our study is to measure pain symptom relief by evaluating the pain scores after intravenous continuous infusion of these opioids. Our second main goal is to compare the morphine equivalent dose (MED, mg) administered to both groups within 72 hours. Our study aimed to compare the frequency of new side effects in both groups.

MATERIALS AND METHODS: The study was constructed as observational and prospective. Sixty-eight patients who met the exclusion and inclusion criteria were included in fentanyl (n / 34) and morphine (n / 34) groups. Patients who were admitted to the palliative care unit were administered a continuous intravenous infusion of morphine and fentanyl at equal analgesic doses, using an elastomeric pain pump, based respectively on the opioid agents and doses patients used to consume previously and were followed up for 3 days. For the management of breakthrough pain, 5-15% of the daily opioid dose was administered in both groups. Daily pain scores, breakthrough pain scores, basal infusion doses, breakthrough pain doses, laboratory tests and hemodynamic parameters of the patients were recorded.

RESULTS: Faster pain score regression and lower total opioid döşe requirements were found in the fentanyl group. There was no significant difference between the groups in terms of adverse effects.

DISCUSSION - CONCLUSION: According to our study, we found out that continuous parenteral fentanyl infusion is superior to continuous parenteral morphine infusion in patients with chronic cancer pain during acute pain exacerbations. Thus, we suggest that the parenteral administration of fentanyl may be a more advantageous alternative to morphine, and we believe that larger, randomized prospective researches are necessary to be conducted on this issue.

Keywords: Fentanyl, Morphine, Cancer pain, Opioid adverse effects, Equianalgesic doses

Pub No: O-115

Our Anesthesia Experience in Pediatric Burn Patients: A Retrospective Analysis of the Burn Center

Serra TOPAL[1], Ayça SAYAN[1], Zeynep TABUR GÜMÜŞKANAT[1], Banu OTLAR CAN[1], Abdulkadir İSKENDER[1]

[1]Health Sciences University Bursa Medical Faculty, Bursa City Hospital, Anesthesiology and Reanimation Clinic,Bursa,Turkey

INTRODUCTION - PURPOSE: Pathophysiological changes may occur in burn patients that require careful and difficult management of anesthesia.The face and neck burns may require difficult airway management.We aimed to evaluate the demographic data,the method of anesthesia and diffucult airway management ,mortality of pediatric cases that are operated in our burn center.

MATERIALS AND METHODS: The files of 483 pediatric cases that are operated in our burn center between April 2020 and August 2022 were reviewed retrospectively.The demographic data of the patients,the anesthesia method,the number and the type of operations,the unit in which the patient was followed-up postoperatively and mortality were recorded.Diffucult airway management of neck burns were evaluated

RESULTS: 483 pediatric patients,40.99% (n=198)were female and 59.60% (n=285) were male.The mean age was 3.5 ± 3.61. Although according to the age ranges,35.40% (n=171)were 1-2 years of age constituted the highest rate.84.8% (n=410)of the patients were followed in the clinic and 15.1% (n=73) were followed in the intensive care unit. Intensive care mortality was 1.36% (Table 1).General anesthesia was the predominant choice for anesthesia,but endotracheal intubation (ETT) was significantly higher than Laryngeal mask airway (LMA).According to the surgical operation, sedoanalgesia was preferred especially in cases with short-term debridement (%37,5)(Table 2). Endotracheal intubation was preferred according to the burn percentage in head and neck burns (%60)(Table 3).Difficult airway was reported in 13 cases.

Table 1. Patients data

Gender (%,n)	
Female	40,99 / 198
Male	59,60 /285
Age (mean)	3,5 ± 3,91
Age Range (%,n)	
0-1	14,2 / 69
1 ≤ 2	35,40 / 171

2 ≤ 7	33,7 /163
7 ≤ 18	16,5 /80
Citizen (% ,n)	
Turkish citizen	80,9 /391
Other citizens	19,04 /92
Unit (%,n)	
Clinic	84,6 / 410
Intensive care (ICU)	15,1 /73
ICU mortality (%,n)	1,36 /1
Burn surgery with anesthesia (n)	920

Table 2.Anesthesia method by age range and surgery type

	ETT (%,n)	**LMA (%,n)**	**Sedoanalgesia (%,n)**
Age Range			
0-1	7,6 / 70	0,2 / 2	5,7 / 53
1 ≤ 2	14,8 / 137	1,3 / 12	13,8 / 127
2 ≤ 7	16,7 / 154	1 / 9	**17,7 / 163**
7 ≤ 18	13,2 /122	0,6 / 6	7,06 / 65
Total	**52,5 / 483**	3,1 / 29	44,3 / 408
Surgery Type			
C group	7,6 / 70	0,5 / 5	0,76 / 7
D group	12,7 / 117	0,5 / 5	6,73 / 62
E group	31,5 / 290	2 / 19	**37,5 / 345**
Total	51,8 / 477	3,1 / 29	45 / 414

ETT: Endotracheal intubation, LMA: Laryngeal mask airway ventilation, C group: Split thickness skin graft, debridement large group D: Split thickness skin graft, debridement medium, etc. Group E: Debridement small, Escarectomy,etc.

Tablo 3.Anesthesia management in patients with head and neck burns

	ETT (% , n)	**LMA (% , n)**	**Sedoanalgesia (%,n)**
>%30	14,2 / 5	0	0
%15-30	28,5 / 10	0	14,2 / 5
<%15	17,1 / 6	0	25,7 / 9
Total	60 / 21	0	40 / 14

ETT: Endotracheal intubation, LMA: Laryngeal mask airway ventilation

DISCUSSION - CONCLUSION: Pediatric burn cases are special in terms of anesthesia management. Pathophysiological changes according to the degree and percentage of burns cause an increased need for opioids. Also, burn areas on the face, head-neck and chest wall causes contractures and pathologies such as subglottic stenosis (Picture 1).Therefore, we think that the appropriate anesthetic method should be planned in advance by considering both pediatric anesthesia, diffucult airway, burn complications and pathophysiological changes and alternative management plans should be prepared considering the complications that may develop.

Figure 1. Patient with a difficult airway



Keywords: pediatric anesthesia, difficult airway, burn

Pub No: O-116

Anesthetic Management of a Patient with McCune-Albright Syndrome: A Case Report

Cenk KIRANLI[1], Tugce CETIN[1], Gaye AYDIN[1]

[1]University of Health Sciences Izmir Faculty of Medicine

INTRODUCTION - PURPOSE: McCune-Albright syndrome; It is a rare disease diagnosed with fibrous dysplasia, cafe-au lait pigmentations,endocrine hyperfunction triple finding(1,2).We aimed to present this case report, considering that there is not enough resources about anesthetic management in McCune Albright syndrome and that it would be good to discuss the expected and unexpected aspects of this syndrome.

CASE: A 16-year-old with McCune-Albright syndrome was planned for elective surgery due to a right humerus lower end fracture. ASA II anesthesia risk was given to the patient who had no endocrine pathology, and his consent was obtained.Standard ASA monitoring was performed before anesthesia.In the physical examination, preparations were made for difficult mask ventilation due to protrusions in the facial bones, prognathism, large tongue, and difficult intubation.Anesthesia was induced by intravenous midazolam, propofol and fentanyl.There was no problem in ventilation, 40 mg of rocuronium was administered and he was intubated with a 7.0 ETT without any problem.Intraoperative close monitoring and blood gas monitoring were performed.Brachial plexus block was applied for postoperative analgesia.The patient was extubated without any problem, and was hospitalized in the intensive care unit for close hemodynamic follow-up.The patient, who had no problems in the postoperative follow-up, was transferred to the service.

McCune-Albright Syndrome



cafe-au lait pigmentations in McCune-Albright Syndrome



Laboratory results of the case

	Case	Normal Range
Growth Hormone(mcg/L)	**4.42** high	0,05-3
IGF-1 (ng/ml)	237	173-414
ALP	**920** high	52-172
LH (mIU/ml)	**0,72** low	1,24-8,62
TSH (mIU/ml)	1.9	0.38-5,33
Serbest T4 (ng/dl)	1,01	0.6-1.34
Serbest T3 (ng/L)	2,82	2,73-8,62
Ca (mg/dl)	**8** low	8.8 - 10.6
P (mg/dl)	3.6	2.5 - 4.5
ACTH (ng/L)	<5.00	0-46
Kortizol (mcg/dL)	10	6,7-22,6 (Between 06.00-10:00) <10 (Between 16.00-20.00)
Prolatin (mcg/L)	21.44	3,34-26,72

DISCUSSION - CONCLUSION: In this case report, necessary preparations should be made considering that there may be additional diseases such as hyperthyroidism, cushing's disease and acromegaly in terms of airway safety in terms of anesthesia management and endocrine.Hemodynamic data should be closely monitored in both intraoperative and postoperative follow-up(3-7).Patients with McCune-Albright syndrome have two main problems: endocrine abnormalities and difficult airway management.Therefore, perioperative management of patients with McCune-Albright syndrome awaiting planned surgery by an endocrinologist is required(1,2).The anesthesiologist should choose the most appropriate anesthetic induction and tracheal intubation method, and various intubation devices such as supraglottic device, video laryngoscope, fiberoptic bronchoscopy should be available.

Keywords: McCune-Albright syndrome, General Anesthesia, Difficult Airway

Pub No: O-117

Difficult Airway And Esophageal Perforation Related To Forestier Syndrome

Mesut ASLAN(5)[1], Asu OZGULTEKIN (1)[1], Ozlem BALIK (2)[1], Esra KARATAY SOZUER(3)[1], Abdullah RAMAZAN(4)[1], Osman EKINCI(6)[1]

[1]HAYDARPASA NUMUNE RESEACH AND TRAINING HOSPITAL

INTRODUCTION - PURPOSE: Forestier Syndrome,also known as diffuse idiopathic skeletal hyperostosis (DIH),is a non-inflammatory,systemic disease characterized by ossification and calcification in ligaments,tendons and fascia,which is evaluated as a different entity from ankylosing spondylitis and osteoarthritis(1).

CASE: A68-year-old-male-patient with no additional disease other than obesity,hypertension and type2diabetesmellitus was evaluated as difficult intubation in the preoperative evaluation,laryngeal mask ventilation was tried twice and after failure,the patient was found to be Cormack-LehanegradeIV in the laryngoscopic evaluation.Tracheal intubation was achieved by videoingoscopy followed after twice esophageal intubation.Esophagus/hypolaryngeal perforation was considered for the patient who applied to the emergency department of our hospital with the complaints of swelling in the neck,increased temperature,difficulty in swallowing and shortness of breath on the second postoperative day.Osteophyte for mation and hyperosseous changes,which compress the esophagus posteriorly and cause bridging,were noted at the patient's C4-C5-C6 spine level(Picture 1).

DISCUSSION - CONCLUSION: A case of difficult intubation due to DIH has been reported in the literature,and it was reported in this report that osteophyte in the mid-cervical region made neck extension difficult and the trachea was intubated with the smallest tube(2).In another case, a case of difficult intubation associated with tracheal deviation and rotation due to ossification at the C5-C7 level was reported(3).In the laryngoscopic examination of ourcase,a mass appearance and deviation in the posterolatea lhypopharynx were observed, in which the anatomical and mucosal integrity of the larynx was impaired. We thought that the postoperative neck abscess that developed in our case may be related to the damage to the hypopharyngeal mucosa during the laryngeal mask and intubation trials.As a result,DID may present as an unexpectedly difficult airway in advanced age and cause complications.The anamnesis and examination of the patients should be deepened and preoperative neck imaging should be performed in case of suspicion.Possible complications should be considered in the air way management of patients with diagnosed DID.

Keywords: DIFFICULT, AIRWAY, Forestier

Pub No: O-118

Cerebral Fat Embolism: Case Report

Burcu ILERI FIKRI[1], Kadir BULUT[1], Guldem TURAN[1]

[1]University of Health Sciences, Basaksehir Cam and Sakura City Hospital Intensive Care Unit, Istanbul

INTRODUCTION - PURPOSE: The condition known as fat embolism syndrome(FES) typically develops following traumatic long-bone fractures. When fat particles enter the circulation, it causes cutaneous findings, neurological findings, and respiratory failure as symptoms(1). We wanted to discuss a case of a patient who experienced epileptic seizures and unconsciousness 24 hours after suffering a femoral shaft fracture.

CASE: A 19-year-old male patient presented to the emergency department with a non-vehicle traffic accident. A decrease in the GKS and seizure activity was observed 24 hours after the femoral fracture was reducted. On his arrival in intensive care; GCS: 6, pupillary isochoric, and light reflex were present bilaterally. No pathological reflex was detected. He was intubated orotracheal and connected to a mechanical ventilator. No feature was seen in the brain CT. In diffusion MRI, diffuse millimetric-sized hyperintense areas in subcortical white matter and frontoparietal cortical area were detected in T2W and FLAIR sequences, and diffusion restriction was seen in diffusion-weighted images(Figure 1). The patient's seizure activity continued, and sedation and levetiracetam 2x1 gram/day were started. A successful weaning process was completed with improvement in the neurological examination on the 7th day. Supportive treatment was continued for a while in the intensive care unit.

diffuse millimetric-sized hyperintense areas

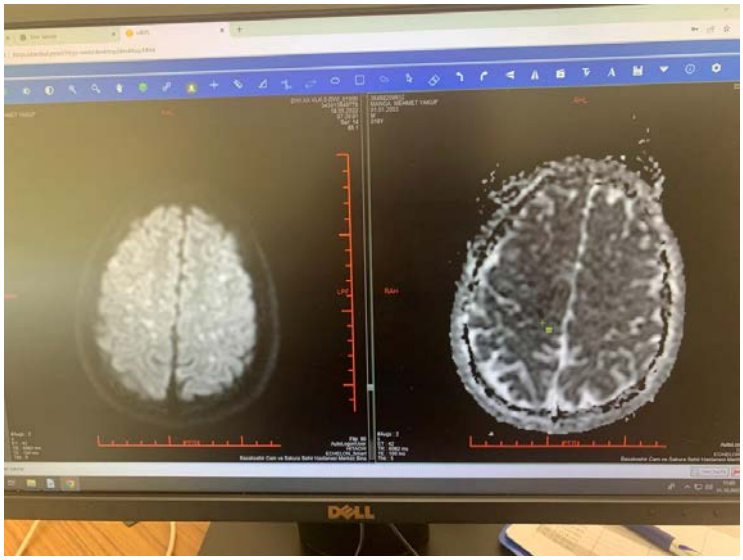

DISCUSSION - CONCLUSION: FES; Pathophysiologically, it is defined as the occlusion of the veins that rupture into the damaged area by fat particles after the damage to the adipose tissue. It has been stated that plasma mediators in the inflammatory pathway trigger the mobilization of fat particles(2,3). If blurred consciousness and respiratory distress occur after 24-48 hours after major traumas or orthopedic surgeries in the diagnosis; FES should be kept in mind(4). Brain MRI is the most sensitive imaging method. In conclusion, FES is a rare condition with neurological, hematological, and respiratory system involvement, and therefore should be considered in risky patients.

Keywords: fat embolism syndrome, intensive care, seizures, traumatic long bone fractures

Pub No: O-119

The Effects Of The Palming Maneuver On Preoperative Anxiety, Hemodynamia And Intubation Response In Patients To Receive Thyroid Surgery: A Prospective Randomized Controlled Study

Muhammet Enes TOPRAK[1], Nureddin YÜZKAT[1]

[1]VAN YYÜ DURSUN ODABAŞ TIP MERKEZİ

INTRODUCTION - PURPOSE: Our aim is to investigate the effects of palming maneuver on preoperative anxiety, hemodynamics and intubation response in patients undergoing thyroid surgery.

MATERIALS AND METHODS: A total of 80 patients, aged 18-65 years, ASA risk classification I and II, who were going to undergo thyroid surgery, were included in the study. Patients were randomized into two groups using the closed envelope method. Vital values and using the STAI scale anxiety levels of both groups were recorded upon arrival to the preoperative waiting room. The laryngoscopy response was evaluated by recording the vital values of the patients who were taken to the operating room before and after intubation.

Şekil 1. Palming manevrasının gösterimi



RESULTS: Anxiety levels, the peak of heart rate, systolic, diastolic, mean blood pressure values measured at the 15th minute (T2) in the preoperative waiting room in Group P significantly decreased compared to the 1st minute (T1) values in the preoperative waiting room. The decrease in the SPO2 value at the 15th minute (T2) in the preoperative waiting room was significantly higher in Group N than at the 1st minute (T1) in the preoperative waiting room, compared to Group P. There was no statistically significant difference in the amount of alteration in the hemodynamic data recorded in response to intubation between the groups. A significant positive correlation was observed between the change in STAI score at preop 1.min/ 15.min (T1/T2) and peak heart rate, systolic and diastolic blood pressure, mean arterial pressure alteration, and a significant negative correlation was observed between SpO2 alteration.

Grupların preop 1.ve 15.dakika STAI skorlarının gösterimi

	Grup P		Grup N		
	Ort.±ss	Medyan	Ort.±ss	Medyan	p
STAI Skoru					
T1 (Preop Bekleme Odası 1.dk)	45.2±10.3	44.0	43.5±10.4	40.0	0.300 [m]
T2 (Preop Bekleme Odası 15.dk)	37.8±7.2	36.0	43.7±9.9	42.0	***0.005*** [m]
T1/T2 Değişim	-7.4±4.7	-8.0	0.2±2.0	0.0	***0.000*** [m]
Grup İçi Değişim p	***0.000***[W]		0.647[W]		

[m] Mann-whitney u test / [w] Wilcoxon test

DISCUSSION - CONCLUSION: We realized that the palming maneuver applied in the preoperative period in patients who are going to undergo thyroid surgery effectively reduces the preoperative anxiety level, blood pressure, heart rate values, but has no effect on the intubation response.

Keywords: palming maneuver, premedication, preoperative anxiety

Pub No: O-120

Multidisciplinary Approach To The Intensive Care Unit Treatment Of Patients With Out Of Hospital Cardiac Arrest

Selma FIŞ TOPALOĞLU[1], Melek EROĞLU[1]

[1]Department Of Anesthesiology And Reanimation, , Health Sciences University Ahi Evren Thoracic And Cardiovascular Surgery Training And Research Hospital, Trabzon, Turkey

INTRODUCTION - PURPOSE: Neurological survival primarily determines mortality and morbidity in cardiac arrest cases. Targeted temperature management, which is known as Targeted Temperature Management (TTM) in the literature, is the leading neuroprotective treatment in post resuscitative care. (1,2,3,4) Amantadine is a dopaminergic agent.(5) It is used in patients with impaired consciousness with its neuroprotective properties resulting from its dopaminergic effects.(6)With this case, we aimed to share the multidisciplinary approach applied in a patient with sudden cardiac arrest.

Targeted temperature management



CASE: Twenty-eight-year-old male patient was brought to our hospital by 112 with the complaint of fainting while carrying a load in construction. The patient underwent cardiopulmonary resuscitation (CPR) for one hour. No acute pathology was detected in the brain tomography of the patient with a Glasgow coma score (GKP) of 3. Coronary angiography was normal. The patient was taken to the intensive care unit(ICU) as orotracheal intubation. TTM applied. thiopental sodium and rocuronium infusion was started. The patient's body temperature was kept at thirty-four degrees Celsius for forty-eight hours. Amantadine 200mg intravenously 2x1 was added to the treatment of the patient with GKP 6. The patient with GCP 12 on the 13th day in the ICU was extubated. ICD implanted. He was discharged on the 26th day in ICU with recommendations for a physical therapy rehabilitation program.

Arterial blood gas parameters of the patient

	ph	pCO_2 %	pO_2 %	HCO_3mmol/L	BE mmol/L	Lactate mmol/L
Arrival to the hospital	7.15	69	64	17	-4	67
1.on the hour	7.24	54	83	19	-3	54
24.on the hour	7.34	37	121	24	2	13

DISCUSSION - CONCLUSION: It is very important to support vital functions in intensive care units in post cardiac arrest syndrome. Fabio S. T. et al. stated the importance of targeted temperature after resuscitation in their study.(7)Wegrzyn et al. showed an increase in coma score using amantadine after cardiac arrest.(8) We also applied TTM to our patient, positively affecting his neurological survival. We benefited from its neuroprotective effects by using amantadine. In conclusion, we believe that the quality of life is improved with multidisciplinary treatments in post-resuscitative care after cardiac arrest.

Keywords: Targeted temperature management, Amantadine, Cardiac arrest