Hormones (2022) 21:501–506
https://doi.org/10.1007/s42000-022-00352-3

TEACHING CASE PRESENTATIONS

Atypical comorbidities in a child considered to have type 1 diabetes led to the diagnosis of *SLC29A3* spectrum disorder

Özge Besci[1] · Kashyap Amratlal Patel[2] · Gizem Yıldız[3] · Özlem Tüfekçi[4] · Kübra Yüksek Acinikli[1] · İbrahim Mert Erbaş[1] · Ayhan Abacı[1] · Ece Böber[1] · Meral Torun Bayram[3] · Şebnem Yılmaz[4] · Korcan Demir[1]

Received: 15 June 2021 / Accepted: 17 January 2022 / Published online: 14 March 2022
© Hellenic Endocrine Society 2022

Abstract

Introduction *SLC29A3* spectrum disorder is an autosomal, recessively inherited, autoinflammatory, multisystem disorder characterized by distinctive cutaneous features, including hyperpigmentation or hypertrichosis, hepatosplenomegaly, hearing loss, cardiac anomalies, hypogonadism, short stature, and insulin-dependent diabetes.

Case presentation Herein, we report a 6-year-old boy who presented with features resembling type 1 diabetes mellitus, but his clinical course was complicated by IgA nephropathy, pure red cell aplasia, and recurrent febrile episodes. The patient was tested for the presence of pathogenic variants in 53 genes related to monogenic diabetes and found to be compound heterozygous for two *SLC29A3* pathogenic variants (p. Arg386Gln and p. Leu298fs).

Conclusion This case demonstrated that *SLC29A3* spectrum disorder should be included in the differential diagnosis of diabetes with atypical comorbidities, even when the distinctive dermatological hallmarks of *SLC29A3* spectrum disorder are entirely absent.

Keywords Monogenic diabetes · Anemia · Steroid · Tocilizumab · Intravenous immunoglobulin

Introduction

The *SLC29A3* gene located on chromosome 10q22 encodes human equilibrative transporter 3 (hENT3), a nucleoside transporter that plays a critical role in salvage pathways [1]. Pathogenic variants in *SLC29A3* cause an autosomal, recessively inherited, autoinflammatory, multisystem disorder (Online Mendelian Inheritance in Man #602,782). A number of conditions, including, inter alia, H syndrome, histiocytosis-lymphadenopathy plus syndrome, and pigmented hypertrichosis with insulin-dependent diabetes mellitus, previously believed to be distinct disorders, have recently been grouped within the same disease spectrum known as *SLC29A3* spectrum disorder [1, 2].

Defects in the *SLC29A3* gene cause hyperpigmentation or hypertrichosis. These distinctive cutaneous features are commonly known to be the hallmarks of the disease. Various other systemic manifestations, including hepatosplenomegaly, hearing loss, cardiac anomalies, hypogonadism, short stature, and insulin-dependent diabetes mellitus, accompany the cutaneous findings [1–8].

In order to expand our understanding of this genodermatosis [9], we herein report a case, initially presenting with a clinical picture indicating diagnosis of type 1 diabetes, who developed IgA nephropathy, pure red cell aplasia, and recurrent fever episodes during follow-up.

Case presentation

A 6-year-old Turkish boy had presented to another clinic with a 3- to 4-week history of polyuria, polydipsia, and enuresis nocturna. He was diagnosed with type 1 diabetes

✉ Korcan Demir
korcan.demir@deu.edu.tr

1 Department of Pediatric Endocrinology, Faculty of Medicine, Dokuz Eylül University, İzmir, Turkey

2 Institute of Biomedical and Clinical Science, University of Exeter, Exeter, UK

3 Department of Pediatric Nephrology, Faculty of Medicine, Dokuz Eylül University, İzmir, Turkey

4 Department of Pediatric Hematology and Oncology, Faculty of Medicine, Dokuz Eylül University, İzmir, Turkey

mellitus (T1DM) upon detection of hyperglycemia (231 mg/dl), ketonuria (ketone + 1), elevated HbA1C (12.5%; normal, 4.5–6), positive insulin antibody (12.5%; normal, < 8.2), and negative anti-islet cell and anti-glutamic acid decarboxylase antibodies. He was born with a birth weight of 3750 g at full term to healthy non-consanguineous parents. His past medical history was unremarkable.

On admission to our clinic after 4 months, he was on basal-bolus insulin regimen (total daily dose 0.8–1 units/kg). He had a body weight of 21 kg (0.21 SDS) and a height of 124 cm (0.1 SDS). He was prepubertal and systemic physical examination showed flat foot, fifth toe clinodactyly, and a 2 × 4 cm sized café-au-lait spot on the right side of his lower back (shown in Fig. 1). Liver-kidney-thyroid function tests and complete blood count were normal, and celiac antibodies were negative. HbA1C level was 7.9%.

At 7.5 years of age, rashes resembling Henoch-Schönlein purpura appeared on both his legs. Laboratory studies showed no abnormality in his serum, urine, and stool. All complaints resolved within a month. There were no signs related to gastrointestinal, renal, or joint involvement. Four months later, he presented with macroscopic hematuria and hypertension (120/90 mmHg, 95th centile of systolic and diastolic blood pressure in his age and height: 111/72), and laboratory analysis showed nephritic range proteinuria (37 mg/m^2/day). Upon exacerbation of his symptoms, a renal biopsy was performed, and he was diagnosed with IgA nephritis. Prednisolone (2 mg/kg/day) and enalapril (0.2 mg/kg/day) were effective in normalizing blood pressure and renal function tests.

At age 8, he presented with pallor. His laboratory evaluation showed hemoglobin of 5.8 g/dL (normal, 11.5–17.5), total leukocyte count of 6.9×10^3/μL (normal, $4–10 \times 10^3$), platelet count of 379×10^3 μL (normal, $156–373 \times 10^3$), red blood cell count of 2.7×10^6/μL (normal, $4–5.7 \times 10^6$/μL) with 0.23% reticulocyte (normal, 0.5–3.5), mean corpuscular volume of 66 fL (normal, 80–95), mean cell hemoglobin concentration of 33 g/dL (normal, 32–35), red cell distribution width of 18% (normal, 12–14), and haptoglobin of 117 mg/dL (normal 32–197). Peripheral blood smear showed non-hemolytic microcytic hypochromic anemia. Serum ferritin and transferrin saturation were 100 ng/mL (normal 23–336) and 66% (normal 7–46), respectively. Toxoplasmosis, rubella, and cytomegalovirus antibodies were negative, along with parvovirus B19 DNA PCR. Pure red cell aplasia (PRCA) was diagnosed after bone marrow aspiration. Systemic corticosteroids (prednisolone 2 mg/kg/d, tapered over 6 months), intravenous immunoglobulin (1 g/kg/d, 2 doses), and cyclosporine A (6 mg/kg/d, 2 months) did not provide any clinical improvement. Regular blood transfusion requirement necessitated chelation treatment because of elevated serum ferritin levels (1789 ng/mL; normal, 23–336).



Fig. 1 Clinical image of the patient at the age of 12.5 years. **a**, **b** Frontal and dorsal view, arrowhead: café-au-lait spot. **c**, **d**, **e** Clinodactyly and flat foot deformity

At 11 years of age, he had four episodes of fever within 2 months, with findings of a noninfectious etiology. Acute-phase reactants were elevated, including an erythrocyte sedimentation rate of 120 mm/h (normal, < 20) and CRP of 370 mg/L (normal < 5). Bacterial cultures and viral serology tests were negative. Antinuclear antibody (ANA) was positive at 1:320 dilution with a speckled pattern; anti-dsDNA and extractable nuclear antigen antibody (ENA) panel were negative; genetic analysis for familial Mediterranean fever showed the E148Q variant on a single allele; adenosine deaminase-2 (ADA2) was not deficient. Abdomen ultrasonography and thoracic tomography imaging was normal. After 2 months, the fever resolved spontaneously, erythrocyte sedimentation rate returned to normal, and CRP and ANA were found to be negative.

Development of the abovementioned comorbidities that are unexpected in T1DM, weak positivity of a single diabetes autoantibody, and a low T1DM genetic risk score generated from 30 T1DM-associated common genetic variants (10.4th centile of T1D reference population) prompted an investigation into monogenic causes of diabetes [10–12]. Based on previous work [13], a custom-designed NGS panel including 53 genes and the NC_012920.1:m.3243A > G mitochondrial DNA variant revealed the presence of two heterozygous variants in the *SLC29A3* gene, namely, the novel variant c.890dupC, p.Leu298fs, and the previously reported variant c.1157G > A, p.Arg386Gln, the latter classified as pathogenic according to ACMG/AMP criteria [14]. Sanger sequencing of the SLC29A3 gene in the parents confirmed compound heterozygosity in our patient [Leu298fs] [Arg386Gln], since the father was found to be heterozygous for the p.Leu298fs variant and the mother heterozygous for p.Arg386Gln (Supplemental Fig. 1).

On clinical examination at the age of 11 years and 10 months, he was found to have hepatomegaly with elevated liver transaminases (aspartate transaminase 178 U/L; normal, 0–50, alanine transaminase 291 U/L; normal, 0–50), presumably as a consequence of his chronic transfusion-dependence (peak ferritin at 4560 ng/mL), despite good adherence to iron chelation therapy with deferasirox (30 mg/kg/d). Other laboratory investigations were normal, including albumin 3.8 g/dL (normal, 3.8–5.4), total protein 6.2 g/dL (normal, 5.7–8), INR 1.8 (normal, 0.8–1.2), total bilirubin 0.34 mg/dL (normal, 0.3–1.2), creatine kinase 55 U/L (normal, 0–171), and ceruloplasmin 0.4 g/L (normal, 0.2–0.6); viral hepatitis serology was negative, antimitochondrial, smooth muscle and liver-kidney antibodies were negative, and the ultrasound of the abdomen showed an enlarged liver with no focal lesions. Surveillance of the derangements of liver transaminases necessitated liver biopsy to rule out hepatic involvement of *SLC29A3* spectrum disorder; the biopsy showed chronic hepatitis with massive hemosiderosis.

A laboratory investigation into other *SLC29A3* spectrum features was performed. Thyroid function (TSH 2.9 IU/L; normal 0.38–5.5, freeT4 0.95; normal, 0.5–1.5) was normal, and gonadotropin levels (FSH 1.57 IU/mL; normal, 1.5–18, LH 3.01 IU/mL; normal, 0.3–6.3, total testosterone 107 ng/dL; normal, 240–827) were in accordance with his age interval. Standard screening laboratory tests of immunity, including IgA of 133 mg/dL; normal, 67–433, IgM of 50 mg/dL; normal, 47–484; IgG of 1032 mg/dL; normal, 835–2094, total IgE of 67 IU/mL; normal 0–87, total leukocyte count of 5900/μL; normal, 4 to 10×10^3, absolute lymphocyte count of 2100/μL (1300–3500), absolute neutrophil count 3100/μL (2100–6100), and relative sizes of lymphocyte subpopulations (T cells 82%; normal, 52–78, B cells 10.5%; normal, 8–24, natural killer cells 6.5%; normal, 6–27, T helper cells 34.5%; normal 25–48, T cytotoxic cells 41.5%, normal 9–35), did not reveal any deficiencies.

Based on the results of empirical treatment trials for *SLC29A3* spectrum disorders in the literature, tocilizumab (8 mg/kg/d), a human monoclonal interleukin-6 receptor antibody, was administered [6, 15, 16]. However, the anemia did not improve, and transaminase levels increased two to threefold after two doses of this hepatotoxic agent. Tocilizumab treatment was discontinued (Table 1). Liver enzymes returned to normal after cessation of therapy.

Currently, at 12.5 years of age, he is on basal-bolus insulin treatment (1.5 u/kg/day) and receives erythrocyte

Table 1 Response to tocilizumab treatment

	Pre-treatment	2 weeks after the first dose	1 week after the second dose	Normal range
Hemoglobin (g/dL)	13.3	10.2	7.9	13.5–17.5
Sedimentation (mm/h)	12	-	2	0–15
AST (U/L)	29	51	70	0–50
ALT (U/L)	65	86	104	0–50
CRP (mg/L)	17	-	1.3	0.2–5
WBC (u/L)	6300	5700	4700	4000–10,000
Urine protein/creatinine (mg/mg)	0.3	0.26	0.21	0.15

transfusions every 3–4 weeks with deferasirox chelation (shown in Fig. 2).

Discussion

Among several features defining *SLC29A3* spectrum disorder, cutaneous findings are considered to comprise the hallmark clinical presentation [1, 2]. Almost all patients reported in the literature presented with different musculoskeletal and/or dermatological phenotypical characteristics, including hyperpigmentation, hypertrichosis, facial telangiectasias, flexion contractions, or foot deformities [2, 4, 6, 9, 15, 16]. Diabetes was the first and only presenting feature in our patient. To our knowledge, there is only one other similar case without any significant dermatological or musculoskeletal involvement reported by Brostilava et al. [17], namely, the younger brother of a previously diagnosed case, a short-statured adult with telangiectasias who presented with antibody negative diabetes. In strong contrast to the previously reported cases, which were typically diagnosed after characteristic phenotypic features, including cutaneous hyperpigmentation with or without hypertrichosis and flexion contractures, our case had mild phenotypic features. He had flat feet and clinodactyly, which features were observed in 20% of all cases reported by Molho-Pessach et al. [2] and a café-au-lait spot, which was not previously reported [2, 4, 6, 9, 15, 16]. Hence, despite the aggressive clinical course, characteristic dermatological involvement never emerged, which constitutes a novel finding.

In previous studies, homozygosity or compound heterozygosity for several different variants (including Gly427Ser, Gly437Arg, Arg363Gln, Arg363Trp, Arg386Gln, Thr449Arg, and Met116Arg) in the *SLC29A3* gene have been reported [1, 8, 18–21]. With respect to genotype–phenotype correlation, one patient identified by Farooq et al. [20], who carried the same p.Arg386Gln variant as our patient, was reported to have hyperpigmentation, hypertrichosis, flexion contractures, heart defects, hearing loss, liver fibrosis, and elevated fasting blood glucose, while Campeau et al. [22] observed dysosteosclerosis and recurrent infections in another patient carrying the same variant. Our case, whom we found to be compound heterozygous for the two *SLC29A3* pathogenic variants (p. Arg386Gln and p. Leu298fs), had hyperglycemia, abnormalities in liver function tests, and fever episodes, similarly to the previously diagnosed cases; however, no other shared clinical characteristics were noted. There thus seems to be no genotype–phenotype correlation among the carriers of the same variant in the *SLC29A3* gene [20, 22].

The exact etiopathogenesis delineating the mechanism of diabetes remains an important subject area of research [18]. The weakly positive anti-insulin antibodies observed in our case may reflect the autoimmune nature of the disorder, as suggested by several other reports [4–6, 18, 21]. According to Haliloglu et al. [23], antibody positivity was 83% in T1D, but on the other side of the spectrum, McDonald et al. [24] reported detectable autoantibodies in 1–2% of all other monogenic forms of diabetes. Furthermore, Cliffe et al. [18] demonstrated that knockdowns of Drosophilia *SLC29A3* orthologs at different degrees resulted in different phenotypes with varying levels of losses, but once the insulin receptors were rescued, the intracellular signaling defect was also reversible.

Several other endocrine features were also reported in the *SLC29A3* disease spectrum. Short stature, for instance, was seen in half of the cases, and responses to treatment were best achieved after administration of supraphysiological doses of growth hormone [4, 6, 16]. Despite the chronic systemic illness and recurrent doses of steroids, our patient's height continued to be within the normal range. Another aspect, hypogonadism, observed in 16% of the cases

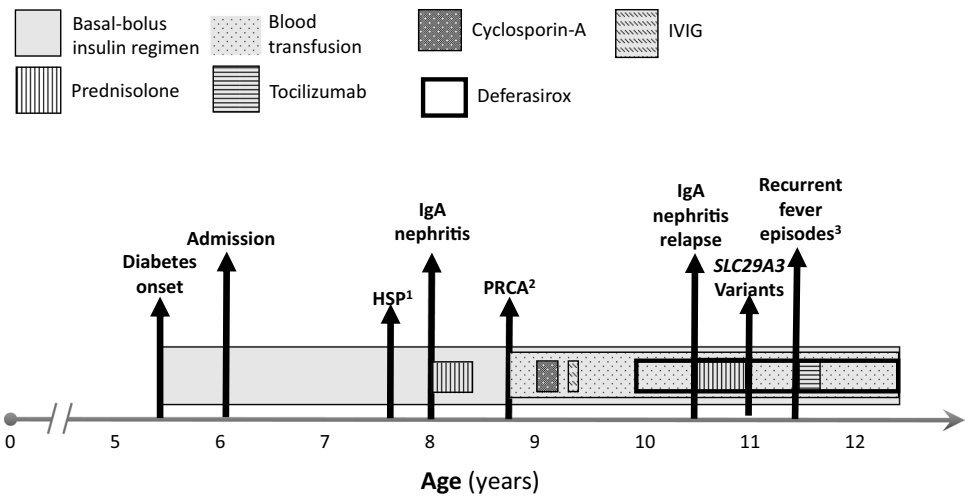

Fig. 2 Timeline of the diagnosis and treatments. [1]Henovh-Schoenlein purpura, [2]Pure red cell aplasia. [3]Within 2 months, 4 episodes of admittance

reported by Molho-Pessach et al. [2], was also not apparent in our patient, as he showed steady progression through the pubertal stages with normal gonadotropin levels.

Different forms of immune deficiencies related to *SLC29A3* disease spectrum have also been presented in the literature [6, 16, 19, 25]. Although in our case the initial immunological tests did not reveal any deficiencies and the inflammatory markers returned to normal without any need for long-term hospitalization, as was suggested by Cagdas et al. [5], further diagnostic functional analyses may be performed for cases with suspected immunodeficiencies. Congenital anomalies of the kidney and urinary tract have been reported in 6% of cases by Molho-Pessach et al. [2]. However, though glomerular involvement was observed in only two cases reported by David et al. [26], a novel finding in our case was the fact that our patient had IgA nephropathy, which has not been reported to date. Furthermore, similar to the pure red cell aplasia observed in our patient, various other bone marrow abnormalities, including pure red cell aplasia, myelofibrosis, or pancytopenia, have been reported in 10% of confirmed cases [2, 5, 27]. Although there is a lack of consensus on treatment, several different treatment approaches have been tried which are reported in the literature [5, 6, 15, 25]. In contrast to the adequate treatment responses reported by Bloom [6] and Cagdas et al. [5], as regards our patient, systemic steroids, immunoglobulins, cyclosporine A, and tocilizumab did not result in any therapeutic effect on bone marrow or pancreas, except for IgA nephritis, which partially showed remission under the systemic corticosteroids.

In conclusion, atypical comorbidities blurring the classical T1D course necessitate further investigation. While *SLC29A3* disease spectrum is presented as a form of genodermatosis in the literature, even when such classical dermatological hallmarks characterizing the spectrum are not evident, it should be included in the differential diagnosis of atypical courses of diabetes. The present study not only presented new features of this entity, but has also helped to expand our understanding of the spectrum of diabetes.

Supplementary Information The online version contains supplementary material available at https://doi.org/10.1007/s42000-022-00352-3.

Author contribution All authors contributed to the study conception and design. O.B. collected data and wrote the first draft; K.A.P. performed the genetic testing for monogenic diabetes and edited the paper; I.M.E. and K.Y.A. collected data and followed up the patient; G.Y. and M.T.B. performed renal biopsy and treated renal involvement; O.T. and S.Y. performed bone marrow biopsy and treated hematologic involvement; A.A. and E.B. edited the paper; K.D. investigated the clinical disorder, made the clinical diagnosis, followed up the patient, and critically edited the paper. All authors commented on the drafts of the manuscript. All authors read and approved the final manuscript. All authors have accepted responsibility for the entire content of this manuscript and approved its submission.

Funding Genetic testing for monogenic diabetes is funded by Wellcome Trust as part of a post-doctoral fellowship to K.A.P. (110082/Z/15/Z). For the purpose of open access, the author has applied a CC BY public copyright license to any Author Accepted Manuscript version arising from this submission.

Availability of data and material The datasets generated during and/or analyzed during the current study are available from the corresponding author on reasonable request.

Code availability Not applicable.

Declarations

Ethics approval The research was complied with all the relevant national regulations and institutional policies and in accordance with the World Medical Association Declaration of Helsinki and the appropriate guidelines for human studies.

Consent to participate Written informed consent was obtained from the parents.

Consent for publication The parents signed informed consent regarding publication of their data. All authors read and approved the final manuscript for publication.

Competing interests The authors declare no conflict of interest. The Wellcome Trust had no role in the design and conduct of the study; collection, management, analysis, and interpretation of the data; preparation, review, or approval of the manuscript; and decision to submit the manuscript for publication.

References

1. Molho-Pessach V, Lerer I, Abeliovich D et al (2008) The H syndrome is caused by mutations in the nucleoside transporter hENT3. Am J Hum Genet 83(4):529–534
2. Molho-Pessach V, Ramot Y, Camille F et al (2014) H syndrome: the first 79 patients. J Am Acad Dermatol 70(1):80–88
3. Melki I, Lambot K, Jonard L et al (2013) Mutation in the SLC29A3 gene: a new cause of a monogenic, autoinflammatory condition. Pediatrics 131(4):e1308–e1313
4. Ozlu C, Yesiltepe Mutlu G, Hatun S (2019) A Turkish girl with H syndrome: stunted growth and development of autoimmune insulin dependent diabetes mellitus in the 6th year of diagnosis. J Pediatr Endocrinol Metab 32(1):89–93
5. Çağdaş D, Sürücü N, Tan Ç et al (2020) Autoinflammation in addition to combined immunodeficiency: SLC29A3 gene defect. Mol Immunol 121:28–37
6. Bloom JL, Lin C, Imundo L et al (2017) H syndrome: 5 new cases from the United States with novel features and responses to therapy. Pediatr Rheumatol Online J 15(1):76
7. Morgan NV, Morris MR, Cangul H et al (2010) Mutations in SLC29A3, encoding an equilibrative nucleoside transporter ENT3, cause a familial histiocytosis syndrome (Faisalabad histiocytosis) and familial Rosai-Dorfman disease. PLOS Genetics. 6(2):e1000833
8. Bolze A, Abhyankar A, Grant AV et al (2012) A mild form of SLC29A3 disorder: a frameshift deletion leads to the paradoxical translation of an otherwise noncoding mRNA splice variant. PLOS ONE. 7(1):e29708

9. Tekin B, Atay Z, Ergun T et al (2015) H syndrome: a multifaceted histiocytic disorder with hyperpigmentation and hypertrichosis. Acta Derm Venereol 95(8):1021–1023
10. Patel KA, Oram RA, Flanagan SE et al (2016) Type 1 diabetes genetic risk score: a novel tool to Discriminate monogenic and type 1 diabetes. Diabetes 65(7):2094–2099
11. Marchand L, Li M, Leblicq C, et al. (2021) Monogenic causes in the type 1 diabetes genetics consortium cohort; low genetic risk for autoimmunity in case selection. J Clin Endocrinol Metab
12. Simsek DG, Aycan Z, Özen S et al (2013) Diabetes care, glycemic control, complications, and concomitant autoimmune diseases in children with type 1 diabetes in Turkey: a multicenter study. J Clin Res Pediatr Endocrinol 5(1):20–26
13. Patel KA, Ozbek MN, Yildiz M, et al. (2021) Systematic genetic testing for recessively inherited monogenic diabetes: a cross-sectional study in paediatric diabetes clinics. Diabetologia.
14. Richards S, Aziz N, Bale S, et al. (2015) Standards and guidelines for the interpretation of sequence variants: a joint consensus recommendation of the American College of Medical Genetics and Genomics and the Association for Molecular Pathology. 17(5):405-24.
15. Rafiq NK, Hussain K, Brogan PA (2017) Tocilizumab for the treatment of SLC29A3 mutation positive PHID syndrome. Pediatrics. 140(5).
16. Simsek E, Simsek T, Eren M et al (2019) Clinical, histochemical, and molecular study of three Turkish siblings diagnosed with H syndrome, and literature review. Horm Res Paediatr 91(5):346–355
17. Broshtilova V, Ramot Y, Molho-Pessach V, Zlotogorski A (2009) Diabetes mellitus may be the earliest and sole manifestation of the H syndrome. Diabet Med 26(11):1179–1180
18. Cliffe ST, Kramer JM, Hussain K et al (2009) SLC29A3 gene is mutated in pigmented hypertrichosis with insulin-dependent diabetes mellitus syndrome and interacts with the insulin signaling pathway. Hum Mol Genet 18(12):2257–2265
19. Spiegel R, Cliffe ST, Buckley MF et al (2010) Expanding the clinical spectrum of SLC29A3 gene defects. Eur J Med Genet 53(5):309–313
20. Farooq M, Moustafa RM, Fujimoto A et al (2012) Identification of two novel mutations in SLC29A3 encoding an equilibrative nucleoside transporter (hENT3) in two distinct Syrian families with H syndrome: expression studies of SLC29A3 (hENT3) in human skin. Dermatology 224(3):277–284
21. Prendiville J, Rogers M, Kan A et al (2007) Pigmented hypertrichotic dermatosis and insulin dependent diabetes: manifestations of a unique genetic disorder? Pediatr Dermatol 24(2):101–107
22. Campeau PM, Lu JT, Sule G et al (2012) Whole-exome sequencing identifies mutations in the nucleoside transporter gene SLC29A3 in dysosteosclerosis, a form of osteopetrosis. Hum Mol Genet 21(22):4904–4909
23. Haliloğlu B, Abalı S, Buğrul F et al (2018) The distribution of different types of diabetes in childhood: a single center experience. J Clin Res Pediatr Endocrinol 10(2):125–130
24. McDonald TJ, Colclough K, Brown R et al (2011) Islet autoantibodies can discriminate maturity-onset diabetes of the young (MODY) from Type 1 diabetes. Diabet Med 28(9):1028–1033
25. Mistry A, Parry D, Matthews B et al (2016) A case of SLC29A3 spectrum disorder-unresponsive to multiple immunomodulatory therapies. J Clin Immunol 36(5):429–433
26. David O, Geylis M, Kristal E, Ling G, Schreiber R (2021) Glomerular involvement in children with H syndrome. Pediatr Nephrol 36(3):721–724
27. de Jesus J, Imane Z, Senée V et al (2013) SLC29A3 mutation in a patient with syndromic diabetes with features of pigmented hypertrichotic dermatosis with insulin-dependent diabetes, H syndrome and Faisalabad histiocytosis. Diabetes Metab 39(3):281–285

Publisher's note Springer Nature remains neutral with regard to jurisdictional claims in published maps and institutional affiliations.