ACTA ORTHOPAEDICA et TRAUMATOLOGICA TURCICA
www.aott.org.tr

Case Report

Bilateral anterior cruciate ligament agenesis in a 12-year-old boy: A rare case report

Eren Akin[1], Salih Kagan Kurun[1], Lokman Kehribar[1], Ahmet Emin Okutan[2]

[1]*Department of Orthopedics and Traumatology, Dokuz Eylül University Faculty of Medicine, İzmir, Türkiye*
[2]*Department of Orthopedics and Traumatology, Samsun University Faculty of Medicine, Samsun, Türkiye*

A R T I C L E I N F O

Article history:
Submitted November 28, 2025
Received in revised form December 26, 2025
Last revision received form March 25, 2026
Accepted May 08, 2026
Publication date July 23, 2026

Keywords:
Anterior cruciate ligament agenesis
Bilateral
Congenital

ORCiD iDs of the Authors:
E.A. 0009-0002-5099-7171;
S.K.K. 0009-0006-8503-4593;
L.K. 0000-0001-9799-8839;
A.E.O. 0000-0003-1818-9422.

ABSTRACT

Bilateral anterior cruciate ligament (ACL) agenesis is an exceptionally rare condition. Only a limited number of bilateral ACL agenesis cases have been reported in the literature, and these patients typically present with additional congenital anomalies or other pathologies involving the knee joint. Here, a 12-year-old male patient was reported with bilateral absence of the ACL, who had no comorbidities other than a history of casting and Achilles tenoplasty performed for pes equinovarus. The patient presented to the clinic with bilateral knee laxity and a sense of instability during daily activities. Magnetic resonance imaging of both knees revealed bilateral ACL agenesis. Unlike most previously published cases, the patient had no associated congenital anomalies or accompanying pathologies, making this case a rare example in the existing literature.

Introduction

Anterior cruciate ligament (ACL) agenesis is a rare entity and has been reported infrequently in the literature, mostly as small case series.[1] The prevalence of ACL agenesis is 0.017 per 1000 live births.[2]Hypoplasia or aplasia of the ACL has been described in association with meniscal anomalies, lower extremity deformities, and various congenital syndromes.[3,4] Similarly, several cases have been reported in conjunction with femoral, tibial, or fibular aplasia.[1,5]

Anterior cruciate ligament absence during early childhood is often asymptomatic, and there is no consensus regarding its optimal management.[6] When these patients present with symptoms—particularly instability—they may be misdiagnosed with acute ACL rupture on magnetic resonance imaging (MRI), which can lead to challenges in the treatment pathway.[6]

Here, a patient presented to the clinic with a sense of instability in the left knee and rotational discomfort during sports activities, and bilateral ACL agenesis was identified on MRI. This case contributes to the literature because the patient had no congenital anomalies or developmental abnormalities involving the femur or knee joint.

Case Presentation

A 12-year-old male patient presented to the clinic with pain and swelling in the left knee following a non-contact rotational injury while playing football. The general condition was good, vital signs were stable, and the patient was alert and cooperative. The injury was reported to be non-contact in nature, and the patient had no complaints involving other extremities or organ systems.

Upon further questioning, the patient stated that similar symptoms—particularly episodes of giving way, rotational instability during sports, and a feeling of the knees "collapsing" when climbing stairs—had been intermittently present in both knees since the age of 9 years.

Physical examination began with inspection. The left knee exhibited swelling and effusion. Palpation revealed mild tenderness. Because of the swelling and tenderness, provocative tests on the left knee were deferred. Anterior drawer and Lachman tests on the right knee were positive. Bilateral anteroposterior and lateral knee radiographs were obtained (Figure 1), which demonstrated that no significant osseous abnormality was detected on radiographs. The patient was prescribed a nonsteroidal anti-inflammatory topical cream and an elastic bandage. Given the history of intermittent instability symptoms affecting both knees, bilateral knee MRI was planned, and the patient was asked to return for follow-up in 10 days. At the follow-up visit, the swelling had resolved and his symptoms had significantly improved. Repeat physical examination showed no effusion or tenderness. Anterior drawer and Lachman tests demonstrated high-grade laxity (grade 2-3) in both knees (Figure 2). Magnetic resonance imaging revealed bilateral agenesis of the ACL (Figure 3). To exclude potential bony deformities, an orthoroentgenogram was obtained, which showed no abnormalities.

Corresponding author:
Eren Akin,
erenakn310@gmail.com

Content of this journal is licensed under a Creative Commons Attribution-NonCommercial 4.0 International License.

Cite this article as: *Akin E, Kurun SK, Kehribar L, Okutan AE. Bilateral anterior cruciate ligament agenesis in a 12-year-old boy: A rare case report. Acta Orthop Traumatol Turc., 2026; 60(4), 0787, . doi: 10.5152/j.aott.2026.25787.*

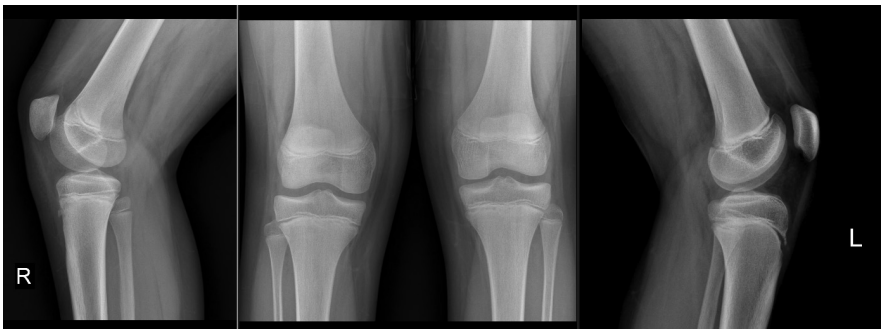

Figure 1. Bilateral anteroposterior and lateral knee radiographs demonstrating narrowing of the intercondylar notch in both knees.



Figure 2. Anterior drawer test performed on the patient, demonstrating bilateral positivity.

The patient's medical history revealed a diagnosis of congenital pes equinovarus, for which he had undergone Ponseti casting followed by Achilles tenoplasty. No other significant personal or family medical history was identified.

The patient is currently being followed in the clinic with a physical therapy and rehabilitation program. Surgical intervention will be reconsidered near skeletal maturity, and no operative treatment is planned at this stage. Informed consent for publication was obtained from the patient's legal guardians.

Discussion

Anterior cruciate ligament agenesis is an exceedingly rare condition, with most available publications consisting of small case series. The most comprehensive work to date is the systematic review by Kambhampati et al,[6] in which 8 out of 34 evaluated knees also demonstrated absence of the posterior cruciate ligament (PCL). In contrast, both PCLs were intact in the patient.

A prominent point in the literature is the frequent presence of additional deformities and congenital conditions in patients with ACL agenesis.

HIGHLIGHTS

- Bilateral anterior cruciate ligament (ACL) agenesis is an exceptionally rare condition, and cases without associated congenital anomalies are even more uncommon.
- The patient demonstrated isolated bilateral ACL agenesis with intact posterior cruciate ligaments, distinguishing this case from many previously published reports.
- Early diagnosis is essential to differentiate congenital agenesis from acute ACL rupture, especially in symptomatic pediatric patients.
- Management should focus on rehabilitation during growth, with surgical reconstruction considered near skeletal maturity.

Thomas NP et al, in a series of 12 cases, emphasized associated lower-extremity abnormalities such as congenital short femur and tibial dysplasia.[5]Hejgaard N et al reported bilateral genu valgum in a patient with ACL agenesis.[7]Tolo VT et al described a case of bilateral ACL agenesis accompanied by radial clubhand, bilateral genu varum, and congenital thrombocytopenia.[3] Apart from a history of pes equinovarus—which had been treated in infancy—the patient had no additional congenital anomalies, distinguishing this case from many reported examples.

Another noteworthy observation in previously published cases is the coexistence of PCL agenesis alongside ACL agenesis.[8] However, in this case, both PCLs were preserved, further supporting the uniqueness of this presentation.

Manner et al evaluated 28 unilateral and 3 bilateral knees with cruciate ligament aplasia and described 3 distinct patterns based on ligament morphology.[9] In their classification, type 1 represents ACL aplasia or hypoplasia with a normal PCL, type 2 is characterized by ACL aplasia accompanied by PCL hypoplasia, and type 3 involves aplasia of both the ACL and PCL. According to this classification, the patient clearly fits the Type 1 pattern, as the ACL was bilaterally absent while the PCL remained intact in both knees.

Andrew J. Degnan et al reported a case of bilateral ACL agenesis in a patient with juvenile idiopathic arthritis, noting narrowing of the femoral intercondylar notch and aplasia of the tibial eminence.[10] Although the patient also exhibited narrowing of the intercondylar notch, tibial eminence aplasia was not observed. This discrepancy may be explained by the presence of concurrent PCL agenesis in Degnan's case, whereas the patient's PCL was normal.

NieBauer J.J. et al suggested that early and effective surgical intervention may prevent intra-articular consequences of cruciate ligament

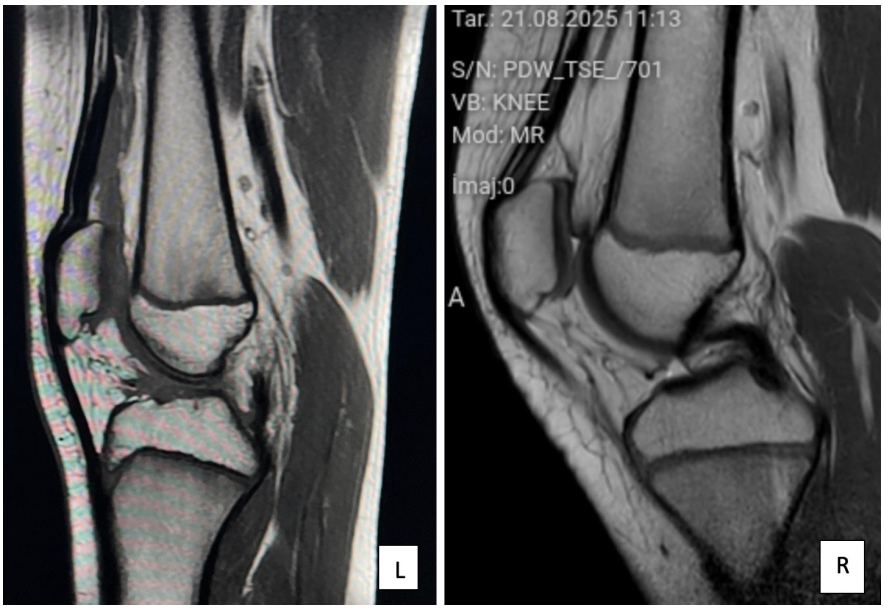

Figure 3. Bilateral T2-weighted sagittal magnetic resonance imaging images of the knees showing absence of the anterior cruciate ligament in both joints.

aplasia, whereas delayed treatment may necessitate arthrodesis in severe cases. [11] While correction of associated bony deformities is important when present, ACL reconstruction can be performed in skeletally immature patients using physeal-sparing or physeal-respecting techniques; a conservative approach was preferred in this case due to the congenital nature of the condition, relatively mild symptoms, and the patient's functional adaptation. Considering the potential risk to the growth plates and absence of disabling instability, surgical intervention was deferred, with plans for reassessment near skeletal maturity. This case adds to the limited body of literature by demonstrating that bilateral ACL agenesis may present without associated congenital abnormalities and with preserved PCL integrity, which may influence both diagnosis and management strategies.

Anterior cruciate ligament agenesis is an extremely rare condition, and isolated bilateral cases without associated congenital anomalies are exceptionally uncommon. This case highlights the importance of recognizing isolated bilateral ACL agenesis as a distinct clinical entity, even in the absence of accompanying deformities. Accurate diagnosis is essential to avoid misinterpretation as acute ligament injury, particularly in pediatric patients presenting with instability. Patients with ACL agenesis should be carefully evaluated for associated lower-extremity anomalies. Although the risk of developing osteoarthritis is increased in the absence of reconstruction, management should be individualized, and conservative treatment may be appropriate in selected patients, with surgical intervention considered near skeletal maturity or in cases of significant functional impairment.

Data Availability Statement: The data that support the findings of this study are available on request from the corresponding author.

Informed Consent: Written informed consent was obtained from the patients' legal guardians who agreed to take part in the study.

Peer-review: Externally peer-reviewed.

Acknowledgments: The authors would like to thank the Department of Orthopaedics and Traumatology at Dokuz Eylül University for their support during the evaluation and management of this case. We also acknowledge the radiology team for their assistance in obtaining and interpreting the imaging studies.

Author Contributions: Concept – E.A., L.K.; Design – E.A., L.K.; Supervision – L.K., A.E.O.; Resources – E.A., S.K.K.; Materials – E.A., S.K.K.; Data Collection and/or Processing – E.A., S.K.K.; Analysis and/or Interpretation – E.A., L.K., A.E.O.; Literature Search – E.A., S.K.K.; Writing – E.A.; Critical Review – L.K., A.E.O.

Declaration of Interests: The authors have no conflict of interest to declare.

Funding: The authors declared that this study has received no financial support.

References

1. Johansson E, Aparisi T. Congenital absence of the cruciate ligaments: a case report and review of the literature. *Clin Orthop Relat Res*. 1982;162:108-111. [CrossRef]
2. Tachdjian MO. *Pediatric Orthopedics*. 2nd ed. Philadelphia, PA: Saunders; 1990:609-618, 2277-2280.
3. Tolo VT. Congenital absence of the menisci and cruciate ligaments of the knee. A case report. *J Bone Joint Surg Am*. 1981;63(6):1022-1024. [CrossRef]
4. Mitsuoka T, Horibe S, Hamada M. Osteochondritis dissecans of the medial femoral condyle associated with congenital hypoplasia of the lateral meniscus and anterior cruciate ligament. *Arthroscopy*. 1998;14(6):630-633. [CrossRef]
5. Thomas NP, Jackson AM, Aichroth PM. Congenital absence of the anterior cruciate ligament. A common component of knee dysplasia. *J Bone Joint Surg Br*. 1985;67(4):572-575. [CrossRef]
6. Kambhampati SBS, Vishwanathan K, Vasudeva N, et al. Management of anterior cruciate ligament aplasia for the arthroscopy surgeons: a systematic review. *Indian J Orthop*. 2022;56(7):1123-1138. [CrossRef]
7. Hejgaard N, Kjaerulff H. Congenital aplasia of the anterior cruciate ligament. Report of a case in a seven-year-old girl. *Int Orthop*. 1987;11(3):223-225. [CrossRef]
8. Bedoya MA, McGraw MH, Wells L, et al. Bilateral agenesis of the anterior cruciate ligament: MRI evaluation. *Pediatr Radiol*. 2014;44(9):1179-1183. [CrossRef]
9. Manner HM, Radler C, Ganger R, et al. Dysplasia of the cruciate ligaments: radiographic assessment and classification. *J Bone Joint Surg Am*. 2006;88(1):130-137. [CrossRef]
10. Degnan AJ, Kietz DA, Grudziak JS, et al. Bilateral absence of the cruciate ligaments with meniscal dysplasia: unexpected diagnosis in a child with juvenile idiopathic arthritis. *Clin Imaging*. 2018;49:193-197. [CrossRef]
11. NieBauer JJ, King DE. Congenital dislocation of the knee. *J Bone Joint Surg Am*. 1960;42-A(2):207-225. [CrossRef]