Serum vitamin A and β-carotene concentrations and renal scarring in urinary tract infections

Salih Kavukçu, Mehmet Türkmen, Nilgün Sevinç, Alper Soylu, Erkan Derebek, Benal Büyükgebiz

Abstract

***Objective*—To evaluate the role of vitamin A on renal scarring in recurrent urinary tract infections (UTIs).**

***Design*—Twenty three children with UTIs and renal scarring (mean (SD) age 7.3 (3.9) years) and 91 children without renal scarring (6.4 (3.4) years) were studied. All the children had serum vitamin A and β-carotene measurements and nutritional evaluation. Renal scarring was assessed by technetium-99m dimercaptosuccinic acid (^{99m}Tc DMSA) scanning. Nutritional status of all the patients was within normal limits and not different between the groups.**

***Results*—Mean (SD) serum vitamin A and β-carotene concentrations were not significantly different between the patients with and without renal scarring (vitamin A 53.2 (22.6)/46.8 (17.0) μg/dl and β-carotene 232.3 (201.3)/272.4 (86.0) μg/dl respectively). However, when the patients with renal scarring and with greater than 10% difference among the DMSA uptakes of their kidneys (11 cases) were evaluated, a significant negative correlation was determined between the serum vitamin A concentrations and the magnitude of the difference in uptakes of each kidney. The same relation was not true for serum β-carotene concentrations.**

***Conclusion*—This study demonstrated a relation between serum vitamin A concentrations and magnitude of hypoactivity in ^{99m}Tc DMSA scanning in kidneys with advanced scarring.**

(*Arch Dis Child* 1998;**78**:271–272)

Keywords: vitamin A, β-carotene, renal scarring, technetium-99m DMSA

Dokuz Eylül University, Medical Faculty, İnciraltı, İzmir,Turkey: Department of Paediatrics
S Kavukçu
M Türkmen
N Sevinç
A Soylu
B Büyükgebiz

Department of Nuclear Medicine
E Derebek

Correspondence to:
Dr Salih Kavukçu, Mithatpaşa Cad No 665/4, 35280 Küçükyalı, İzmir, Turkey.

Accepted 30 September 1997

The role of vitamin A in recurrent urinary tract infections (UTIs) and urolithiasis has been assessed previously.[1] Vitamin A was proposed as effective in the regeneration of epithelial tissue in the urinary tract[2]; β-carotene has been reported to have antioxidant properties.[3] Technetium 99-m dimercaptosuccinic acid (^{99m}Tc DMSA) scintigraphy is the gold standard for demonstration of scarring in renal cortical tissue.[4]

We hypothesised that the regenerative effect of vitamin A on epithelial tissue could also be considered to play a part on renal parenchymal epithelium, as in the case of epithelium lining the lower urinary tract. The aim of this study was to evaluate the relation between vitamin A metabolism and scarred and unscarred renal parenchymal tissues and also to evaluate whether vitamin A and β-carotene had an effect on prevention of renal scarring.

Subjects and methods

Children with renal scarring due to recurrent UTIs were enrolled in this study. A control group was composed of children with recurrent UTIs but without renal scarring.

Each patient was evaluated twice by ^{99m}Tc DMSA scans performed at least six months apart. Persisting hypodense areas on two consecutive DMSA scans were considered as renal scarring.[4] Patients with normal or non-persisting DMSA findings were considered as free of scarring. Uptake of each kidney was determined as per cent of total uptake of both kidneys which was considered to be 100%. When the difference between uptakes of kidneys exceeds 10% on scanning, renal function was considered to be diminished on the lower uptake side.[4] All the scans were read blindly by two specialists.

Nutritional status of patients was evaluated by body mass index and the results were compared with published standards.

Vitamin A and β-carotene concentrations were measured by the Neeld and Pearson method in venous blood samples obtained during acute UTI episodes.[5] The intrabatch coefficients of variation for vitamin A and β-carotene were 6.5% and 7.8 % respectively in preliminary standardisation.

Patients were grouped according to whether they had renal scarring (study group) or not (control group). The groups were compared for serum vitamin A and serum β-carotene concentrations and nutritional status. In addition, the extent of kidney scarring was compared with serum concentrations of vitamin A and β-carotene, when the difference between ^{99m}Tc DMSA uptakes of kidneys was greater than 10%.

Results were analysed by unpaired *t* test and correlation analysis.

Results

There were 23 children with renal scars (mean (SD) age 7.3 (3.9) years and 91 unscarred children (mean age 6.4 (4.4) years). The mean age difference between the groups was statistically insignificant. All the patients were well nourished and there was no difference in nutritional status of the two groups. Weight and height of the subjects were between 25th and 75th centile and their weight for height indices were higher than 90%. The mean (SD, range) serum vitamin A and β-carotene concentrations in patients with renal scars were 53.2

Arch Dis Child: first published as 10.1136/adc.78.3.271 on 1 March 1998. Downloaded from http://adc.bmj.com/ on September 2, 2021 by 193.140.151.30. Protected by copyright.

Table 1 Mean (SD) serum vitamin A and β-carotene concentrations in patients with and without renal scarring

	Renal scarring		
	With (n=23)	*Without (n=91)*	*Advanced (n=11)*
Vitamin A (μg/dl)‡	53.2 (22.6)*	46.8 (17.0)	56.3 (23.6)†
Range	19.5–102.4	14.4–104.0	25.0–105.0
β-Carotene (μg/dl)§	232.3 (201.3)*	272.4 (86.0)	269.7 (94.0)†
Range	130.0–1154.0	103.0–496.0	102.0–486.0

*The difference between the patients with *v* without renal scarring is non-significant.
†The difference between patients with advanced renal scarring *v* without scarring is non-significant.
‡Normal values: 30–80 μg/dl in infants and 30–60 μg/dl in older children.[6] (To convert vitamin A to μmol/l multiply by 0.03491.)
§Normal values: 20–79 μg/dl in infants and 40–130 μg/dl in older children.[6] (To convert β-carotene to μmol/l multiply by 0.01863.)

(22.6, 13.5–102.4) μg/dl and 232.3 (201.3, 130.0–1154.0) μg/dl respectively. These values were 46.8 (17.0, 14.4–104.0) μg/dl and 272.4 (86.0, 103.0–496.0) μg/dl in the group without renal scarring. No significant difference was present between the groups ($p>0.05$) (table 1).

Patients with renal scarring and with greater than 10% difference between negative uptakes of kidneys (11/23) had a mean (SD, range) serum vitamin A concentration of 56.27 (23.63, 25.0–105.0) μg/dl and β-carotene concentration of 269.72 (94.0 (102.0–486.0) μg/dl. These values did not differ from those of the patients without renal scarring ($p>0.05$) (table 1). However, there was a significant negative correlation between serum vitamin A and magnitude of the difference in uptakes of each kidney in patients with renal scarring and greater than 10% difference between negative uptakes of kidneys ($r = -0.607$, $p<0.05$) (fig 1). The serum β-carotene concentrations were not related to the per cent of negative uptakes ($r = 0.384$, $p>0.05$). Isolated hypovitaminosis A was 8.6% (2/23) and 8.7% (8/91) in patients with or without renal scarring respectively. The difference was insignificant ($p>0.05$). β-carotene deficiency was not present in any of the subjects.

Discussion

The relation between vitamin A metabolism and respiratory, gastrointestinal, and urinary infections has been recognised previously.[1 2] Deficiency of vitamin A is responsible for epithelial changes in the body. Hyperkeratosis and squamous metaplasia have been stated to predispose to infections.[6] In addition, vitamin A and its metabolites have been reported to be necessary for T and B cell functions and its deficiency could lead to alterations in immune status.[3]

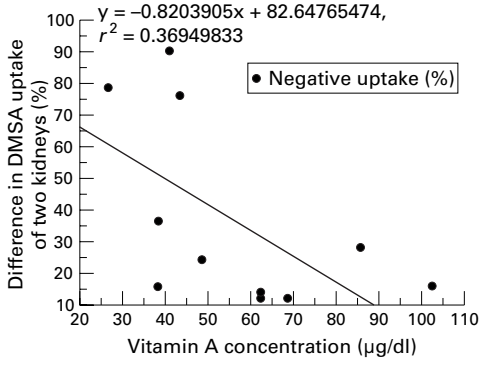

Figure 1 Relation between serum vitamin A and DMSA uptake in patients whose kidney uptake differences are >10% in renal ^{99m}Tc DMSA scintigraphy ($r = -0.607$, $p<0.05$). (To convert vitamin A to μmol/l multiply by 0.03491.)

In this study, evaluation of the proximal tubular epithelial changes determined by ^{99m}Tc DMSA scintigraphy did not demonstrate any difference in patients with or without renal scarring with respect to their serum vitamin A and β-carotene concentrations. Carotenoids have been proposed to have antioxidant activities.[3] However, since none of our cases was deficient in β-carotene, it could be hypothesised that β-carotene was not sufficient by itself to prevent renal scarring in UTIs. On the other hand, patients with renal scarring were also shown to have serum vitamin A concentrations which were no lower than those of the patients without scarring. However, the degree of hypoactivity in scarred kidneys of patients with greater than 10% difference between negative uptakes of their kidneys was significantly inversely related to serum vitamin A concentrations. This finding emphasises the importance of the serum vitamin A concentration in advanced renal scarring due to recurrent UTIs. In this study, serum vitamin A and β-carotene were measured by the time irreversible renal injury (scarring) had occurred. Since renal scarring is defined as the persistence of hypoactivity in DMSA scintigraphy for 4–6 months, prospective studies could not be performed within a short time by this method.[4] If serum vitamin A is determined at the time of the initial DMSA scan, nutritional factors and other intervening infections could alter its level during the next 4–6 months.

In this study, serum vitamin A was found to be related to the level of hypoactivity in patients with advanced renal scarring. This relation could result from the interaction between vitamin A and systemic immune response or epithelial tissue lining renal parenchyma and/or urinary tract.[3 6]

Isolated hypovitaminosis A ratio was not different among the patients with or without renal scarring. Isolated β-carotene deficiency was not present in any of the patients. Since β-carotene deficiency was not present, low vitamin A concentrations could be explained as secondary to infections.[6] Furthermore, besides the effect of vitamin A deficiency on UTIs and renal scarring, recurrent UTIs could be the cause of low vitamin A.[7]

We conclude that our study demonstrated a relation between serum vitamin A concentrations and magnitude of hypoactivity in ^{99m}Tc DMSA scan in patients with advanced renal scarring. However, no relation was determined between β-carotene and renal scarring.

1 Stansfield SK, Pierre-Louis M, Lerebours G, *et al.* Vitamin A supplementation and increased prevalance of childhood diarrhoea and acute respiratory infections. *Lancet* 1993;**342**:578–82.
2 Brown KH, Gaffar A, Alamgir SM. Xerophthalmia, protein-calorie malnutrition, and infections in children. *J Pediatr* 1979;**95**:651–6.
3 Bates CJ. Vitamin A. *Lancet* 1995;**345**:31–5.
4 Hellerstein S. Urinary tract infections. Old and new concepts. *Pediatr Clin North Am* 1995;**42**:1433–57.
5 Neeld JB, Pearson WN. Macro and micro methods for determination of serum vitamin A using trifluoroacetic acid. *J Nutr* 1962;**79**:454–62.
6 Report of a joint WHO/Unicef/USIAD/HKI/IVACG meeting. *Control of vitamin A deficiency.* (Tech Rep Ser No 672.) Geneva: World Health Organisation, 1982.
7 Herrera MG, Nestel P, El Amin A, *et al.* Vitamin A supplementation on child survival. *Lancet* 1992;**340**:267–71.

Arch Dis Child: first published as 10.1136/adc.78.3.271 on 1 March 1998. Downloaded from http://adc.bmj.com/ on September 2, 2021 by 193.140.151.30. Protected by copyright.