Hepatitis-Associated Aplastic Anemia: Etiology, Clinical Characteristics and Outcome

Özlem Tüfekçi, MD, Hamiyet H. Özdemir, MD,† Barış Malbora, MD,‡ Namık Y. Özbek, MD,§ Neşe Yaralı, MD,§ Arzu Erdem, MD,§ Melike Evim, MD,‖ Birol Baytan, MD,‖ Adalet M. Güneş, MD,‖ Tuba Karapınar, MD,¶ Yeşim Oymak, MD,¶ Ersin Töret, MD,# Özcan Bör, MD,# Şebnem Yılmaz, MD,* Hale Ören, MD,* Gül N. Özdemir, MD,** and Deniz Y. Karapınar, MD†*

Summary: Hepatitis-associated aplastic anemia (HAA) is a form of acquired aplastic anemia (AA) in which bone marrow failure develops after an acute attack of hepatitis. Bone marrow failure leading to AA is generally severe in cases of HAA and fatal if left untreated. This retrospective multicenter study investigated clinical and laboratory characteristics, possible causes, treatment, and outcome of HAA in children. Twenty patients from 8 centers were included in the study. Aspartate aminotransferase and alanine aminotransferase were < 3 to 5×upper limit of normal (ULN) in 2 patients, < 5 to 10×ULN in 2 patients, and > 10×ULN in 16 patients. Acute liver failure developed in 5 (29%) patients. Pancytopenia was simultaneously present in 6 of 20 (30%) patients. Eleven of the 20 patients (55%) were alive, in remission and transfusion free. Those who were alive either had undergone hematopoietic stem cell transplantation and/or immunosuppressive treatment, except 1 patient who had received no treatment. Patients with the diagnosis of acute hepatitis should be evaluated and followed up carefully for presence of cytopenia, so that definitive treatment of AA can be initiated in a timely and appropriate manner when needed.

Key Words: hepatitis-associated aplastic anemia, aplastic anemia, hepatitis

(*J Pediatr Hematol Oncol* 2022;44:e223–e226)

Hepatitis-associated aplastic anemia (HAA) is a form of acquired aplastic anemia (AA) in which bone marrow failure develops after an acute attack of hepatitis. Hepatitis develops within 6 months before the diagnosis of AA but it can also occur concurrently.[1–3] The severity of hepatitis ranges from mild to acute liver failure.[4–6] Indeed, AA has also been reported after orthotopic liver transplantation undertaken for acute fulminant non-A, non-B, and non-C hepatitis.[6–8] Although some viral hepatitis agents have been identified in the etiology, the cause is unknown in most cases.[4,6,9–11]

Bone marrow failure leading to AA is generally severe in cases of HAA and fatal if left untreated. Immunosuppressive treatment (IST) with cyclosporine and antithymocyte globulin (ATG) and hematopoietic stem cell transplantation (HSCT) have been successfully used for treating AA.[3,6,8,11–13]

In this study, we investigated the clinical and laboratory characteristics, possible causes, treatment and outcome of HAA in children.

PATIENTS AND METHODS

All the pediatric hematology centers in Turkey were invited to join this retrospective study by on-line announcement of the Turkish Society of Pediatric Hematology. Children from 1 month to 18 years old diagnosed with HAA were eligible for the study. Patients who developed AA after liver transplantation for acute fulminant liver failure were also included. Clinical and laboratory data including peripheral blood count, bone marrow features, liver function test results, cause of hepatitis, treatment modalities (IST, HSCT), response to treatment, status at the latest follow-up, and causes of death were retrieved from medical records.

Hepatitis was considered when serum aminotransferase levels were higher twice or more than upper limit of normal (ULN) range. Acute liver failure was diagnosed when patients met all of the following criteria: 1. Hepatic failure within 8 weeks in a patient with no previous evidence of chronic liver disease. 2. Biochemical evidence of acute liver injury: elevated transaminases (aspartate aminotransferase, alanine transaminase), and total and conjugated bilirubin. 3. Coagulopathy not corrected by vitamin K; international normalized ratio > 1.5. 4. Encephalopathy (encephalopathy is not required when international normalized ratio > 2).[14] Severe AA was confirmed by bone marrow biopsy and defined as bone marrow cellularity of < 25% and at least 2 of the following: neutrophil count $< 500\times10^6$/L, platelet count $< 20{,}000\times10^6$/L, reticulocyte count $< 20{,}000\times10^6$/L. Those not fulfilling criteria for SAA but have decreased bone marrow cellularity and peripheral blood cytopenia were classified as moderate or nonsevere HAA. A complete response is defined as a normalization of peripheral blood

Received for publication February 2, 2021; accepted May 27, 2021.
From the *Department of Pediatric Hematology, Dokuz Eylül University Faculty of Medicine; †Department of Pediatric Hematology, Ege University Faculty of Medicine; ¶Department of Pediatric Hematology/Oncology, Dr Behçet Uz Training and Research Hospital, The University of Health Sciences, İzmir; ‡Department of Pediatric Pematology/Oncology, Tepecik Training and Research Hospital; §Department of Pediatric Hematology/Oncology, Ankara City Hospital, The University of Health Sciences, Ankara; ‖Department of Pediatric Hematology, Uludağ University Faculty of Medicine, Bursa; #Department of Pediatric Hematology, Osmangazi University Faculty of Medicine, Eskişehir; and **Department of Pediatric Hematology/Oncology, İstinye University Faculty of Medicine, İstanbul, Turkey.
The authors declare no conflict of interest.
Reprints: Özlem Tüfekçi, MD, Department of Pediatric Hematology, Pediatric Hematology Dokuz Eylul University Faculty of Medicine, İzmir 35340, Turkey (e-mail: ozlemtufekci@hotmail.com).
Copyright © 2021 Wolters Kluwer Health, Inc. All rights reserved.

Copyright © 2021 Wolters Kluwer Health, Inc. All rights reserved.

values in at least 2 separate blood cell counts at least 4 weeks apart.[15]

All patients were screened for hepatitis A, B, C and E, Epstein-Barr virus, cytomegalovirus (CMV), parvovirus B19, human immunodeficiency virus serology, serum liver autoantibodies, and Wilson's disease. Exposure to drug and other toxic agents was also questioned.

RESULTS

Twenty patients from 8 centers were included in the study (Table 1). The median age at the time of diagnosis of acute hepatitis was 10.8 years (range: 5 to 17). Eleven of 20 patients were males. Aspartate aminotransferase and aminotransferase were 3 to 5×ULN in 2 patients, 5 to 10×ULNin 2 patients and > 10×ULN in 16 patients. Acute liver failure developed in 5 (29%) patients. Liver transplantation because of acute liver failure was performed in all 5 patients. Severe AA developed before liver transplantation in 2 patients and after liver transplantation in 3 patients. The search for etiology revealed highly positive CMV-DNA in 1 patient and HCV-RNA in 1 patient. Besides, 1 patient had the diagnosis of autoimmune hepatitis based on immunologic and histopathologic features.[16] The median time from diagnosis of hepatitis to diagnosis of AA was 30 days (range: 0 to 322).

Table 2 gives the results of liver function tests and complete blood counts at the time of diagnosis of hepatitis and severe AA. The median values of blood count parameters revealed mild cytopenia at the time of diagnosis of hepatitis. Pancytopenia was simultaneously present in 6 of 20 (30%) patients. Of those 6 patients, 3 had severe AA at diagnosis. In terms of treatment for severe AA; 10 patients (45%) received IST with ATG and cyclosporine (Table 1). The source of ATG in patients who received IST was horse in 4 (40%) patients and rabbit in 6 (60%) patients. HLA identical HSCT was performed in 7 patients (35%). Of the 7 patients; 3 had received IST before HSCT but had to undergo HSCT because of failure of IST. The median time from diagnosis of AA to HSCT was 115 days (range: 86 to 1282). HSCT was performed from matched sibling donors in all 7 patients. The source of stem cell was bone marrow in 6 patients and peripheral blood in 1 patient. The conditioning regimen consisted of high-dose cyclophosphamide and rabbit ATG in all patients. Figure 1 shows the treatment and clinical outcome of the 20 patients. Finally, 11 of 20 patients (55%) were alive, in remission for AA and transfusion free. Those who were alive either had received HSCT and IST, except 1 patient who had received no treatment. Nine of 20 patients (45%) died mainly because of infectious causes including septicemia and invasive fungal infections.

DISCUSSION

HAA is a well-recognized clinical entity, but there are limited numbers of published reports on it in the literature. With this retrospective study, we improved our knowledge and reveal the clinical outcome of patients with HAA.

HAA has been reported to develop more frequently in children and young adolescents with a slight male predominance in most of the studies.[3–5,7,17] A recent study, however, reported an equal sex distribution among 18 patients with HAA.[6] Most studies, although with limited numbers of patients, show that older children are more affected.[4–6] Our findings were consistent with the literature with a median age of 10.8 years and more males were affected in our study. The epidemiologic characteristics may vary depending upon the geographical area and socioeconomic status.[11] Further studies with a larger number of patients are needed for better definition of the epidemiologic characteristics of this rare disease.

The median interval between HAA and AA has been reported as 1 to 3 months ranging from 0 to 18 months.[1,4–7,13,17] In our study, the median time between hepatitis and AA was

TABLE 1. Clinical Characteristics, Treatment Modalities and Last Status of the Patients

Patient Number	Sex	Age (y)	Time from Hepatitis to Aplastic Anemia (d)	Etiology	Liver Transplantation	Treatment of Aplastic Anemia	Source of ATG Used in IST	Last Status
1	Female	7.9	27	Not identified	No	HSCT		Alive
2	Female	8.9	67	Not identified	No	IST	Horse	Alive
3	Male	12	62	Not identified	No	IST+HSCT	Rabbit	Alive
4	Female	16	22	Cytomegalovirus	No	Supportive		Dead
5	Male	17.1	0	Hepatitis C	No	Supportive		Dead
6	Male	11.8	159	Autoimmune hepatitis	No	IST	Rabbit	Dead
7	Male	8	0	Not identified	No	IST	Rabbit	Alive
8	Female	6	40	Not identified	No	IST	Rabbit	Dead
9	Female	7.9	19	Not identified	Yes	IST+HSCT	Rabbit	Alive
10	Female	5	2	Not identified	No	Supportive		Dead
11	Female	11.6	52	Not identified	No	Supportive		Dead
12	Female	7.9	322	Not identified	Yes	IST	Rabbit	Alive
13	Male	5.9	30	Not identified	Yes	HSCT		Alive
14	Male	5.2	24	Not identified	Yes	IST	Horse	Alive
15	Male	10	13	Not identified	Yes	Supportive		Dead
16	Male	12.3	71	Not identified	No	HSCT		Dead
17	Male	12	84	Not identified	No	Supportive		Alive*
18	Female	12.7	14	Not identified	No	IST	Horse	Alive
19	Male	12.2	0	Not identified	No	IST+HSCT	Horse	Alive
20	Male	16.5	30	Not identified	No	HSCT		Dead

Supportive treatment includes blood component transfusion and use of granulocyte-colony stimulating factor.
*Spontaneous remission.
HSCT indicates hematopoietic stem cell transplantation; IST, immunosuppressive therapy.

Copyright © 2021 Wolters Kluwer Health, Inc. All rights reserved.
Copyright © 2021 Wolters Kluwer Health, Inc. All rights reserved.

TABLE 2. The Results of Complete Blood Counts and Liver Function Tests at the Time of Diagnosis of Hepatitis and Aplastic Anemia

Laboratory Parameter	At the Time of Diagnosis of Hepatitis	At the Time of Diagnosis of Aplastic Anemia
Median hemoglobin (range); $\times 10^9$/L	11 (6.7-13.9)	7.9 (5-11.4)
Median neutrophil count (range); $\times 10^9$/L	1.35 (0.1-9.5)	0.1 (0-0.9)
Median platelet count (range); $\times 10^9$/L	118 (3.5-42)	17 (1-70)
Median ALT (range); IU/L	895 (86-2193)	87 (9-2695)
Median AST (range); IU/L	966 (81-2007)	134 (14-2229)
Median total bilirubin (range); mg/dL	8 (0.2-36)	3.3 (0.3-26)
Median conjugated bilirubin (range); mg/dL	6 (0.08-22)	2.4 (0.1-16)

ALT indicates alanine aminotransferase; AST, aspartate aminotransferase.

30 days with a range of 0 to 322 days. The patient with 322 days interval was 1 of 5 patients who underwent orthotopic liver transplantation. It was also interesting to determine that approximately one-third of our patients had pancytopenia at the time of the diagnosis of acute hepatitis. Mild cytopenia concurrently with the diagnosis of acute hepatitis has also been reported in some studies.[4,6] These results show that patients with a diagnosis of acute hepatitis should be evaluated and followed up carefully for the presence of cytopenia, so that definitive treatment of AA can be initiated in a timely and appropriate manner when needed.

The pathogenesis of HAA has not yet been identified but an immune-mediated mechanism that targets similar antigens in the liver and bone marrow cells, is thought to be responsible. In addition to hepatitis viruses, viruses such as parvovirus B19, human immunodeficiency virus, CMV, Epstein-Barr virus, and transfusion-transmitted virus have been reported to cause AA, but the etiology is unknown in most HAA cases.[1–6,9–11] In our study, etiologic search revealed viral etiology in 2 patients and autoimmune hepatitis in 1 patient.

The course of hepatitis is unpredictable but AA is lethal if left untreated.[1,2,11,13] The definitive treatment options for HAA are IST and HSCT, as in the case of acquired AA.[3–6,8,10,13] In children with acquired AA, HSCT has been recommended as the first-line therapy when HLA-matched related donor is available.[15,18] Multiple studies have reported 5-year survival rates of 90% or more in children who underwent HSCT with a matched related donor.[3,15,18–20] In our study 7 patients had undergone HSCT, all with matched sibling donors, 6 of them were still alive and in complete remission. For children who have not a matched related donor, IST consisting of ATG and cyclosporine is the first-line treatment option. The response rate to IST in children has been reported as 60-77% with an overall 10-year survival of 80% to 90%.[15,18] A recent multicenter study in 361 patients with severe AA has reported an objective response of 71.2% and 5-year overall survival of 93% to IST with horse ATG and cyclosporine.[21] In terms of the source of ATG, horse ATG has been reported to be superior to rabbit ATG, but it has not been easily available in all countries and difficulties in obtaining the drug can affect the success of treatment.[15,20,22] IST as a monotherapy was successful in 5 of 10 patients in our study. Of note, more than half of our patients were given rabbit ATG instead of horse ATG. Horse ATG was not available in our country until 2 years ago, it had to be brought from abroad, which took a long time. Therefore, some centers had to use rabbit ATG in the first place. Most of our patients had markedly elevated liver enzymes but 5 of them developed acute liver failure and underwent orthotopic liver transplantation. Of note, 5 of 6 patients who had not undergone IST and/or HSCT died. This unfortunate result justifies the vital urgency of definitive treatment in patients with AA. Spontaneous remission occurred in 1 of those 6 untreated patients. Although rare, some cases of spontaneous remission have also been reported in the literature.[4,12]

In conclusion, although there has been a limited number of patients in this study, it was noteworthy that approximately one-third of patients presented with pancytopenia at the time of diagnosis of hepatitis. The loss of patients who did not undergo IST and HSCT revealed once again the importance of initiating IST at the appropriate time together with donor search for HSCT in this group of patients.

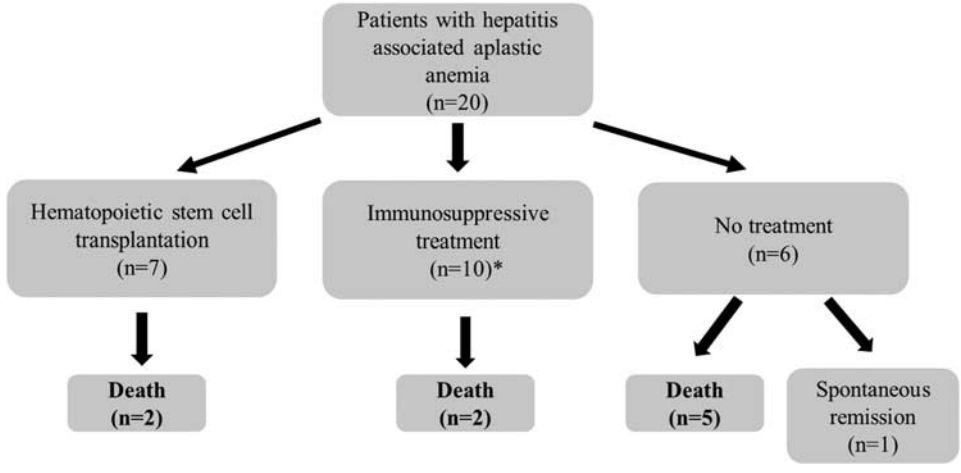

FIGURE 1. Treatment and clinical outcome of 20 patients. *3 of 10 patients had to undergo hematopoietic stem cell transplantation.

Copyright © 2021 Wolters Kluwer Health, Inc. All rights reserved.

Copyright © 2021 Wolters Kluwer Health, Inc. All rights reserved.

REFERENCES

1. Rauff B, Idrees M, Shah SA, et al. Hepatitis associated aplastic anemia: a review. *Virol J*. 2011;8:87.
2. Gonzalez-Casas R, Garcia-Buey L, Jones EA, et al. Systematic review: hepatitis-associated aplastic anaemia—a syndrome associated with abnormal immunological function. *Aliment Pharmacol Ther*. 2009;30:436–443.
3. Locasciulli A, Bacigalupo A, Bruno B, et al. Severe Aplastic Anemia Working Party of the European Blood and Marrow Transplant Group (SAA-WP, EBMT). Hepatitis-associated aplastic anaemia: epidemiology and treatment results obtained in Europe. A report of The EBMT aplastic anaemia working party. *Br J Haematol*. 2010;149:890–895.
4. Honkaniemi E, Gustafsson B, Fischler B, et al. Acquired aplastic anaemia in seven children with severe hepatitis with or without liver failure. *Acta Paediatr*. 2007;96:1660–1664.
5. Altay D, Yılmaz E, Özcan A, et al. Hepatitis-associated aplastic anemia in pediatric patients: single center experience. *Transfus Apher Sci*. 2020;59:102900.
6. Böske AK, Sander A, Sykora KW, et al. Hepatitis-associated aplastic anaemia in children. *Klin Padiatr*. 2020;232:151–158.
7. Molina RA, Katzir L, Rhee C, et al. Early evidence of bone marrow dysfunction in children with indeterminate fulminant hepatic failure who ultimately develop aplastic anemia. *Am J Transplant*. 2004;4:1656–1661.
8. Mohseny AB, Eikema DA, Neven B, et al. Hematopoietic stem cell transplantation for hepatitis-associated aplastic anemia following liver transplantation for nonviral hepatitis: a retrospective analysis and a review of the literature by the Severe Aplastic Anemia Working Party of the European Society for Blood and Marrow Transplantation (SAAWP-EBMT). *J Pediatr Hematol Oncol*. 2020. doi:10.1097/MPH.0000000000001991.
9. Alsakkal M, Al-Khateeb M, Alhalaby M, et al. Hepatitis-associated aplastic anemia: a report of 3 cases associated with HAV. *J Pediatr Hematol Oncol*. 2019;41:e164–e166.
10. Wang WH, Wu JF, Chang HH, et al. The impact of hepatitis on clinical outcomes for pediatric patients with aplastic anemia. *J Pediatr*. 2020;227:87–93.
11. Alshaibani A, Dufour C, Risitano A, et al. Hepatitis-associated aplastic anemia. *Hematol Oncol Stem Cell Ther*. 2020. S1658-3876(20)30168-0.
12. Lapinski J, Nolfi-Donegan D, Cooper JD, et al. Atypical outcomes for hepatitis-associated acquired aplastic anemia: 2 case studies and review of the literature. *J Pediatr Hematol Oncol*. 2021;43:195–199.
13. Wang H, Tu M, Fu R, et al. The clinical and immune characteristics of patients with hepatitis-associated aplastic anemia in China. *PLoS One*. 2014;9:e98142.
14. Newland CD. Acute liver failure. *Pediatr Ann*. 2016;45:e433–e438.
15. Hartung HD, Olson TS, Bessler M. Acquired aplastic anemia in children. *Pediatr Clin North Am*. 2013;60:1311–1336.
16. Hennes EM, Zeniya M, Czaja AJ, et al. Simplified criteria for the diagnosis of autoimmune hepatitis. *Hepatology*. 2008;48:169–176.
17. Hadzić N, Height S, Ball S, et al. Evolution in the management of acute liver failure-associated aplastic anaemia in children: a single centre experience. *J Hepatol*. 2008;48:68–73.
18. Samarasinghe S, Webb DK. How I manage aplastic anaemia in children. *Br J Haematol*. 2012;157:26–40.
19. Locasciulli A, Oneto R, Bacigalupo A, et al. Severe Aplastic Anemia Working Party of the European Blood and Marrow Transplant Group. Outcome of patients with acquired aplastic anemia given first line bone marrow transplantation or immunosuppressive treatment in the last decade: a report from the European Group for Blood and Marrow Transplantation (EBMT). *Haematologica*. 2007;92:11–18.
20. Marsh JC, Bacigalupo A, Schrezenmeier H, et al. European Blood and Marrow Transplant Group Severe Aplastic Anaemia Working Party. Prospective study of rabbit antithymocyte globulin and cyclosporine for aplastic anemia from the EBMT Severe Aplastic Anaemia Working Party. *Blood*. 2012;119:5391–5396.
21. Rogers ZR, Nakano TA, Olson TS, et al. Immunosuppressive therapy for pediatric aplastic anemia: a North American Pediatric Aplastic Anemia Consortium study. *Haematologica*. 2019;104:1974–1983.
22. Scheinberg P, Nunez O, Weinstein B, et al. Horse versus rabbit antithymocyte globulin in acquired aplastic anemia. *N Engl J Med*. 2011;365:430–438.

Copyright © 2021 Wolters Kluwer Health, Inc. All rights reserved.

Copyright © 2021 Wolters Kluwer Health, Inc. All rights reserved.